

DIAGNOSING MEDICAL PARASITES:

A Public Health Officers Guide to Assisting Laboratory and Medical Officers



Compiled and edited by:
Michael J. Cuomo, Maj, USAF, BSC (PH)
Lawrence B. Noel, Maj, USAF, BSC (PH)
Daryl B. White, Capt., USAF, BSC (Lab)

Contents:

Chapter 01. The Ameba

Chapter 02. The Ciliates, Coccidia, and Microsporidia

Chapter 03. The Flagellates

Chapter 04. The Cestodes (Tapeworms)

Chapter 05. The Nematodes (Roundworms)

Chapter 06. The Trematodes (Flukes)

Chapter 07. Unusual Tissue Dwelling Nematodes

Chapter 08. Larval Cestodes and Nematodes which Infect Man

Chapter 09. Malaria

Chapter 10. The Blood Nematodes

Chapter 11. Babesia, Trypanosomes, and Leishmania

Chapter 12. Arthropod Vectors

Chapter 13. Artifacts and Confounders

Chapter 1.

The Ameba

1.1 An Introduction to Parasitology

Parasitology is the study of parasites and as such does not include bacterial, fungal or viral parasites. Human parasites are separated into intestinal and blood-borne parasites. For a parasite to be defined as intestinal it must have an intestinal life-cycle stage, though it may have life-cycle stages in the heart, circulation, lung, tissue, other animals or the environment.

Parasites found in the intestines can be categorized into two groups: Protozoa and Helminths.

Protozoa are single celled organisms. There are four classes of Protozoa commonly found in concentrated fecal samples. These are differentiated by the method of motility. Protozoa include *Entamoeba*, *Giardia*, *Trichomonas*, *Cryptosporidium*, *Isospora*, *Pneumocystis* and *Balantidium*. There are two diagnostic life-cycle stages commonly seen in parasites - the cyst and the adult trophozoite stage. The trophozoite stage is analyzed directly on a slide without concentration. Cysts require concentration. The key diagnostic factor is that Protozoan cysts are typically 5-30 μm (μm = microns or micrometers) in diameter, and as such are smaller than most Helminth eggs. Due to the size they are particularly difficult to see under the microscope if the sample clarity is bad.

The medically important Helminths are nematodes (roundworms), cestodes (tapeworms) and trematodes (flukes). Genera include: *Fasciola*, *Schistosoma*, *Ascaris*, Hookworm, *Trichuris*, *Taenia* and *Enterobius*. The normal stage for examination is the egg stage, although larvae may develop in some organisms (Strongyloides); the diameter of the eggs range from 30 μm - 150 μm .

The other major grouping of parasites is known as blood-borne parasites which are transmitted through an arthropod vector. By far the most important arthropod for transmitting parasitic infections is the mosquito. Mosquitoes are known to carry malaria and filarial nematodes. Different types of biting flies transmit African trypanosomiasis, leishmaniasis and several kinds of filariasis.

Most protozoan and helminthic infections that are transmitted by arthropods can readily be diagnosed, on clinical grounds alone, but are usually identified by fairly simple techniques designed to present the presence of the causative parasite by microscopy. Sophisticated techniques are also being employed including highly sensitive and specific simple monoclonal antibody tests, DNA probes, and PCR primers.

1.2 Infections Acquired Through the Gastrointestinal Tract

Many of the infections of the gastrointestinal tract (GI) are caused by parasites that are cosmopolitan in distribution. Protozoa can be directly infectious for man when they are passed in the feces into the environment, but helminths require a period of maturation while in the soil, where they become infectious. Others such as *Taenia saginata* require the involvement of an intermediate host during their life cycle.

Infections of the GI tract account for a high proportion of deaths in infants where the standards of hygiene and nutrition are low.

Fecal-oral transmission of the pathogens is the most common mode of GI infections, whereby water, food and hands become contaminated with fecal material which then come in contact with the mouth.

A number of GI infections can reach epidemic proportion, protozoal pathogen *Cryptosporidium parvum*, has been known to cause the severe water-borne epidemics, even in first-world countries such as the United States and the UK. Other infections such as amebiasis or enterobiasis can be more localized, infecting households or institutions.

Some of the rarer, protozoal infections such as the microsporidia are only now being understood as they are appearing as concomitant infections in people with depressed immune responsiveness, e.g. AIDS.

The Ameba

Ameba (or Amoeba) are characterized by possessing clear protoplasm which form pseudopodia. These pseudopodia are the means by which these organisms move and engulf bacteria and red blood cells for feeding purposes. The most common amebas seen in the intestinal tract are *Entamoeba histolytica/dispar*, *Entamoeba coli*, *Entamoeba hartmanni*, *Endolimax nana* and *Iodamoeba bütschlii*. All but *Entamoeba histolytica* are thought to be non-pathogenic. The cysts can be identified in an ethyl acetate concentrate by the addition of iodine to reveal the characteristic inclusions and also by measuring the cyst using an eyepiece graticule. The trophozoites can be seen in a fresh saline preparation of the stool although accurate identification is on a permanently stained fecal smear.

Entamoeba histolytica

Introduction

There are a large number of species of ameba which parasitize the human intestinal tract. Of these, *Entamoeba histolytica* / *dispar* is the only species found to be associated with intestinal disease. Although many people harbor this organism world wide, only about 10% develop clinically invasive disease, thus the parasite has been shown to present as two very differing clinical presentations.

1. The commensal or non-invasive luminal form where the parasite causes no signs or symptoms of disease.
2. The pathogenic or invasive form where the parasite invades the intestinal mucosa and produces dysentery or amebiasis and may give rise to extra-intestinal lesions via the blood, mainly to the liver.

Sargeaunt and Williams (1978) conclusively proved that invasive and non-invasive strains of *E. histolytica* could be differentiated by isoenzyme electrophoresis and the application of molecular biology has confirmed the presence of two distinct species with the same morphological features. The pathogenic or invasive species has retained the name *E. histolytica* and the non-pathogenic, non-invasive species has been named *E. dispar*.

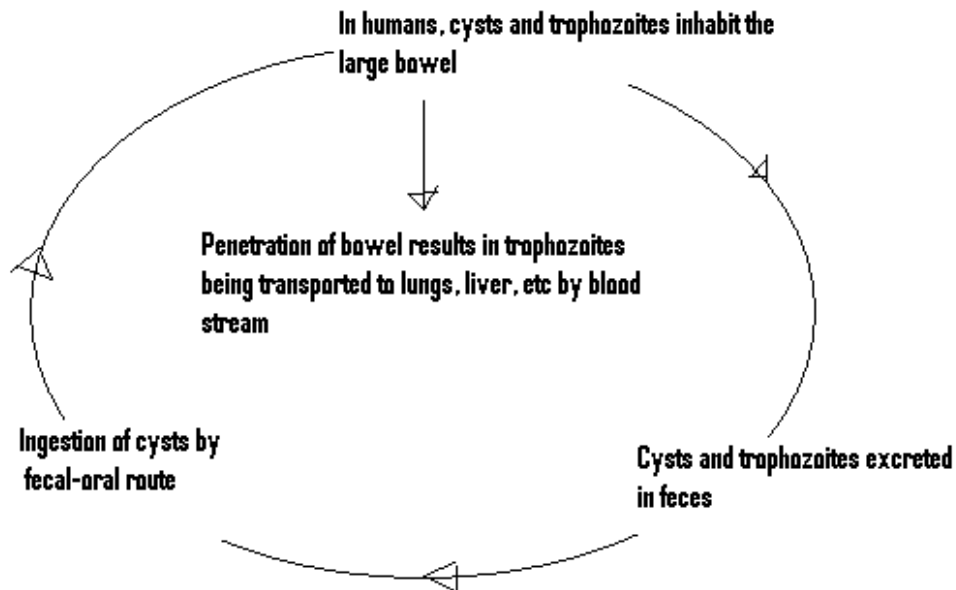


Illustration 1-1. Life Cycle of *Entamoeba histolytica*: A protozoan in which its life cycle consists of two stages; cysts and trophozoites (Cuomo)

Morphology of Trophozoites

The trophozoites of *E. histolytica* / *dispar* recovered from dysenteric stools exhibit ingested red blood cells and clear pseudopodia. Those of *E. dispar* will have no ingested red blood cells. They can be up to 60 μ m in diameter and motility is rapid and unidirectional. On a permanently stained fecal smear e.g. Trichrome or Iron hematoxylin, the morphological features are more visible. When using Trichrome stain nuclei, chromidial bars, chromatin, red cells and bacteria stain red cytoplasm stains blue-green and background and yeasts stain green. The presence of a small centrally placed karyosome is clearly visible. With Iron hematoxylin, nuclear chromatin and the karyosome will be stained immensely black. The remainder will be varying shades of grey/black.

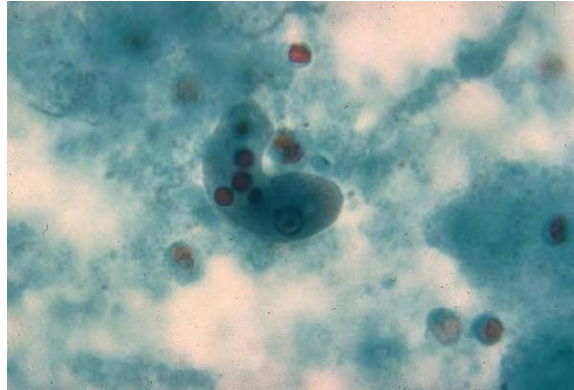


Image 1-1. *Entamoeba histolytica* trophozoites (SOURCE: PHIL 336 -CDC / Dr. N.J. Wheeler, Jr.)

Morphology of Cysts

Cysts of *E. histolytica* / *dispar* are 10-15 μ m in diameter and contain one to four nuclei. Chromatoid bodies are usually present in young cysts as elongated bars with bluntly rounded ends. Glycogen is usually diffuse, but in young cysts it is often present as a concentrated mass, staining reddish brown with iodine.

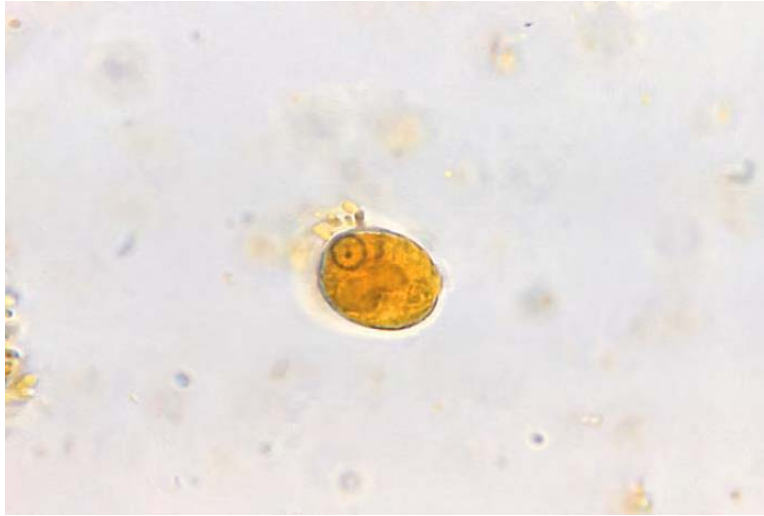

Image 1-2. *Entamoeba histolytica* cyst. (SOURCE: PHIL 531 - CDC/ Dr. L.L.A. Moore, Jr.)

Clinical Disease

Amebiasis is an infection usually caused by the pathogenic *Entamoeba histolytica* / *dispar*, and is commonly an infection of the colon. It has a world wide distribution where environmental sanitation is poor. The parasite may behave as a commensal (causing no harm to the host) or it may act as a parasite (harming the host). It is a disease of human beings, although some monkeys can become infected and the infection is then transmissible to humans.

Intestinal Disease

Patients with intestinal disease may exhibit a number of symptoms including profuse diarrhea with blood and mucus, fever and dehydration. Amebic ulcers may develop in the large colon and can also be found in the rectal area. The ulcers are usually "flask shaped" with a small opening on the mucosal surface and a larger area below the surface. **Image 1-3.** illustrates *E. histolytica* trophozoites in the intestine, resulting in amebiasis.

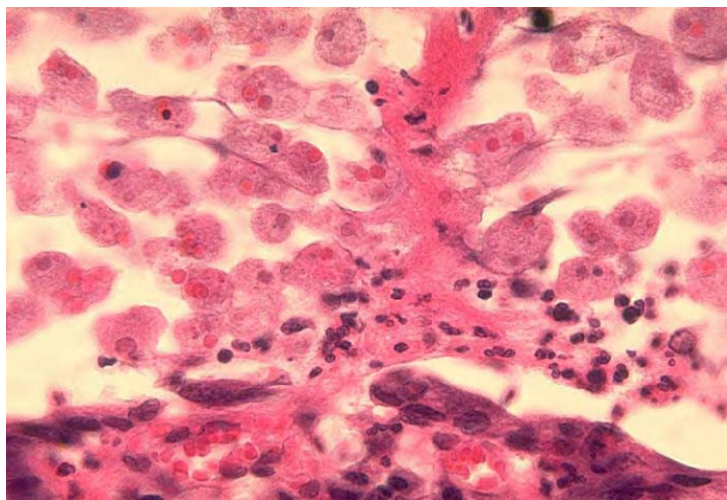


Image 1-3. *Entamoeba histolytica*, intestine. (SOURCE: PHIL 623 - CDC)

Hepatic Disease

Trophozoites are transported from the intestine to the liver and liver disease is characterized with abdominal pain, fever, hepatomegaly and tenderness. If the abscess ruptures, there is spreading to the brain, pericardium and other sites. If left untouched the abscess will grow normally until it reaches a surface where it can discharge, e.g. the skin, the peritoneum, the pleural cavity or the pericardium. The stretching of the liver is presumably the main source of the pain.

Laboratory Diagnosis

Laboratory diagnosis is made by finding the characteristic cysts in an iodine stained, formol-ether concentration method or by detecting the characteristic trophozoites in a wet preparation or a permanent stained preparation.

Microscopy

Where amebic dysentery is suspected, the laboratory should be informed that a "hot stool" is being supplied so that it can be examined within twenty minutes of being passed. On cooling the ameba stop moving which then become very difficult to identify. Direct microscopy should be done by mixing a small amount of the specimen in 0.9% sodium chloride solution. This permits detection of motile trophozoites of *Entamoeba histolytica / dispar* and can also provide information on the content of the stool (i.e., the presence of leucocytes and red blood cells). On search e.g. primarily for cysts, not for ameba, several stool samples are required to be examined, by direct microscopy and a sensitive concentration technique. Three negative stool samples are required before it can be accepted that there is no amebic infection. Microscopic examination of an amebic abscess aspirate e.g. in the liver or lungs, may reveal hematophagous trophozoites. It must be examined immediately by mixing a drop of warm saline with some aspirated pus on a microscope slide.

Serology

If visceral or hepatic amebiasis is suspected, serological tests should be done as microscopic methods do not always reveal the characteristic trophozoites. The tests of choice are indirect fluorescent antibody test (IFAT), counter immunoelectrophoresis (CIEP) enzyme linked immunosorbent assay (ELISA), and Rapid Antigen testing by enzyme immunoassay.

The search for *E. histolytica / dispar* is mainly carried out because there is a natural concern to ensure that patients, even in the absence of symptoms, are not harboring parasites that may lead to serious complications later on.

Entamoeba coli

Introduction

Entamoeba coli are a non-pathogenic amoeba with world wide distribution. Its life cycle is similar to that of *E. histolytica* but it does not have an invasive stage and does not ingest red blood cells.

Morphology of Trophozoite

The trophozoite is larger than that of *E. histolytica* ranging from 15-50 μ m in diameter. It exhibits blunt pseudopodia with sluggish movement. A permanently stained preparation shows a nucleus with a moderately large eccentric karyosome with the chromatin clumped on the nuclear membrane. The cytoplasm appears granular containing vacuoles with ingested bacteria and other food particles.

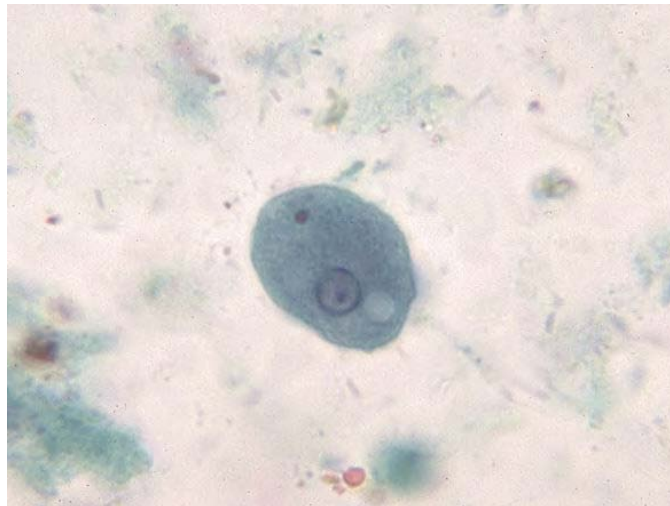


Image 1-4. *Entamoeba coli* trophozoite with ingested bacteria. (SOURCE: PHIL 605 - CDC)

Morphology of Cysts

Cysts of *E. coli* are 15-30 μ m in diameter and contain one to eight nuclei with irregular peripheral chromatin: karyosomes not central. Chromatoid bodies are not frequently seen but when present they are usually splinter-like with pointed ends. Glycogen is usually diffuse but in young cysts is occasionally found as a well-defined mass, which stains reddish brown with iodine.

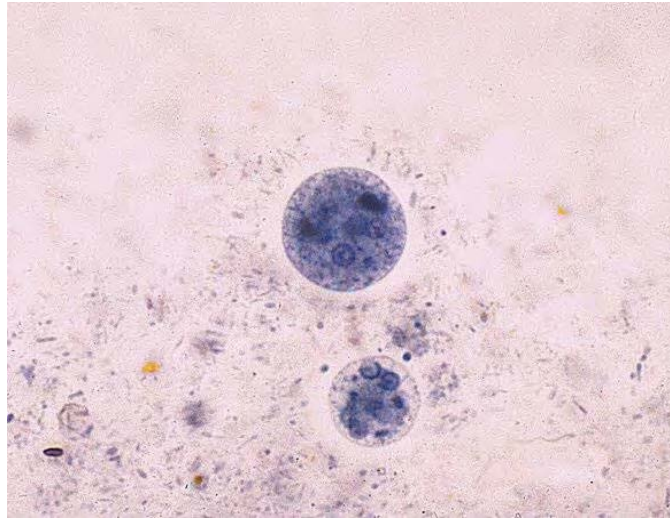


Image 1-5. *Entamoeba coli* (larger) and *Entamoeba histolytica* (smaller) cysts. (SOURCE: PHIL 442 - CDC/Dr. Mae Melvin)

Laboratory Diagnosis

Laboratory diagnosis is made by finding the characteristic cysts in an iodine stained, formol-ether concentration method or by detecting the characteristic trophozoites in a wet preparation or a permanent stained preparation.

Microscopy

Where amebic dysentery is suspected, the laboratory should be informed that a "hot stool" is being supplied so that it can be examined within twenty minutes of being passed. On cooling the ameba stop moving which then become very difficult to identify. Direct microscopy should be done by mixing a small amount of the specimen in 0.9% sodium chloride solution. This permits detection of motile trophozoites of *Entamoeba coli* and can also provide information on the content of the stool (i.e., the presence of leucocytes and red blood cells). On search e.g. primarily for cysts, not for ameba, several stool samples are required to be examined, by direct microscopy and a sensitive concentration technique. Three negative stool samples are required before it can be accepted that there is no amebic infection. Microscopic examination of an amebic abscess aspirate (e.g. in the liver or lungs), may reveal hematophagous trophozoites. It must be examined immediately by mixing a drop of warm saline with some aspirated pus on a microscope slide.

Entamoeba hartmanni

Introduction

Entamoeba hartmanni is a non-pathogenic amoeba with world wide distribution. Its life cycle is similar to that of *E. histolytica* but it does not have an invasive stage and does not ingest red blood cells.

Morphology of Trophozoites

Morphology of the trophozoites is similar to those of *E. histolytica* / *dispar* but they do not contain ingested red blood cells and the motility is less rapid.

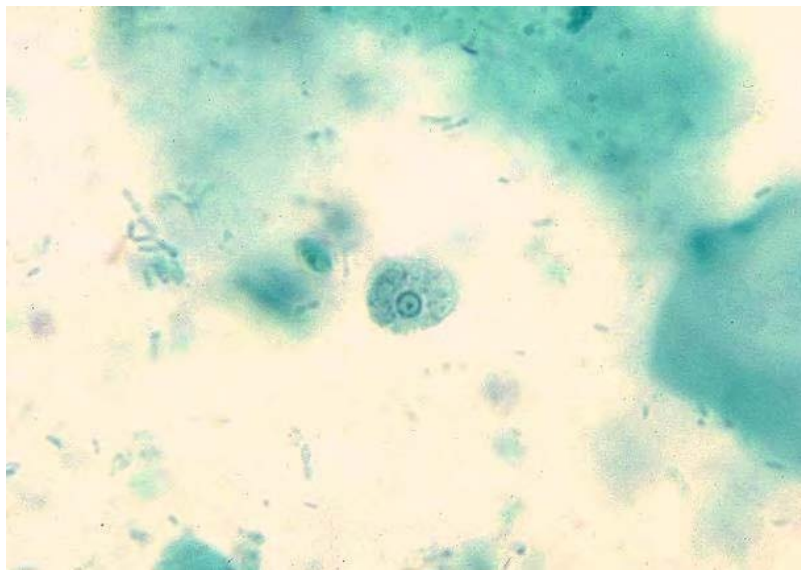


Image 1-6. *Entamoeba hartmanni* trophozoite (SOURCE: PHIL 528 - CDC/Dr. L.L.A. Moore, Jr.)

Morphology of Cysts

Cysts of *E. hartmanni* 7-9 μ m in diameter and contain one to four nuclei. Chromatoid bodies are usually present in young cysts as elongated bars with bluntly rounded ends. Glycogen is usually diffuse, but in young cysts it is often present as a concentrated mass, staining reddish brown with iodine.

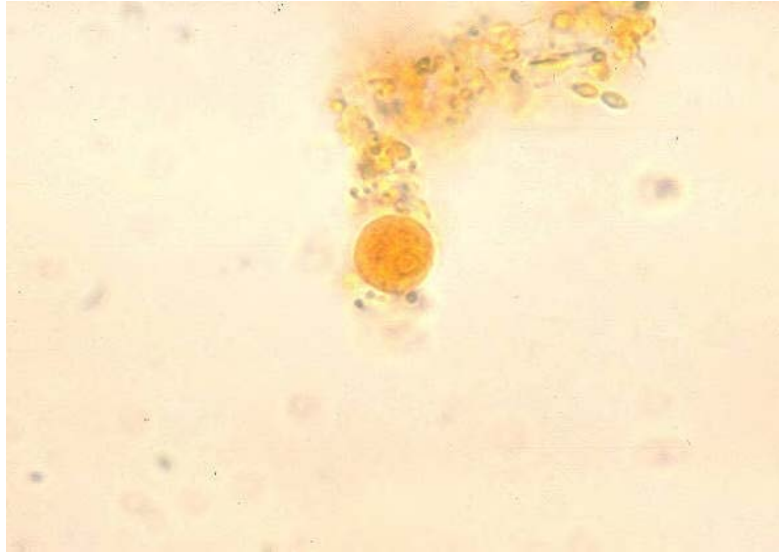


Image 1-7. *Entamoeba hartmanni* cyst (SOURCE: PHIL 533 - CDC/Dr. L.L.A. Moore, Jr.)

Laboratory Diagnosis

Laboratory diagnosis is made by finding the characteristic cysts in an iodine stained, formol-ether concentration method or by detecting the characteristic trophozoites in a wet preparation or a permanent stained preparation.

Microscopy

Where amebic dysentery is suspected, the laboratory should be informed that a "hot stool" is being supplied so that it can be examined within twenty minutes of being passed. On cooling the ameba stop moving which then become very difficult to identify. Direct microscopy should be done by mixing a small amount of the specimen in 0.9% sodium chloride solution. This permits detection of motile trophozoites of *Entamoeba hartmanni* and can also provide information on the content of the stool (i.e., the presence of leucocytes and red blood cells). On search e.g. primarily for cysts, not for ameba, several stool samples are required to be examined, by direct microscopy and a sensitive concentration technique. Three negative stool samples are required before it can be accepted that there is no amebic infection. Microscopic examination of an amebic abscess aspirate (e.g. in the liver or lungs), may reveal hematophagous trophozoites. It must be examined immediately by mixing a drop of warm saline with some aspirated pus on a microscope slide.

Endolimax nana

Introduction

Endolimax nana is a small non-pathogenic amoeba with world wide distribution. Its life cycle is similar to that of *E. histolytica* but is non-invasive.

Morphology of Trophozoite

Trophozoites of *E. nana* measures from 6-12 μ m. Motility is sluggish with blunt hyalin pseudopodia. In a permanently stained preparation, the nucleus exhibits a large karyosome with no peripheral chromatin on the nuclear membrane.

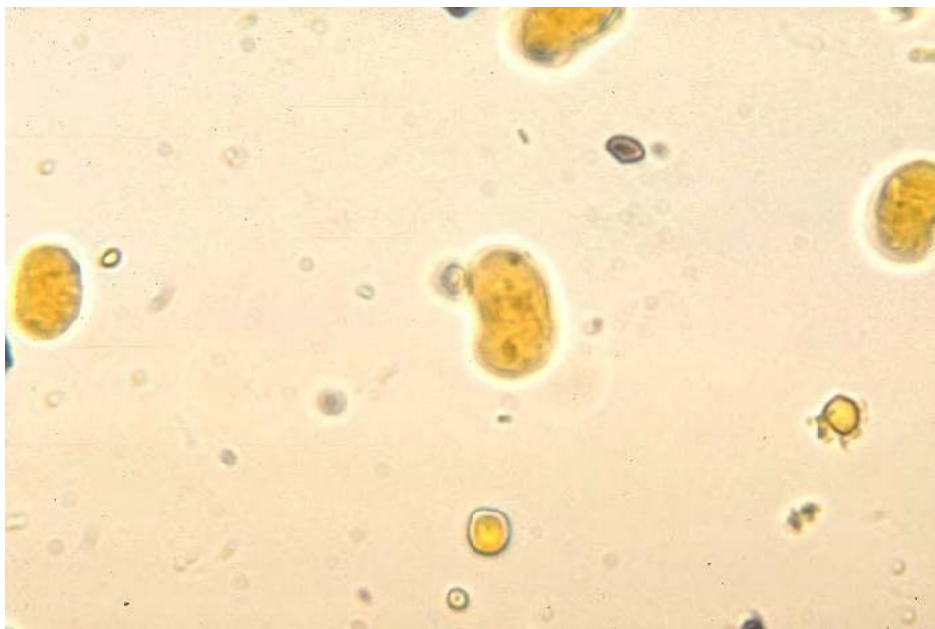

Figure 1-8. *Endolimax nana* cyst. Iodine stain. (SOURCE: PHIL 530 - CDC/Dr. L.L.A. Moore, Jr.)

Morphology of Cysts

Cysts of *E. nana* are 6-9 μ m in diameter. They can be spherical or ovoid in shape and contain four pinpoint nuclei, which are highlighted by the addition of iodine. Chromatoid bodies are not found and glycogen is diffuse.

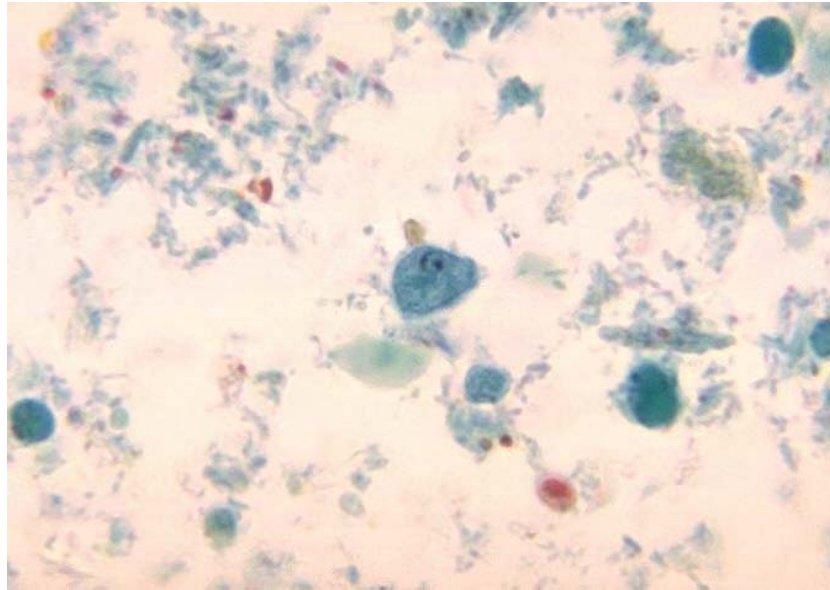


Image 1-9. *Endolimax nana* trophozoite (SOURCE: PHIL 1463 - CDC/Dr. Mae Melvin)

Laboratory Diagnosis

Laboratory diagnosis is made by finding the characteristic cysts in an iodine stained, formol-ether concentration method or by detecting the characteristic trophozoites in a wet preparation or a permanent stained preparation.

Microscopy

Where amebic dysentery is suspected, the laboratory should be informed that a "hot stool" is being supplied so that it can be examined within twenty minutes of being passed. On cooling the ameba stop moving which then become very difficult to identify. Direct microscopy should be done by mixing a small amount of the specimen in 0.9% sodium chloride solution. This permits detection of motile trophozoites of *Endolimax nana* and can also provide information on the content of the stool (i.e., the presence of leucocytes and red blood cells). On search e.g. primarily for cysts, not for ameba, several stool samples are required to be examined, by direct microscopy and a sensitive concentration technique. Three negative stool samples are required before it can be accepted that there is no amebic infection. Microscopic examination of an amebic abscess aspirate (e.g. in the liver or lungs), may reveal hematophagous trophozoites. It must be examined immediately by mixing a drop of warm saline with some aspirated pus on a microscope slide.

Iodamoeba bütschlii

Introduction

Iodamoeba bütschlii is a non-pathogenic amoeba with world wide distribution although not as common as *E. coli* or *E. nana*. Its life cycle is similar to that of *E. histolytica* but is non-invasive.

Morphology of Trophozoites

Trophozoites of *I. bütschlii* are 8-20µm and are actively motile. On a permanently stained fecal smear, a nucleus with a large karyosome is evident. Chromatin bodies form striations around the karyosome. The cytoplasm appears granular containing vacuoles with ingested bacteria and debris.

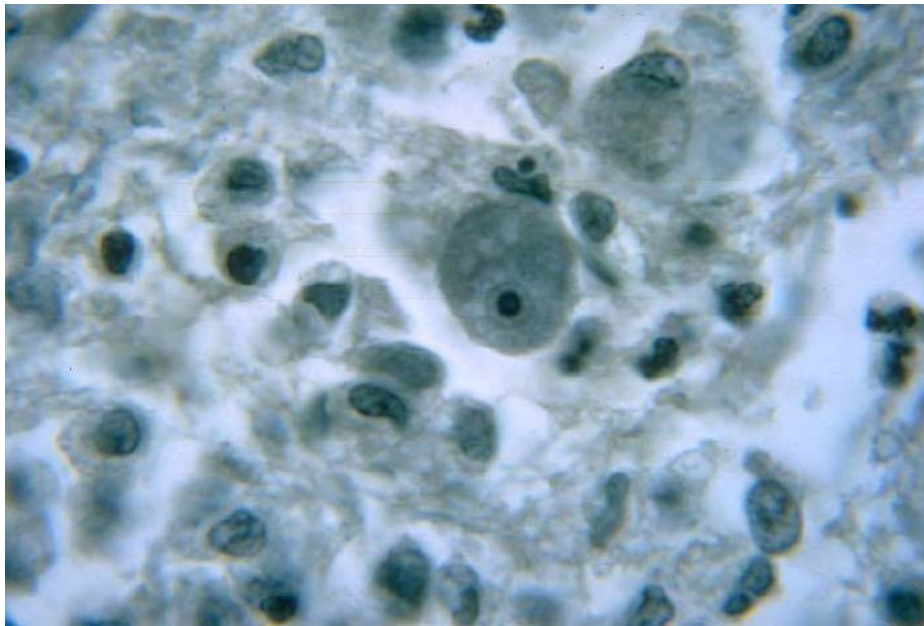


Image 1-10. Histopathology of amebiasis of brain due to *Iodamoeba bütschlii*. (SOURCE: PHIL 323 - CDC/Dr. Martin D. Hicklin)

Morphology of cysts

Cysts of *I. bütschlii* are 9-15µm in diameter and have one nucleus in mature cysts usually eccentrically placed. Chromatoid bodies are not present. Glycogen is present as a compact well defined mass staining dark brown with iodine.

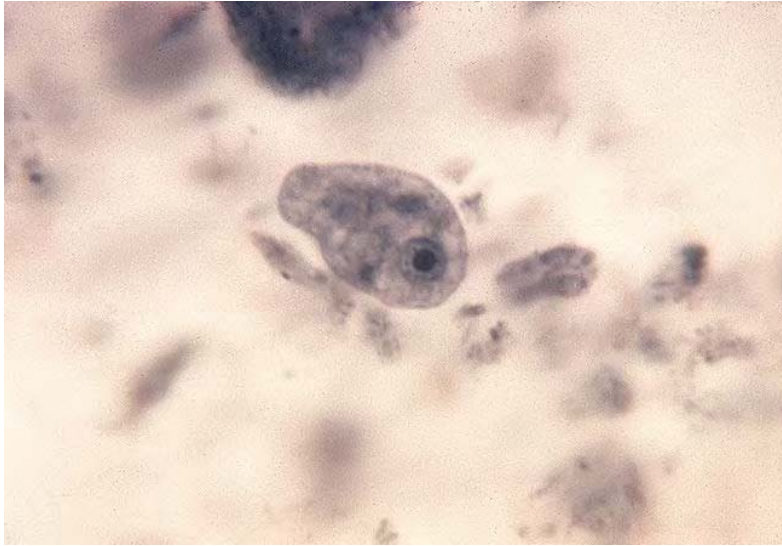

Image 1-11. *Iodamoeba bütschlii* cyst. (SOURCE: PHIL 587 - CDC/Dr. L.L.A. Moore, Jr.)

Laboratory Diagnosis

Laboratory diagnosis is made by finding the characteristic cysts in an iodine stained, formol-ether concentration method. Trophozoites are difficult to detect in a wet preparation.

Microscopy

Where amebic dysentery is suspected, the laboratory should be informed that a "hot stool" is being supplied so that it can be examined within twenty minutes of being passed. On cooling the ameba stop moving which then become very difficult to identify. Direct microscopy should be done by mixing a small amount of the specimen in 0.9% sodium chloride solution. This permits detection of motile trophozoites of *Iodamoeba bütschlii* and can also provide information on the content of the stool (i.e., the presence of leucocytes and red blood cells). On search e.g. primarily for cysts, not for ameba, several stool samples are required to be examined, by direct microscopy and a sensitive concentration technique. Three negative stool samples are required before it can be accepted that there is no amebic infection. Microscopic examination of an amebic abscess aspirate e.g. in the liver or lungs, may reveal hematophagous trophozoites. It must be examined immediately by mixing a drop of warm saline with some aspirated pus on a microscope slide.

Blastocystis hominis

Introduction

B. hominis is an inhabitant of the human intestinal tract. It is capable of both sexual and asexual reproduction by binary fission and of pseudopod extension and retraction.

Morphology

The classic form that is usually seen in stool specimens varies in size from 6-40µm and is characterized by a large membrane bound central body which occupies 90% of the cell. It has no internal nuclear structure and a rim of peripheral granules the function of which is not known.

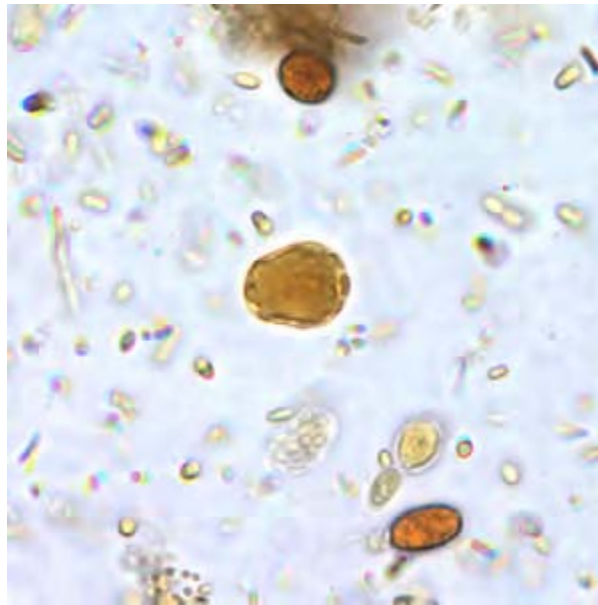


Image 1-12. *Blastocystis hominis* cyst-like forms in a wet mount stained in iodine. (SOURCE: CDC)

Clinical Disease

The pathogenic potential of *B. hominis* is unclear, though this organism has been associated with nausea, fever, vomiting, diarrhea and abdominal pain.

Laboratory Diagnosis

Permanently stained preparations of fecal smears is the procedure of choice for identification, although the organism can be seen in wet preparations. The recommended stains are Fields' and Giemsa.

1.3 Direct Fecal Parasite Concentration Methods

Diagnosis of intestinal parasites is confirmed by the recovery of protozoan trophozoites and cysts, helminth eggs and larvae in the clinical parasitology laboratory. Microscopic examination of feces is essential for the recognition and identification of intestinal parasites. Due to the low density of the parasites in the feces, direct microscopy is useful for the observation of motile protozoan trophozoites and the examination of cellular exudate, is not recommended solely for the routine examination of suspected parasitic infections. It is essential to increase the probability of finding the parasites in fecal samples to allow for an accurate diagnosis. Therefore, a concentration method is employed. (Direct wet mount examination should not be entirely excluded as the trophozoites are usually destroyed during the concentration procedure and therefore, microscopic examination of wet mounts should be performed).

Conventional Methods

Ridley-Allen Method

The concentration procedure used in hospitals requires the use of ether or ethyl acetate as a lipid removing agent and formalin as a fixative. The process involves the use of either expensive brass sieves or the use of tea strainers as the filter element.

Tea strainers have a very open pore structure of at least 600 micron and due to the shape of the strainer it is a non-linear pore size.

The fecal matter is filtered directly through these meshes in a dead stop manner, and hence there is the tendency for occlusion of the filter. There is also a formation of a secondary filter layer, which retains eggs and allows the extrusion of particles (particularly fibers) into the sediment. The net result is a reduction in egg yield and in sample clarity.

- a. Using orange sticks, select a quantity of feces (approx. 1g) to include external and internal portions.
- b. Place in a centrifuge containing 7ml of 10% formalin.
- c. Emulsify the feces in the formalin and filter through the brass/plastic filter into the dish.
- d. Wash the filter and discard any lumpy residue.
- e. Transfer the filtrate to a boiling tube-add 3ml of ether and mix well on a vortex mixer for 15 seconds or mix by hand for 1 minute.
- f. Transfer back to the centrifuge tube and centrifuge at 3,000 rpm for 1 min.
- g. Loosen the fatty plug with an orange stick and pour the supernatant away by quickly inverting the tube.
- h. Allow the fluid on the side of the tube to drain onto the deposit – mix well and transfer a drop to a slide for examination under a coverslip. (WHO Basic lab methods in Medical Parasitology)

The advantages of this method are that it will recover most ova, cysts and larvae and retain their morphology (thus facilitating identification). It has the disadvantage of destroying trophozoite stages and distorting cellular exudate. Liquid feces do not concentrate well, thus it

is necessary in these cases to examine the stool by direct microscopy. Since the sieves are not disposable there is a problem with cleaning for re-use. The system is also open so there is a biohazard and odor issue.

Flotation Method

This technique is predominantly used in veterinary laboratories. By exploiting the density of the parasites, particularly eggs, it allows the parasites to float to the top of a dense solution (final specific gravity of about 1.20) and can then be skimmed from the top of the tube. The most commonly used reagent is zinc sulphate. Operculated eggs as well as schistosome and infertile *Ascaris* eggs are not easily recovered by this method. Also trophozoites are killed due to the high specific gravity and certain other fragile eggs such as *Hymenolepis nana* become distorted.

1. Crush 10-20g (about 1 teaspoon) of feces with applicator sticks and mix well with 10-12ml of saline. Filter the mixture through two layers of dampened surgical gauze into a 15ml conical centrifuge tube.
2. Centrifuge the suspension at 1500 rpm for five minutes. Decant the supernatant into disinfectant. Resuspend the sediment and recentrifuge in saline if there is excessive debris in the sample.
3. Resuspend and thoroughly mix the sediment in 12ml of zinc sulphate solution (specific gravity, 1.18 to 1.20, as verified with a hydrometer).
4. Centrifuge for one minute at 2500 rpm. Place tube in a rack in a vertical position and slowly add enough zinc sulphate with a dropper pipette to fill the tube so that an inverted meniscus forms.
5. Without shaking the tube, carefully place a 22 x 22µm coverslip on top of the tube so that its underside rests on the meniscus. The meniscus should not be so high that fluid runs down the side of the tube carrying parasites away from the cover glass.
6. Allow the tube to stand vertically in a rack with the coverslip suspended on top for ten minutes.
7. Carefully lift the coverslip with its hanging drop containing parasite eggs and cysts on the underside and mount on a clean slide, liquid side down. A small drop of iodine stain may be placed on the slide prior to adding the coverslip. The slide is gently rotated after adding the coverslip to ensure a uniform mixture. The slide is then thoroughly examined microscopically. (Clinical Laboratory procedures)

Chapter 2.

The Ciliates, Coccidia, and Microsporidia

2.1 Infections Acquired Through the Gastrointestinal Tract

In vertebrates, by far the most favorable sites for intestinal parasites are the duodenum, ileum, cecum and large intestine. To survive to reproduce in the gastrointestinal tract the parasites have to adapt to continuous physiological changes relative to the feeding habits of the host, the battery of protein, fat and carbohydrate-splitting enzymes, pH changes and the almost oxygen-free environment. Despite these features many parasites, both protozoa and helminths are capable of colonizing the gastrointestinal tract successfully.

Protozoa are single-celled animals which resemble a single cell of a higher organism. However, the protozoan cell is capable of carrying out vital functions such as reproduction, feeding, and locomotion. Intestinal protozoa include species which can live in the lumen of the intestine and others which additionally live and reproduce in the cells of the intestinal walls.

The protozoa make up a wide spectrum of organisms which have different life cycles and variable characteristics.

The Ciliates

2.2 The Parasites

The ciliates belong to the family Ciliophora. They possess simple cilia or compound ciliary organelles, two types of nuclei and a large contractile vacuole. The only member of the ciliate family to cause human disease is *Balantidium coli*.

Balantidium coli

Introduction

Balantidium coli is widely distributed in warmer climates, which is where human infections most commonly occur. The organisms inhabit the large intestine, cecum and terminal ileum where they feed on bacteria. The most common hosts being humans, pigs and rodents. Human infection is usually from pigs and is rare.

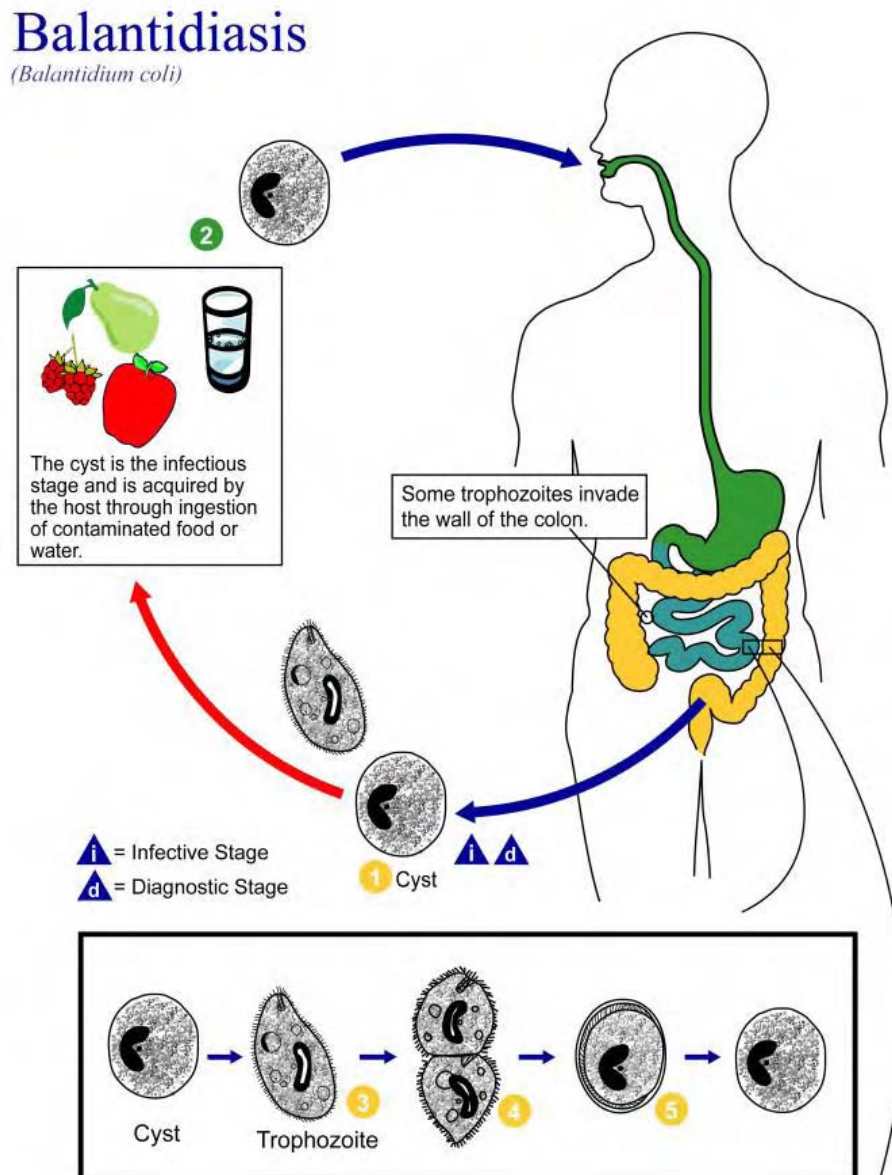


Illustration 2-1. Life cycle of *Balantidium coli*. (SOURCE: PHIL 3380 - CDC/Alexander J. da Silva, PhD/Melanie Moser)

Morphology of the Cyst

The cyst is spherical or ellipsoid and measures from 30-200 μ m by 20-120 μ m. It contains 1 macro and 1 micronucleus. The cilia are present in young cysts and may be seen slowly rotating, but after prolonged encystment, the cilia disappear. Cysts form when diarrhea subsides and the rectal contents become formed. The cyst, ingested by a fresh host, excysts to liberate the trophozoite.

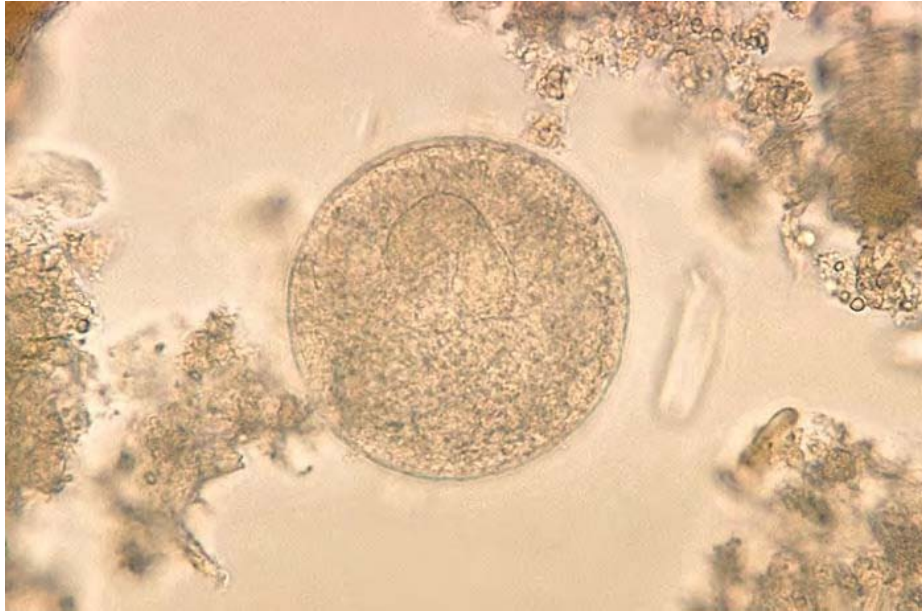


Image 2-1. *Balantidium coli* cyst. (SOURCE: PHIL 584 - CDC/Dr. L.L.A. Moore, Jr.)

Morphology of the Trophozoite

Trophozoites of *B. coli* measure approximately 30-150 μ m in length x 25-120 μ m in width but have been known to attain lengths of up to 200 μ m. They are oval in shape and covered in short cilia. A funnel shaped cytosome can be seen near the anterior end. Multiplication is by binary fission in the trophozoite stage. In an unstained preparation, the organisms are easily recognized because of their size and rapid revolving rotation. In a stained preparation, the characteristic macro and micronuclei may be observed.

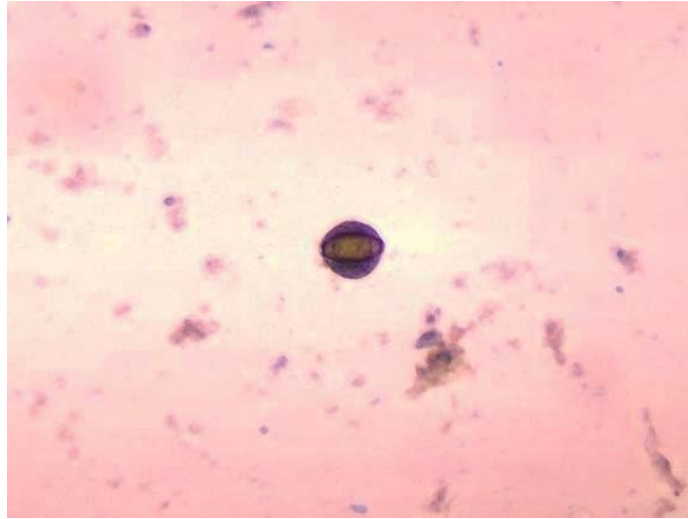


Image 2-2. *Balantidium coli* cyst with *Trichuris* egg inside. Unstained wet mount. (SOURCE: PHIL 1460 - CDC/Dr. Mae Melvin)

Clinical Disease

Severe *B. coli* infections may resemble amebiasis. Symptoms include diarrhea, nausea, vomiting, and anorexia. The diarrhea may persist for long periods of time resulting in acute fluid loss. *Balantidium coli* also has the potential to penetrate the mucosa resulting in ulceration just as those of *Entamoeba histolytica*, but perforation is more common. Metastatic lesions do not occur. Extra-intestinal disease has also been reported, but is rare.

Laboratory Diagnosis

Wet preparations of fresh and concentrated stool samples reveal the characteristic cysts and motile trophozoites. They are easier to identify in direct-smear saline preparations than permanently stained fecal smears.

The Coccidia

The Coccidia are a group of organisms which parasitize the epithelial cells of the intestinal tract. This group includes *Cryptosporidium parvum*, *Cyclospora cayetanensis* and *Isospora belli*. Most of the coccidian infections in man are zoonoses (having the potential to infect animals or arise from animals). In immunocompetent individuals, they usually produce mild, self-limiting infections.

Cryptosporidium parvum

Introduction

Cryptosporidium species, are coccidian protozoa, which are cosmopolitan in distribution, occurring in both developed and underdeveloped countries and causing infection in both humans and their livestock. *Cryptosporidium parvum* is the species responsible for human infection.

Development of *Cryptosporidia* occurs in a parasitophorous vacuole located on the microvillous surface of the epithelial cells.

Life Cycle and Morphology

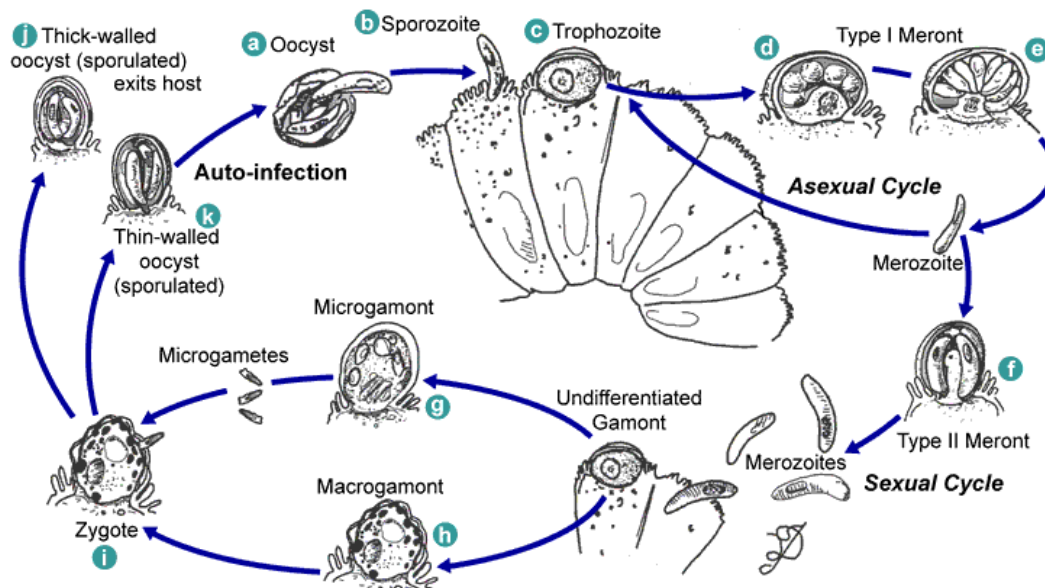


Illustration 2-2. Life cycle of *Cryptosporidium* sp. Sporulated oocysts, containing 4 sporozoites, are excreted by the infected host through feces and possibly other routes such as respiratory secretions. Following ingestion (and possibly inhalation) by a suitable host, excystation (a) occurs. The sporozoites are released and parasitize epithelial cells (b, c) of the gastrointestinal tract or other tissues such as the respiratory tract. In these cells, the parasites undergo asexual multiplication (schizogony or merogony) (d, e, f) and then sexual multiplication (gametogony) producing microgamonts (male) (g) and macrogamonts (female) (h). Upon fertilization of the macrogamonts by the microgametes (i), oocysts (j, k) develop that sporulate in the infected host. Two different types of oocysts are produced, the thick-walled, which is commonly excreted from the host (j), and the thin-walled oocyst (k), which is primarily involved in autoinfection. Oocysts (measuring 4-5µm in diameter and containing 4 sporozoites) are infective upon excretion, thus permitting direct and immediate fecal-oral transmission. (SOURCE: PHIL 3386 - CDC/Alexander J. da Silva, PhD/Melanie Moser)

Clinical Disease

C. parvum is now widely recognized as a cause of acute gastro-enteritis, particularly in children. The infection produces a persistent, watery, offensive diarrhea often accompanied by abdominal pain, nausea, vomiting and anorexia. In immunocompetent persons, symptoms are usually short lived (one to two weeks). The small intestine is the site most commonly affected, symptomatic *Cryptosporidium* infections have also been found in other organs including other digestive tract organs, the lungs, and possibly conjunctiva.

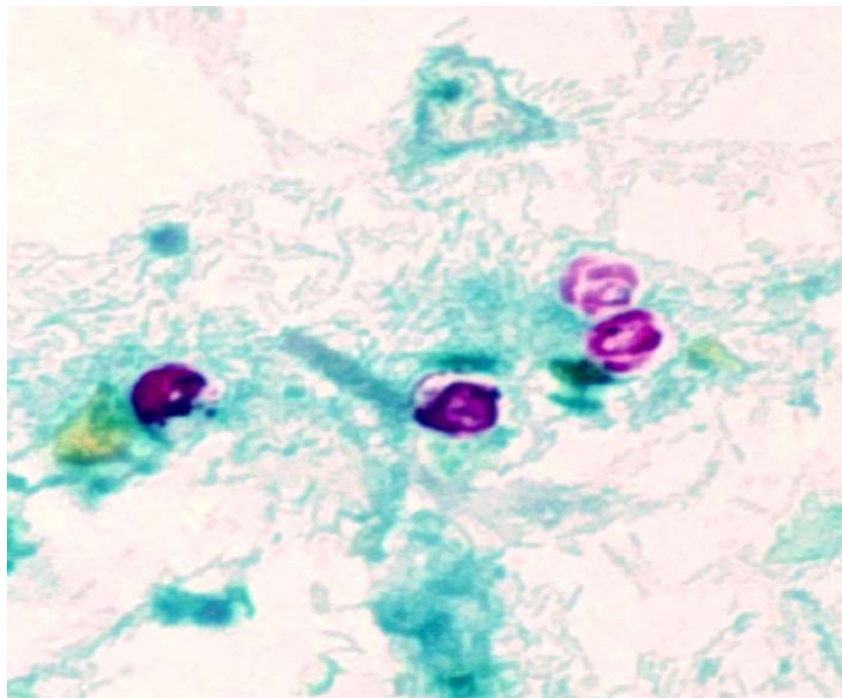


Image 2-3. *Cryptosporidium parvum* oocysts. This photomicrograph revealed the morphologic details of *Cryptosporidium parvum* oocysts, i.e., encapsulated zygotes, which had been stained using the modified acid-fast method. These oocysts exhibit a bright red coloration when using this staining technique, and in this case, you'll note the sporozoites that were made visible inside the two oocysts on the right. Sporozoites are the nucleated, motile stage of development through which many protozoans pass such as *C. parvum*, on their way to becoming adults, and represent a very infectious form of these organisms. The sporozoites will be released from these *C. parvum* oocysts. (SOURCE: PHIL 7829 - CDC/DPDx - Melanie Moser)

Cryptosporidiosis in immunocompromised individuals, especially in HIV patients, can be life threatening, as many as 10% may pass oocysts of *C. parvum*. Infections are characterized by the production of frequent, large volume watery stools and sometimes there is invasion of the pancreas, biliary or respiratory tract.

Oocyst excretion and symptoms may fluctuate during the course of infection. Asymptomatic infections are commonly found in developing countries with poor hygiene, where there is close contact with livestock.

Laboratory Diagnosis

Definitive diagnosis of cryptosporidiosis is by finding the characteristic spherical oocysts in fecal samples. They do not concentrate well using standard concentration techniques and are identified using various staining techniques.

Using the modified Ziehl-Neelsen staining method (fuchsin followed by methylene blue), the oocysts are acid fast. However, staining results within a smear and between specimens are diverse, varying from unstained to partial red staining and complete staining. Fully sporulated forms can be seen in which the red staining sporozoites are within an unstained oocyst wall. When staining the fecal smear with phenol-auramine/carbol-fuchsin, the oocysts appear as bright yellow discs with an "erythrocyte" pattern of staining against a dark red background. Detection of the oocysts can also be achieved by using specific polyclonal or monoclonal antibodies conjugated to fluorescein. These tests are now commercially available and offer a high degree of sensitivity. However, caution must be exercised when they are used to detect oocysts in the fecal smears distributed by NEQAS parasitology. Such specimens are preserved in formalin, which interferes with the fluorescent staining of the parasites, and are thus difficult to detect.

Oocysts in stool specimens (fresh or in storage media) remain infective for extended periods. Thus stool specimens should be preserved in 10% buffered formalin or sodium acetate-acetic acid-formalin (SAF) to render oocysts non-viable. (Contact time with formalin necessary to kill oocysts is not clear; we suggest at least 18 to 24 hours).

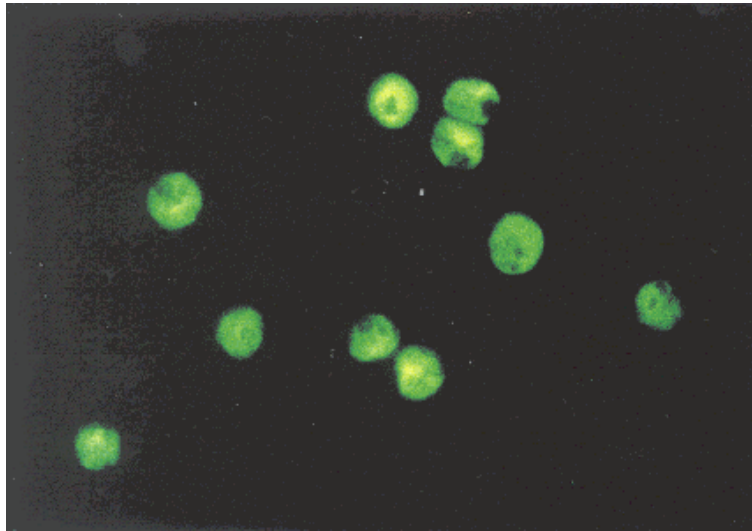


Image 2-4. Staining of *Cryptosporidium parvum* oocysts in a stool smear with monoclonal antibodies conjugated to fluorescein. The *Cryptosporidium* oocysts appear with a peripheral green fluorescence. This technique could be of interest in epidemiological inquiries. (x 670) (SOURCE: Unknown)

Detection of the oocysts can also be achieved by using rapid antigen detection testing kits that specifically detect antigen released by *Cryptosporidium parvu*. These tests are now commercially available and offer a high degree of sensitivity even on specimens that are preserved.

Isospora belli

Introduction

Isospora belli is a coccidian protozoan of cosmopolitan distribution, occurring especially in warm regions of the world infecting both humans and animals.

Life Cycle

The life cycle of *I. belli* involves an asexual (schizogonic stage) and a sexual (sporogonic stage).

Isosporiasis (*Isospora belli*)

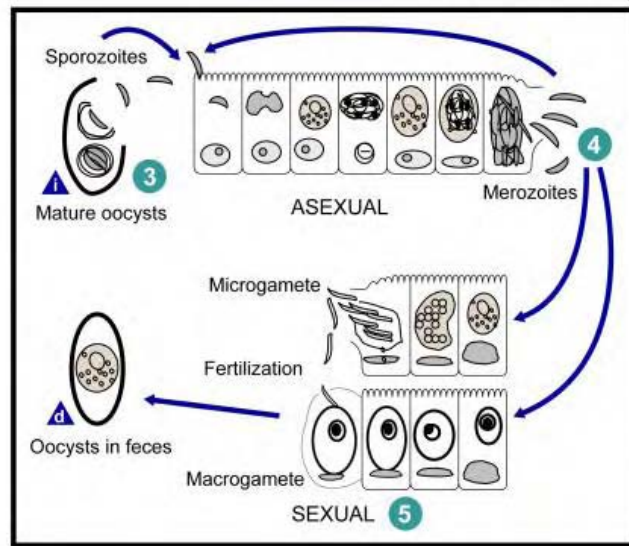
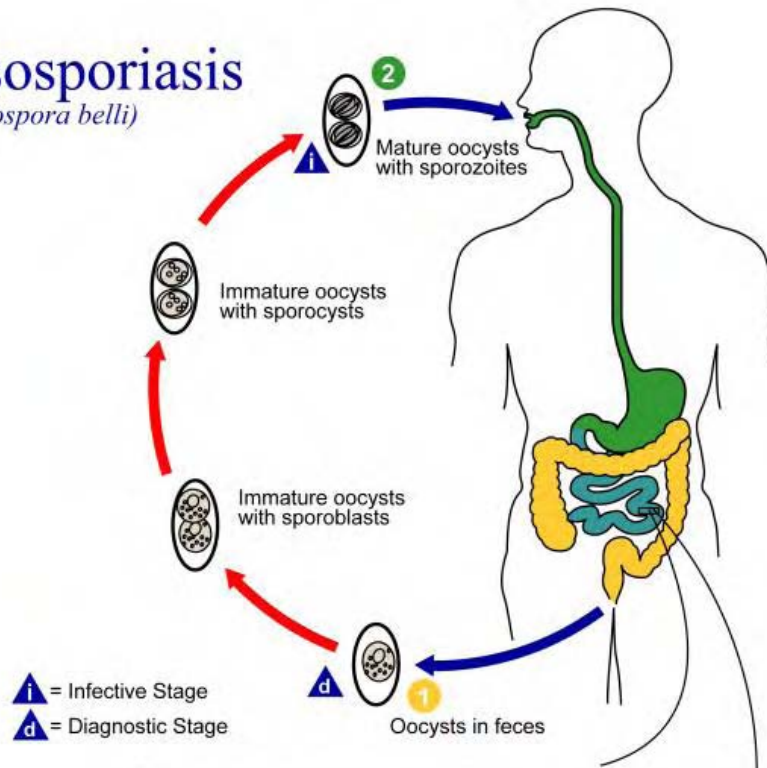


Illustration 2-3. *Isospora belli* life cycle. At time of excretion, the immature oocyst contains usually one sporoblast (more rarely two) **1**. In further maturation after excretion, the sporoblast divides in two (the oocyst now contains two sporoblasts); the sporoblasts secrete a cyst wall, thus becoming sporocysts; and the sporocysts divide twice to produce four sporozoites each **2**. Infection occurs by ingestion of sporocysts-containing oocysts: the sporocysts excyst in the small intestine and release their sporozoites, which invade the epithelial cells and initiate schizogony **3**. Upon rupture of the schizonts, the merozoites are released, invade new epithelial cells, and continue the cycle of asexual multiplication **4**. Trophozoites develop into schizonts which contain multiple merozoites. After a minimum of one week, the sexual stage begins with the development of male and female gametocytes **5**. Fertilization results in the development of oocysts that are excreted in the stool **1**. *Isospora belli* infects both humans and animals. (SOURCE: PHIL 3398 - CDC/Alexander J. da Silva, PhD/Melanie Moser)

Morphology

Infection with *Isospora belli* occurs in both immunocompetent and immunocompromised patients and begins when the mature oocyst is ingested in water or food.

Morphology of oocysts. The mature oocyst contains 2 sporocysts, each containing 4 sporozoites measure on average 35 x 9µm.

Figures 6. and 7. demonstrate fecal smears of oocysts. The sporulated oocyst is the infective stage of the parasite and they excyst in the small intestine releasing sporozoites which penetrate the epithelial cells, thus initiating the asexual stage of the life cycle. The sporozoite develops in the epithelial cell to form a schizont, which ruptures the epithelial cell containing it, liberating merozoites into the lumen. These merozoites will then infect new epithelial cells and the process of asexual reproduction in the intestine proceeds. Some of the merozoites form macrogametes and microgametes (sexual stages) which fuse to form a zygote maturing finally to form an oocyst.

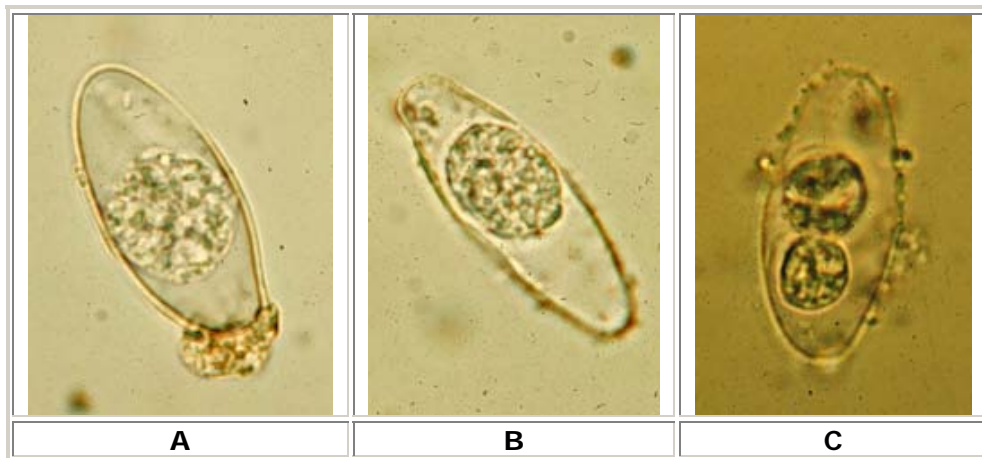


Image 2-5. A, B, C: Oocysts of *Isospora belli*. The oocysts are large (25 to 30 µm) and have a typical ellipsoidal shape. When excreted, they are immature and contain one sporoblast (**A, B**). The oocyst matures after excretion: the single sporoblast divides in two sporoblasts (**C**), which develop cyst walls, becoming sporocysts, which eventually contain four sporozoites each. (Images contributed by Georgia Division of Public Health. (CDC))

Clinical Disease

In the immunocompetent, infection is generally asymptomatic or a self-limiting gastro-enteritis. However, in chronic infections, severe non-bloody diarrhea with cramp-like abdominal pain can last for weeks and result in fat malabsorption and weight loss. Eosinophilia may be present (atypical of other protozoal infections).

In immunocompromised individuals, infants and children, infection ranges from self-limiting enteritis to severe diarrheal illness resembling that of cryptosporidiosis.

Laboratory Diagnosis

Oocysts are thin walled, transparent and ovoid in shape. They can be demonstrated in feces after a formal ether concentration where they appear as translucent, oval structures.

Alternatively, oocysts can be seen in a fecal smear stained by a modified Ziehl-Neelsen method, where they stain a granular red color against a green background, or by phenol-auramine.

Cyclospora cayetanensis

Introduction

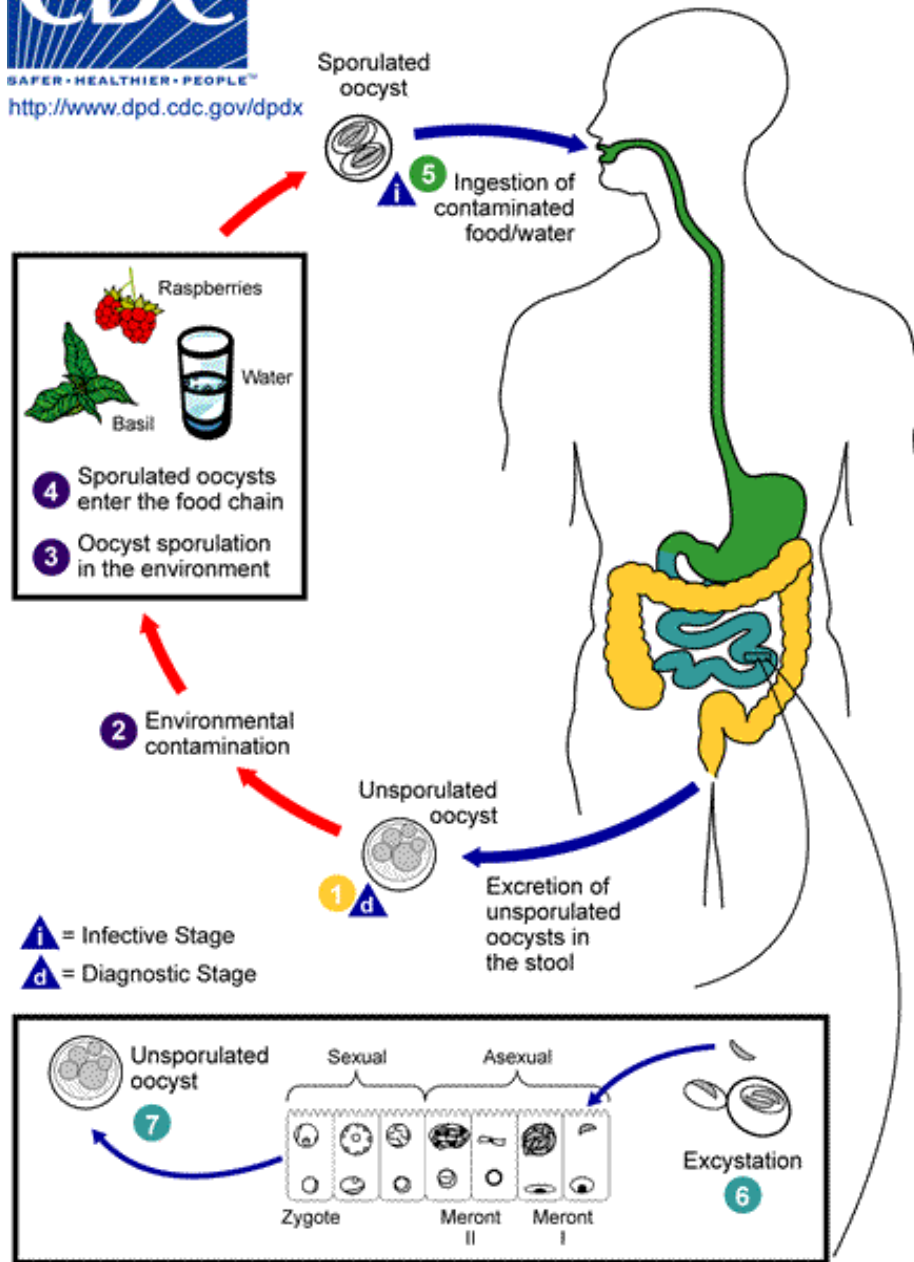
Cyclospora cayetanensis, a coccidian protozoan, has been described in association with diarrheal illness in various countries, in particular Nepal, Pakistan and India. Infection results in a disease with non-specific symptoms. Quite often the disease is the cause of unexplained summer diarrheal illness and similar illness following travel to tropical areas.

Life Cycle and Morphology

The life cycle of this organism is unknown, however environmental data suggest that *Cyclospora*, like *Cryptosporidium* species, is a water-borne parasite. The oocysts of *C. cayetanensis* are spherical, measuring 8-10µm in diameter and the mature oocyst contains 2 sporocysts. Oocysts of *Cyclospora cayetanensis*, are twice as large in comparison with *C. parvum* and are not sporulated (do not contain sporocysts - upon excretion).



SAFER • HEALTHIER • PEOPLE™
<http://www.dpd.cdc.gov/dpdx>



Some of the elements in this figure were created based on an illustration by Ortega et al. *Cyclospora cayetanensis*. In: *Advances in Parasitology: opportunistic protozoa in humans*. San Diego: Academic Press; 1998. p. 399-418.

Illustration 2-4. When freshly passed in stools, the oocyst is not infective **1** (thus, direct fecal-oral transmission cannot occur; this differentiates *Cyclospora* from another important coccidian parasite, *Cryptosporidium*). In the environment **2**, sporulation occurs after days or weeks at temperatures between 22°C to 32°C, resulting in division of the sporont into two sporocysts, each containing two elongate sporozoites **3**. Fresh produce and water can serve as vehicles for transmission **4** and the sporulated oocysts are ingested (in contaminated food or water) **5**. The oocysts excyst in the gastrointestinal tract, freeing the sporozoites which invade the epithelial cells of the small intestine **6**. Inside the cells they undergo asexual multiplication and sexual development to mature into oocysts, which will be shed in stools **7**. The potential mechanisms of contamination of food and water are still under investigation. (SOURCE: CDC)

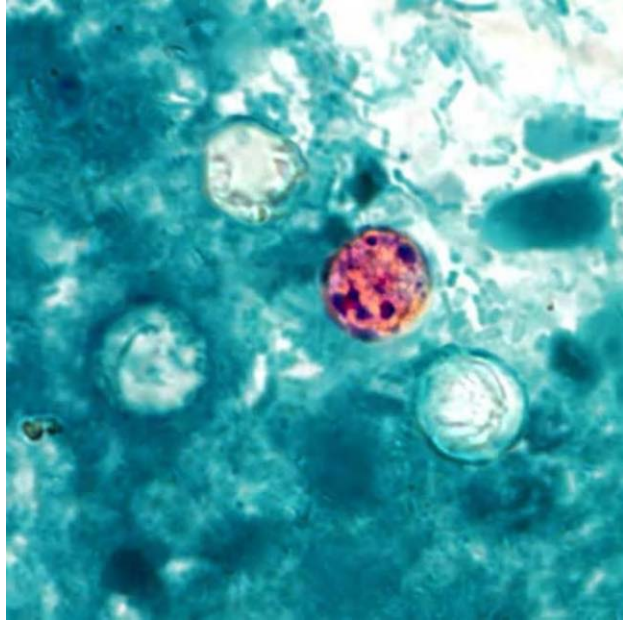


Image 2-6. This photomicrograph of a fresh stool sample, which had been prepared using a 10% formalin solution, and stained with modified acid-fast stain, revealed the presence of four *Cyclospora cayetanensis* oocysts in the field of view. Compared to wet mount preparations, the oocysts are less perfectly round and have a wrinkled appearance due to this method of fixation. Most importantly, the staining is variable among the four oocysts. (SOURCE: PHIL 7827 - CDC/ DPDx - Melanie Moser)

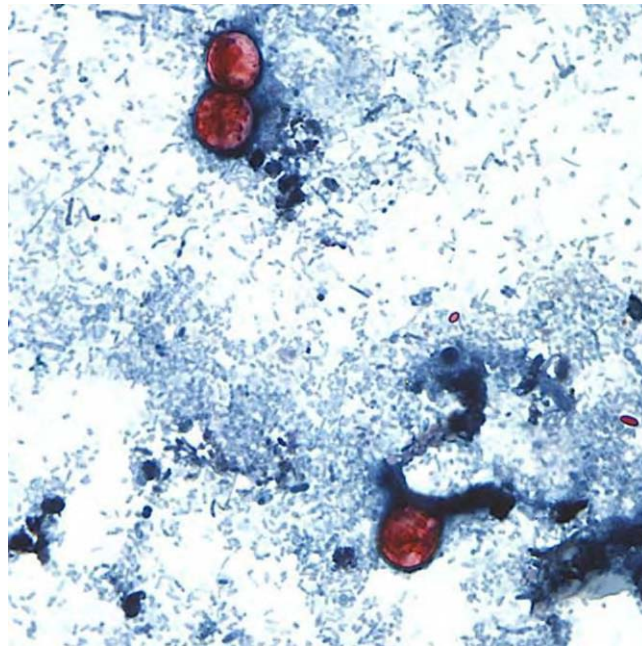


Image 2-7. This photomicrograph of a fresh stool sample, which had been prepared using a 10% formalin solution, and stained with safranin, revealed the presence of three uniformly stained *Cyclospora cayetanensis* oocysts in the field of view. (SOURCE: PHIL 7828 - CDC/ DPDx - Melanie Moser)

Clinical Disease

Patients from whose stools the organism has been isolated have reported nausea, vomiting, weight loss and explosive watery diarrhea. Flatulence and bloatedness, nausea and vomiting, myalgia, low-grade fever, and fatigue are associated symptoms. The site of infection is the small bowel. The disease is usually self-limiting to three to four days but untreated infections can last from several days to a month or longer, and may follow a relapsing course. Some infections are asymptomatic.

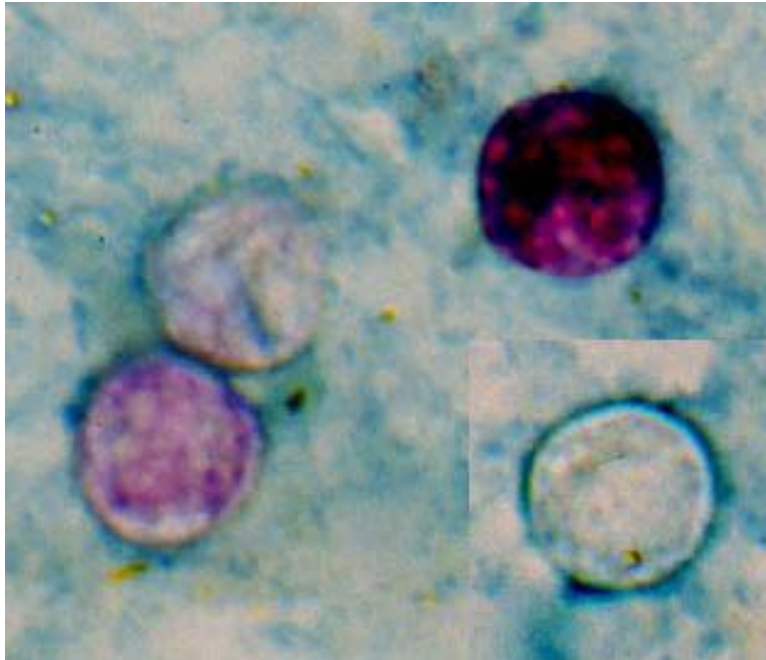


Image 2-8. Four *Cyclospora* oocysts from fresh stool fixed in 10% formalin and stained with modified acid-fast stain. Compared to wet mount preparations, the oocysts are less perfectly round and have a wrinkled appearance. Most importantly, the staining is variable among the four oocysts. (SOURCE: CDC)

Laboratory Diagnosis

The oocysts of *C. cayetanensis* are spherical as can be seen in formol-ether concentrated stool samples by light microscopy. They are refractile spheres which exhibit blue autofluorescence under ultraviolet light. It is important to note that UV microscopes set up for FITC and auramine microscopy only (450-500nm) will fail to detect the autofluorescence of the oocyst. Iodine-quartz microscopes do not produce UV wavelength below 400nm, while both mercury vapor and xenon vapor microscopes must be fitted with a 340-380nm excitation filter to demonstrate autofluorescence.

The oocysts are variably acid-fast when stained by the modified Ziehl-Neelsen method. Some cysts are acid-fast whereas others appear as round holes against a green background. They do not stain well with phenol-auramine.

Microsporidia Species

Introduction

The term microsporidia is also used as a general nomenclature for the obligate intracellular protozoan parasites belonging to the phylum Microsporidia. To date, more than 100 genera and 1,000 species have been described as parasites infecting a wide range of vertebrate and invertebrate hosts. There are at least seven microsporidian species that are well characterized as human pathogens. (Table 2-1.)

Microsporidia are characterized by the production of resistant spores and the polar tubule (or polar filament) which is coiled inside the spore as demonstrated by its ultrastructure.

They have recently come to medical attention as opportunistic pathogens in humans with Acquired Immune Deficiency Syndrome (AIDS) and have been implicated in conditions ranging from enteritis to keratoconjunctivitis.

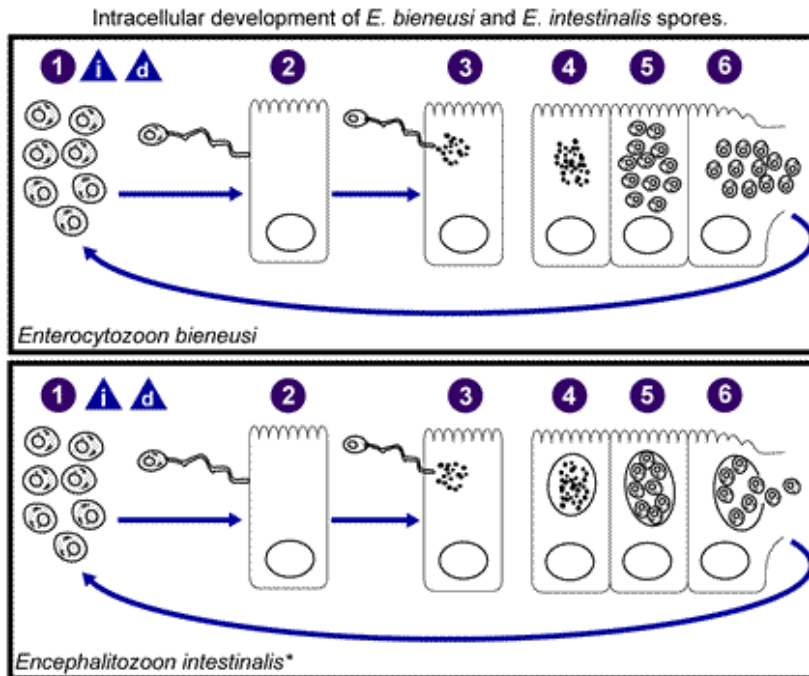
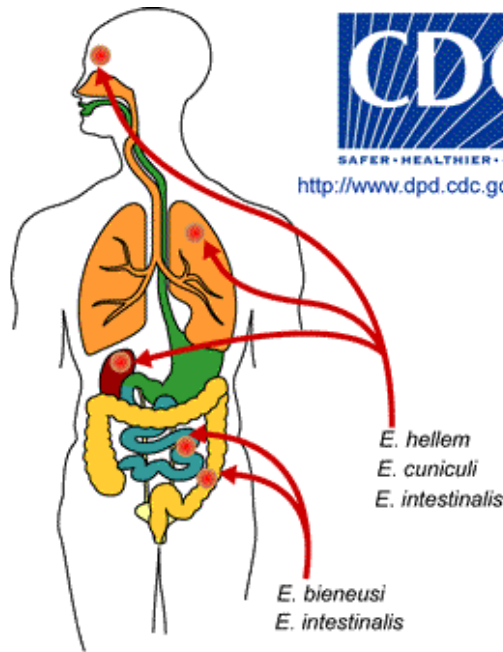
Life Cycle and Morphology

Microsporidia are primitive organisms. They possess no mitochondria and have prokaryotic like ribosomes. Classification is based on the ultrastructural features, which include the number of coils in the polar tubes, the configuration of nuclei and the spore size 1-4 μ m, depending on the species.

▲_i = Infective Stage
 ▲_d = Diagnostic Stage



<http://www.dpd.cdc.gov/dpdx>



*Development inside parasitophorous vacuole also occurs in *E. hellem* and *E. cuniculi*.

Illustration 2-5. Life cycle of *Microsporidia* sp. The infective form of microsporidia is the resistant spore and it can survive for a long time in the environment ①. The spore extrudes its polar tubule and infects the host cell ②. The spore injects the infective sporoplasm into the eukaryotic host cell through the polar tubule ③. Inside the cell, the sporoplasm undergoes extensive multiplication either by merogony (binary fission) or schizogony (multiple fission) ④. This development can occur either in direct contact with the host cell cytoplasm (e.g., *E. bienersi*) or inside a vacuole termed parasitophorous vacuole (e.g., *E. intestinalis*). Either free in the cytoplasm or inside a parasitophorous vacuole, microsporidia develop by sporogony to mature spores ⑤. During sporogony, a thick wall is formed around the spore, which provides resistance to adverse environmental conditions. When the spores increase in number and completely fill the host cell cytoplasm, the cell membrane is disrupted and releases the spores to the surroundings ⑥. These free mature spores can infect new cells thus continuing the cycle. (SOURCE: CDC)

Microsporidia	Size	Associated Disease
<i>Enterocytozoon bieneusi</i>	1µm x 1.5µm	Gastrointestinal and biliary tract infections
<i>Encephalitozoon intestinalis</i>	1.5µm x 2.5µm	Gastrointestinal tract and systemic infections
<i>Encephalitozoon hellem</i>	1.5µm x 1µm	Keratopathy (corneal edema), respiratory tract infection
<i>Encephalitozoon cuniculi</i>	1.5µm x 1µm	Central nervous system disease
<i>Nosema connori</i>	2µm x 4µm	Systemic infections
<i>Nosema corneum</i>	2µm x 4µm	Keratopathy
<i>Pleistophora species</i>	2.8µm x 3.4µm	Myositis

Table 2-1. Microsporidia found in humans and their associated disease. (Cuomo)

In addition to the species in **Table 2-1.**, above, there are other, not well-characterized microsporidian human pathogens. These are designated as *Microsporidium*, a collective taxon that includes *Microsporidium africanum* and *Microsporidium ceylonensis*.

Clinical Disease

The most common microsporeans found in patients with AIDS are *Enterocytozoon bieneusi*, *Encephalitozoon intestinalis* and *Encephalitozoon hellem*. Patients with these infections tend to be severely immunodeficient with a CD4 count less than $100 \times 10^6/L$. Additionally, cases of microsporidiosis have been reported in immunocompromised persons not infected with HIV and in immunocompetent individuals. The clinical manifestations of microsporidiosis are very diverse, varying according to the causal species, with diarrhea being the most common.

Enterocytozoon bieneusi

Infections with *E. bieneusi* are restricted to the enterocytes of the small intestine, resulting in villous atrophy and malabsorption. Clinical symptoms include chronic watery, non-bloody diarrhea, malaise and weight loss.

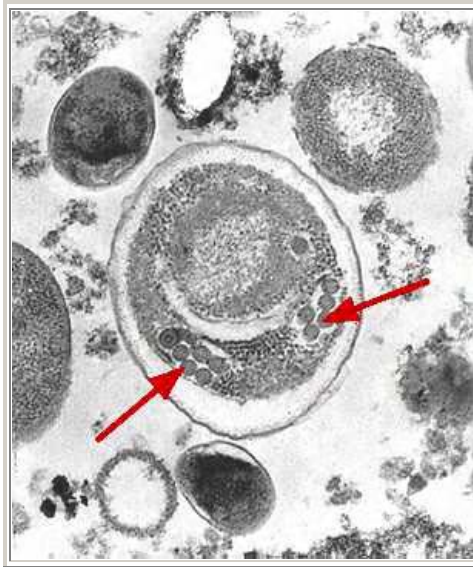


Image 2-9. Electron micrograph of an *Enterocytozoon bienersi* spore. Arrows indicate the double rows of polar tubule coils in cross section which characterize a mature *E. bienersi* spore. (SOURCE: CDC)

Encephalitozoon intestinalis

Infection with *Encephalitozoon intestinalis* occurs in the enterocytes of the small intestine but is more widely disseminated than *E. bienersi* and has been found in the colon, liver and kidney.

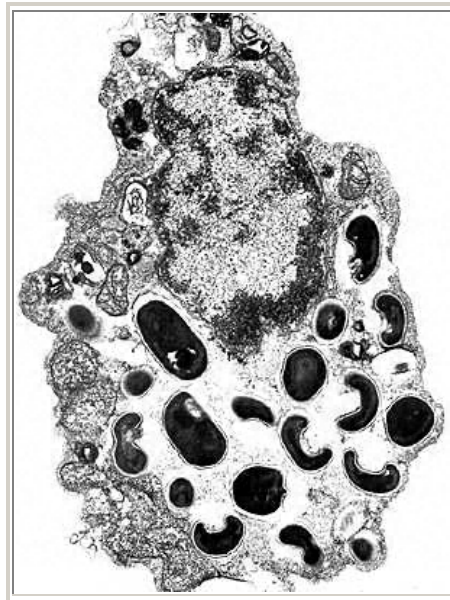


Image 2-10. Electron micrograph of a eukaryotic cell with *Encephalitozoon intestinalis* spores and developing forms inside a septated parasitophorous vacuole. The vacuole is a characteristic feature of this microsporidian species. (SOURCE: CDC)

Encephalitozoon hellem* and *Encephalitozoon cuniculi

These organisms have also been found in disseminated microsporidiosis. Clinical symptoms may include sinusitis, nephritis, hepatitis, keratoconjunctivitis and peritonitis.

Nosema corneum

This organism has been detected in AIDS patients with keratoconjunctivitis.

Laboratory Diagnosis

Initially, the diagnosis of intestinal microsporidiosis depended on tissue biopsies which were stained with Gram's stain and examined by light microscopy. However, in order that ill patients were not subjected to unnecessary invasive procedures, non-invasive diagnostic procedures were developed. The modified Trichrome stain and the Fungiquil fluorescent stain are the stains of choice. Immunofluorescence assays (IFA) using monoclonal and/or polyclonal antibodies are being developed for the identification of microsporidia in clinical samples.

2.3 Examination of fecal specimens for Parasites

Many intestinal disorders are due to intestinal parasites which cannot be diagnosed symptomatically. Laboratory investigation is therefore required and the staff responsible should have adequate expertise in examining fecal specimens for parasitic organisms.

2.4 Relevant information required

The request form should always state the patients clinical symptoms and signs and whether the patient had recent overseas travel. If the patient has had no recent history of overseas travel, examination for *Cryptosporidium*, *Giardia* and Microsporidia, if immunocompromised should be considered. If overseas travel has been undertaken, it is important to note is the patient ill or whether a routine post-tropical screen is requested. The geographical location is also important as it may indicate these parasites which could be present.

2.5 Collection of samples

If a fecal sample is not properly collected and taken care of before examination, it will be of little or no value for accurate diagnosis. This is especially true if protozoa are present. Amoebic trophozoites begin to degenerate one to two hours after passage, as do flagellate trophozoites. Cysts will deteriorate if the fecal specimen is left standing for many hours or overnight, especially at high temperatures.

Helminth eggs and larvae are less affected by the age of the specimen than are protozoa. Nevertheless, changes may occur that could affect their identification; hookworm larvae may become embryonated and larvae may hatch from the eggs risking confusion with *Strongyloides* larvae. Larvae themselves may disintegrate thus making their identification difficult.

To ensure that good specimens are provided for examination, it is important to note the following points.

1. A clean dry container must be used for the collection of fecal samples. Urine and water will destroy trophozoites, if present, and the presence of dirt also causes identification problems.
2. Ideally the specimen should be brought to the lab as soon as it is passed, to avoid deterioration of protozoa and alterations of the morphology of protozoa and helminths.
3. The specimen container should be clearly labeled with the patient's name, date, and time of passage of the specimen.
4. An amount of stool adequate for parasite examination should be collected and a repeat sample requested if too little is supplied. The smallest quantity that should be accepted is about the size of a pigeon's egg.
5. Diarrheal specimens, or those containing blood and mucus, should be examined promptly on arrival in the laboratory. The specimens may contain motile amoebic or flagellate trophozoites and may round up and thus be missed if examination is delayed. Where amoebic dysentery is suggested, the laboratory should be informed that a "hot stool" is being supplied so that it can be examined within twenty minutes of being passed.
6. With the exception of "hot stools" if specimens cannot be examined as soon as they arrive, they should be put in the refrigerator.

2.6 Visual observation of the fecal sample

It is important to observe the macroscopic appearance of the stool as this can give a clue to the type of organisms present. Therefore the consistency; formed, unformed or liquid; the color and the presence or absence of the exudate are reported. The presence of adult worms can also be seen in a freshly passed stool e.g. adult stage of *Ascaris lumbricoides* and *Enterobius vermicularis*. Proglottids of *Taenia* species can also be seen.

2.7 Routine procedure for the microscopic examination of fecal samples for parasites

1. Direct microscopy should be done on all unformed and liquid samples by mixing a small amount of the specimen in 0.9% sodium chloride solution. This permits detection of trophozoites of *Entamoeba histolytica* and *Giardia lamblia*. It can also provide information on the content of the stool i.e. the presence of leucocytes and red blood cells.
2. A formol-ether concentrate should be done on all fecal samples examined for parasites. This reveals the presence of most protozoan cysts, eggs of nematodes, cestodes and trematodes and also the larval stages of some nematodes.
3. A permanently stained direct fecal smear should be used for all bloody, liquid or semi-formed stools. The smear can reveal the presence of intestinal parasites that can be either destroyed or missed by the formol-ether concentration method e.g. *Dientamoeba fragilis*.
4. Specimens from patients with HIV should be left in 10% formalin for one hour before proceeding with parasite examination.

2.8 Principals of Diagnostic Methods for the Identification of Parasites

The principal of the successful identification of fecal parasites is based upon,

1. Measurement - The use of an eyepiece graticule is of the utmost importance, especially for cyst identification.
2. Morphology - In protozoan cysts, the number of nuclei and the presence of inclusions e.g. glycogen mass and chromidial bar, aid the identification of protozoa. In trophozoites, the presence of red cells in amoebae is diagnostic of *Entamoeba histolytica* and flagella also aid identification of some protozoan trophozoites.
3. Appearance - In helminth eggs, the shape of the egg, the thickness of the shell, the color of the ovum and the presence or absence of features such as an operculum, spine or hooklets are diagnostic pointers to the identity of the parasite.
4. Stains also aid in identification of the parasite.

The addition of iodine to formol ether concentrates highlights the internal structure of cysts and helps distinguish between vegetable matter and cysts. Permanently stained fecal smears are useful in demonstrating the nuclear pattern of cysts.

2.9 Problems of identification

Many things in stool specimens look like parasites but are not.

Epithelial cells and macrophages can be confused with amoebic trophozoites, especially macrophages that show slight amoeboid movement and may contain red blood cells. Pus cells can be confused with amoebic cysts. The nuclei appear as 3 or 4 rings and usually stain heavily. The cytoplasm is ragged and the cell membrane is often not seen. Amoebic cysts have a distinct cell wall.

Hair and fibers may be confused with larvae, but they do not have the same internal structure as larvae.

Plant cells can be confused with cysts or eggs. Though plant cells usually have a thick wall and cysts have a thin wall.

2.10 Reporting of Parasites

Ideally, the presence of all parasites should be reported, whether they are pathogens or non-pathogens. This particularly applies to the presence of cysts. However, if it is laboratory practice to report all cysts, the report should state whether they are pathogenic or non-pathogenic.

The stage of the parasite should always be reported. For the protozoa, whether cysts or trophozoites are present; the stage of larvae as in *Strongyloides*; and whether adult stages or eggs of helminths are present.

Chapter 3.

The Flagellates

3.1 Infections Acquired Through the Gastrointestinal Tract

The Flagellates belong to the Mastigophora and possess more than one flagellum. Beating these flagella enable them to move. A cytosome may be present which helps in the identification of the species.

Flagellates possess one advantage over their amoeboid relatives in that they can swim. Therefore, enabling them to invade and adapt to a wider range of environments unsuitable for other amoebae. They are able to change from a flagellated free-swimming environment to a non-flagellated tissue dwelling stage and *vice versa*.

Flagellates are known to inhabit the reproductive tract, alimentary canal, tissue sites and also the blood stream, lymph vessels and cerebrospinal canal.

There are pathogenic and commensal species of flagellates. The flagellates which are encountered in the intestinal tract are *Giardia lamblia*, *Dientamoeba fragilis*, *Chilomastix mesnili*, *Trichomonas hominis*, *Retortamonas intestinalis* and *Enteromonas hominis* (the latter two being less common). The trophozoites are easily recognized in saline preparations by their motility. However, accurate identification is done on a permanently stained fecal smear. Cysts are more commonly seen than the trophozoite.

Giardia lamblia

Introduction

Giardia lamblia is a flagellate of world-wide distribution. It is more common in warm climates than temperate climates. It is the most common flagellate of the intestinal tract, causing *Giardiasis*. Humans are the only important reservoir of the infection. The infection is most common in parts of the world where sanitation is at its lowest. *Giardiasis* is an infection of the upper small bowel, which may cause diarrhea. Only *Giardia* spreads disease.

Morphology of the Trophozoites

The trophozoites of *G. lamblia* are flattened pear shaped and are an average size of 15µm long, 9µm wide and 3µm thick. When stained, the trophozoite is seen to have two nuclei, two slender median rods (axostyles), and eight flagella arising from the anterior end. They have

been described as looking like tennis rackets without the handle (they are often seen as having a comical face-like appearance when looking at the front view).

The movement of the trophozoites is described as tumbling leaf motility, using their four pairs of flagella for locomotion. They attach themselves to the surface of the jejunal or duodenal mucosa by their disc-like suckers which are found on their ventral surface. They multiply in the gut by binary fission. Once the trophozoites drop off the mucosal surface they are normally carried in the intestinal contents down the gut where they usually encyst.

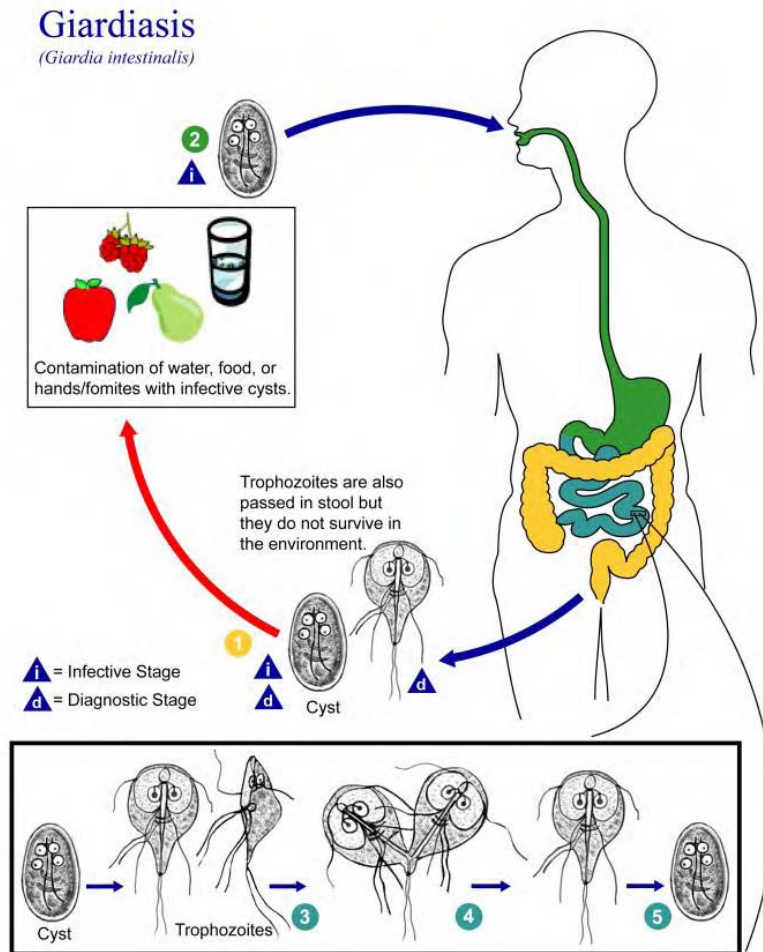


Illustration 3-1. Life cycle of *Giardia lamblia*. Cysts are resistant forms and are responsible for transmission of Giardiasis. Both cysts and trophozoites can be found in the feces (diagnostic stages) ①. The cysts are hardy and can survive several months in cold water. Infection occurs by the ingestion of cysts in contaminated water, food, or by the fecal-oral route (hands or fomites) ②. In the small intestine, excystation releases trophozoites (each cyst produces two trophozoites) ③. Trophozoites multiply by longitudinal binary fission, remaining in the lumen of the proximal small bowel where they can be free or attached to the mucosa by a ventral sucking disk ④. Encystation occurs as the parasites transit toward the colon. The cyst is the stage found most commonly in nondiarrheal feces ⑤. Because the cysts are infectious when passed in the stool or shortly afterward, person-to-person transmission is possible. While animals are infected with *Giardia*, their importance as a reservoir is unclear. (SOURCE: PHIL 3394 - CDC/Alexander J. da Silva, PhD/Melanie Moser)

Morphology of Cysts

The cysts of *G. lamblia* are 8-12 μ m in length and are ellipsoid in shape. They contain four nuclei which tend not to be obvious. Longitudinal fibrils consisting of the remains of axonemes and parabasal bodies may also be seen. Cysts may appear to shrink from the cell wall. The cysts are infective as soon as they are passed.

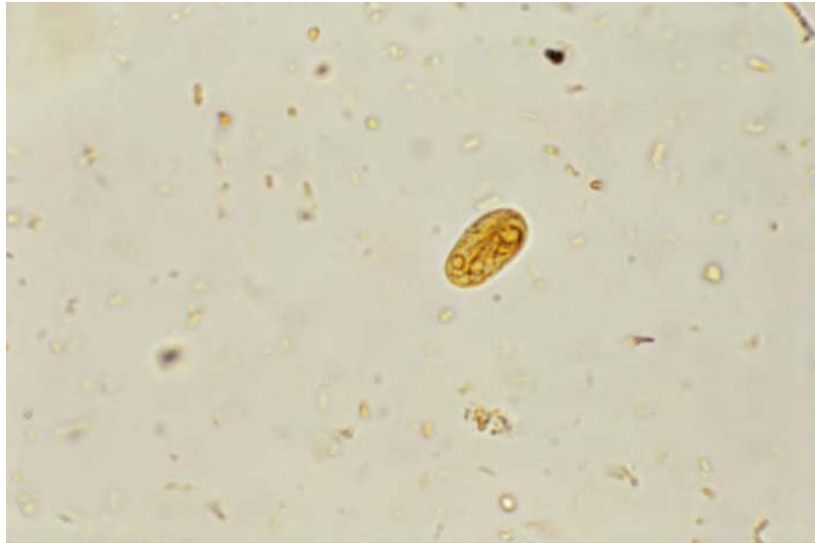

Image 3-1. *Giardia lamblia* cyst iodine stained. (SOURCE: PHIL 3741 – CDC/ Dr. Mae Melvin)

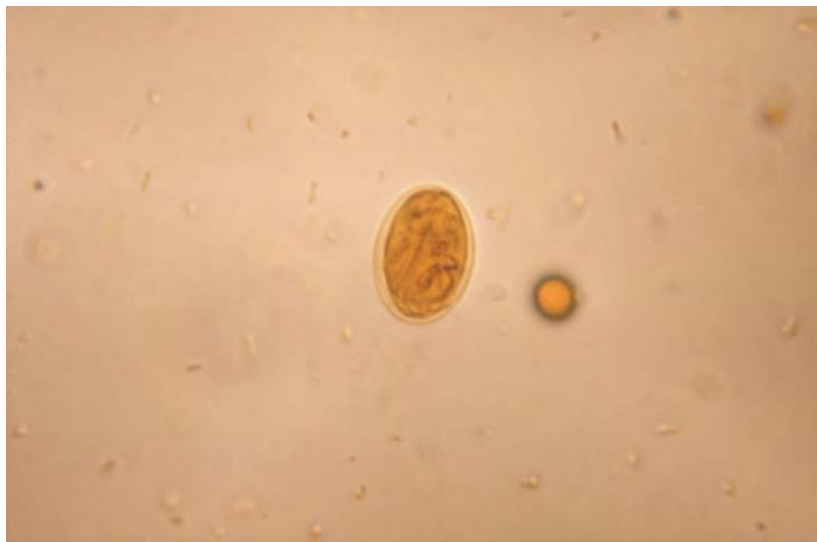

Image 3-2. *Giardia lamblia* cyst iodine stained. (SOURCE: PHIL 3742 – CDC/ Dr. Mae Melvin)

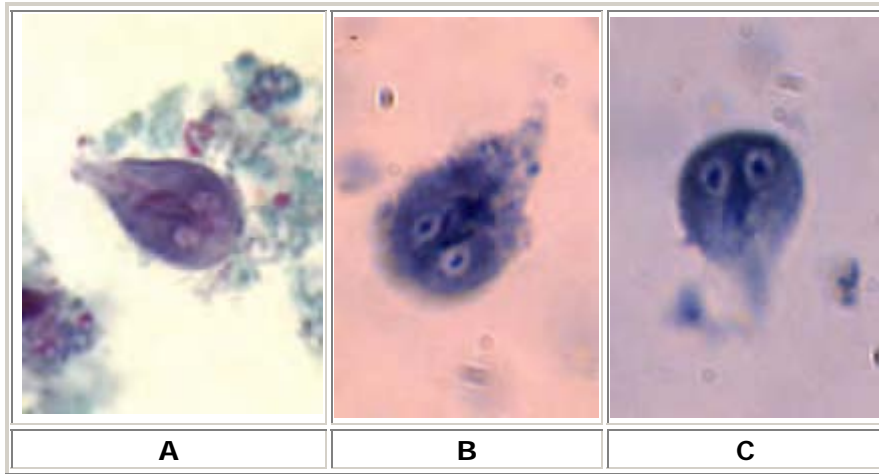


Image 3-3. A, B, C Three trophozoites of *Giardia intestinalis*, stained with trichrome (**A**) and stained with iron hematoxylin (**B** and **C**). Each cell has two nuclei with a large, central karyosome. Cell size: 9 to 21 μm in length. (SOURCE: CDC)

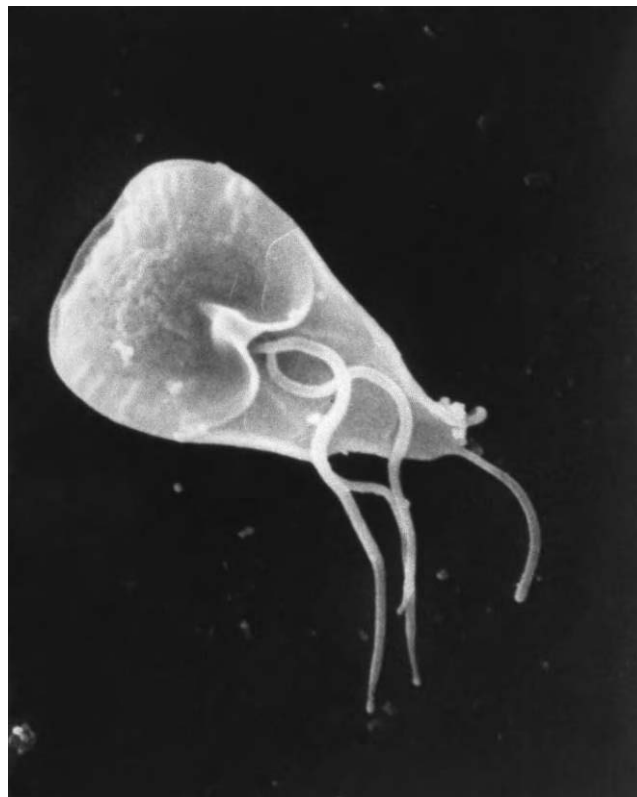

Image 3-4. This scanning electron micrograph (SEM) revealed some of the external ultrastructural details displayed by a flagellated *Giardia lamblia* protozoan parasite. *G. lamblia* is the organism responsible for causing the diarrheal disease "giardiasis". Once an animal or person has been infected with this protozoan, the parasite lives in the intestine, and is passed in the stool. Because the parasite is protected by an outer shell, it can survive outside the body, and in the environment for long periods of time. (SOURCE: PHIL 8698 - CDC / Janice Carr)

Clinical Disease

Giardia lamblia colonizes the small intestine where the trophozoites adhere to the mucosal surface by means of their sucking disc. Cysts are produced as the parasites descend the intestinal tract although trophozoites can be passed in the feces in severe infections. *G. lamblia* is transmitted through ingestion of cysts in contaminated water or food. Cysts can survive outside the body for several weeks under favorable conditions. The main symptoms are abdominal pain, flatulence, and episodic diarrhea with steatorrhea and periodical soreness in severe cases. No blood or mucus is normally seen. However 50% of *G. lamblia* infections are symptomless, although severe infections may develop in immunocompromised hosts. What determines susceptibility is poorly understood. After swallowing cysts for the first time, symptoms commonly develop 2-6 weeks later.

Laboratory Diagnosis

Cysts can be found by examination of the deposit of a formol-ether concentrate of a stool preparation. The oval cysts with thick walls serve as characteristic features for these organisms. (Keys 3-1. & 3-2.) The flagella disintegrate and form a central 'streak' which becomes visible when stained with iodine or MIF (merthiolate-iodine-formaldehyde). Cysts may be excreted intermittently; therefore it is important to examine more than one stool. Stools are usually passed 3-8 times / day and are usually pale, offensive, rather bulky and accompanied by much flatus.

Trophozoites are found by examination of saline wet preparations of fresh, diarrheic stool, duodenal or jejunal aspirate or in a permanently stained fecal preparation.

Trophozoites can also be found in the jejunal aspirate. These can be recovered by the String Test or Enterotest capsule and the material examined microscopically for motile trophozoites.

Trophozoites and cysts can be found to be scarce in chronic infections. Serological methods of diagnosis are proving to be useful as means of diagnosis. An ELISA to detect IgM in serum provides evidence of a current infection. A polyclonal antigen-capture ELISA can be used to demonstrate submicroscopic infections in feces and an IgA-based ELISA will detect specific antibodies in saliva. Table 3-1. details useful morphological features that are similar between species of flagellate and are used in laboratory diagnosis. Detection of the trophozoites and cysts can also be achieved by using rapid antigen detection testing kits that specifically detect antigen released by *Giardia lamblia*. These tests are now commercially available and offer a high degree of sensitivity even on specimens that are preserved and can be detected days before any trophozoites and cysts are shed.

Dientamoeba fragilis

Introduction

Dientamoeba fragilis is an amoeba-flagellate with a cosmopolitan distribution. The life cycle is not completely known.

Morphology of Trophozoites and Lifecycle

D. fragilis are relatively small, varying from 3-22µm in diameter and there can be considerable variation in size among organisms in the same fecal sample. The organisms have only a trophozoite stage and in a permanently stained preparation, one, two or rarely three nuclei can be seen, two being the most common. The nuclear chromatin is usually fragmented into three to five granules but these have not been visualized by Giemsa Stain, and there is normally no peripheral chromatin on the nuclear membrane. The cytoplasm is usually vacuolated and may contain ingested debris as well as some large uniform granules. The cytoplasm can also appear uniform and clean with a few inclusions. *D. fragilis* live in the lumen of the cecum and upper colon.

Dientamoeba fragilis Infection

(*Dientamoeba fragilis*)

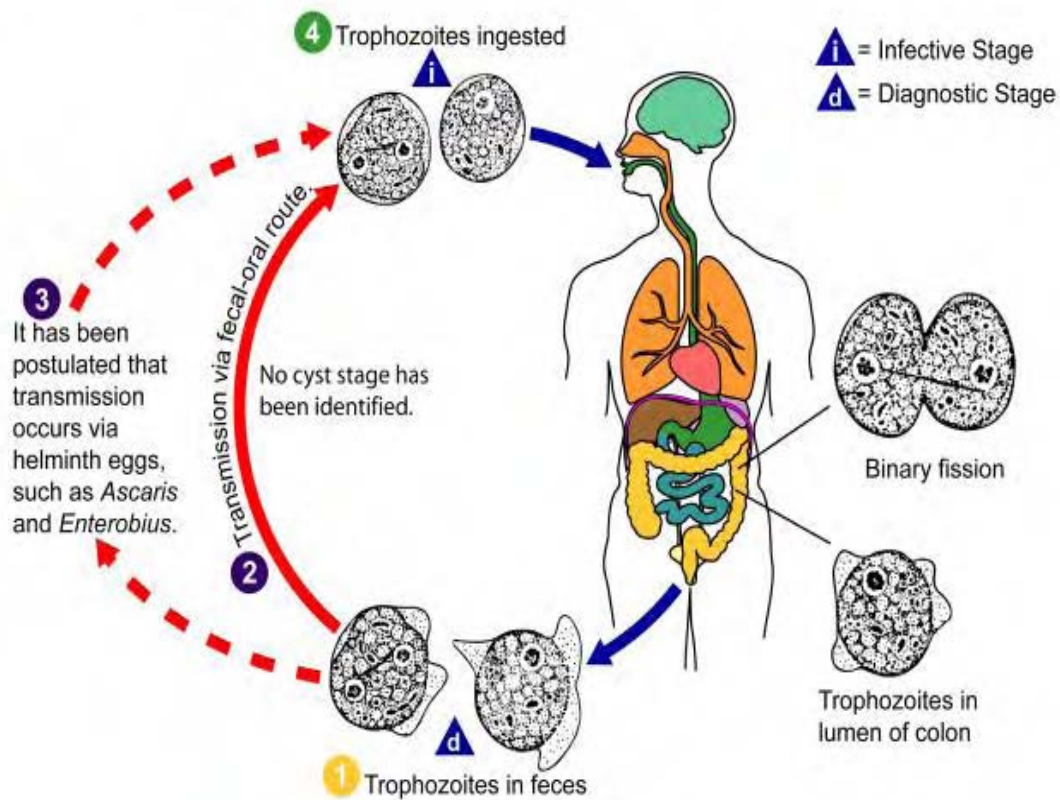


Illustration 3-2. This is an illustration of the assumed life cycle of *Dientamoeba fragilis*, the cause of a protozoan parasitic infection. (SOURCE: PHIL 3389 - CDC/Alexander J. da Silva, PhD/Melanie Moser)

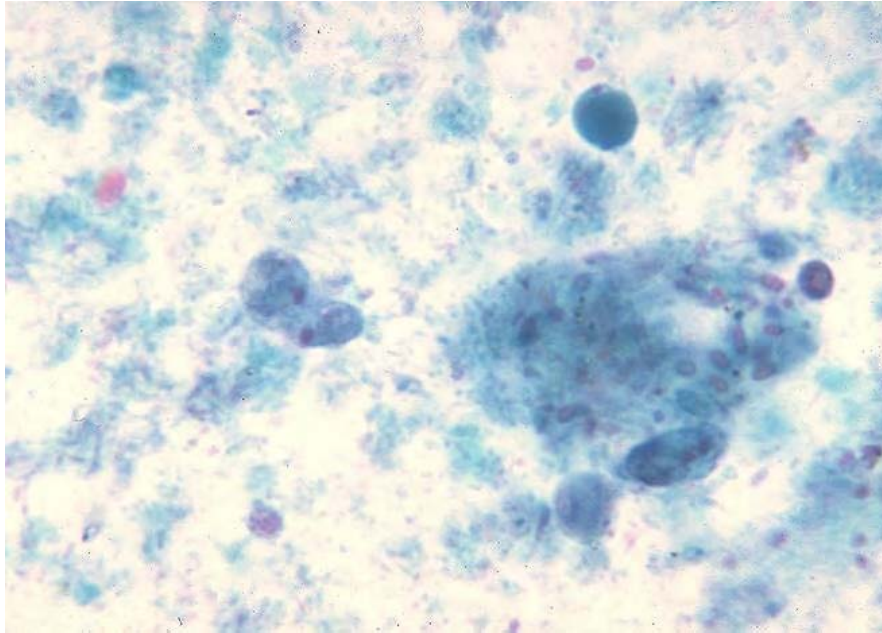


Image 3-5. *Dientamoeba fragilis*. Trichrome stain. (SOURCE: PHIL 548 – CDC)

Pathogenesis

This is a controversial area. The organism has been reported in association with mucous diarrhea, abdominal pain and tenderness. Nausea, vomiting and low-grade fever have also been reported in a number of cases. The precise role of this organism as a cause of disease remains to be determined.

Laboratory Diagnosis

Diagnosis is dependent on examination of the fresh direct wet preparation or permanently stained smears prepared from unformed or formed stools with mucus. It is particularly important that permanently stained smears of stool preparations should be examined, because survival times of the organism in terms of morphology, is very limited and specimens must be examined immediately or preserved in a suitable fixative as soon as possible after defecation. The recommended stains are Fields' and Giemsa stain (trophozoites are destroyed in a formal-ether concentrate). **Table 3-1.** details useful morphological features that are similar between species of flagellate and are used in laboratory diagnosis.

Trichomonas hominis

Introduction

This flagellate is cosmopolitan in its distribution. It is thought to be non-pathogenic although it has been associated with diarrheic stools. It is the most commonly found flagellate next to *G.*

lamblia and *D. fragilis*. Found in a wide host range including non-human primates, cats, dogs and various rodents.

Trichomoniasis (*Trichomonas vaginalis*)

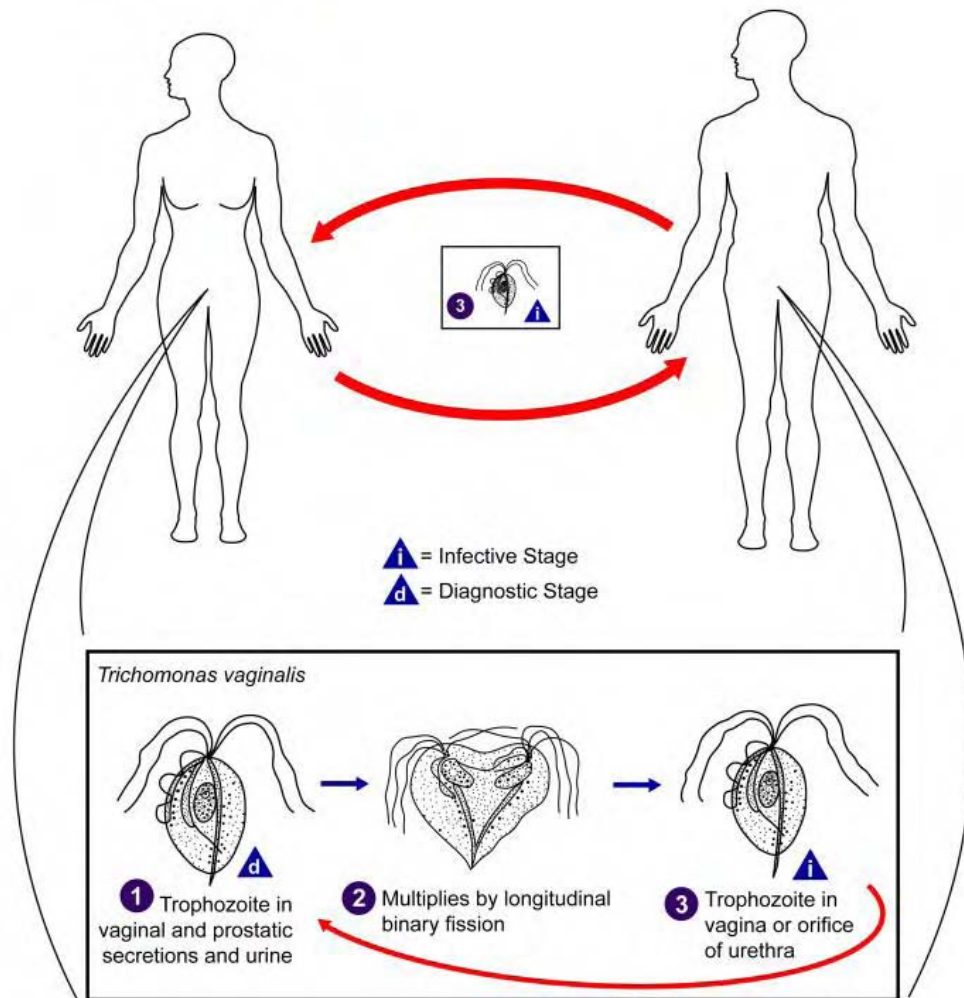


Diagram 3-3. This is an illustration of the life cycle of *Trichomonas vaginalis*, the causal agent of Trichomoniasis. (SOURCE: PHIL 3423 - CDC/Alexander J. da Silva, PhD/Melanie Moser)

Morphology of Trophozoites

Trichomonas hominis do not have a cystic stage. The trophozoites measure from 5-15 μ m in length by 7-10 μ m in width. The shape is pyriform and has an axostyle which runs from the nucleus down the centre of the body and extends from the end of the body. They also possess an undulating membrane which extends the entire length of the body and projects from the body like a free flagellum (this feature distinguishes it from other trichomonads). The characteristic number of flagella is five; there is some deviation from this number. They also

have a single nucleus at the anterior end. Trichomonads swim with a characteristic wobbly movement, which makes them unmistakable during diagnosis.

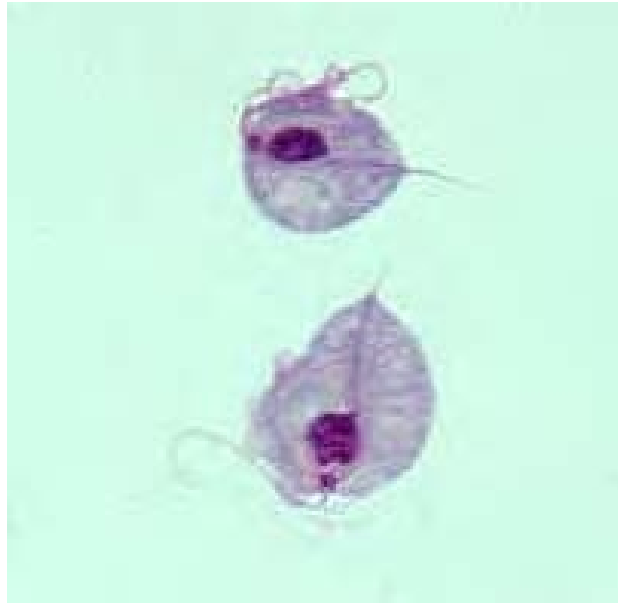

Image 3-6. Two trophozoites of *Trichomonas vaginalis* obtained from in vitro culture. Smear was stained with Giemsa. (SOURCE: CDC)

Laboratory Diagnosis

In a fresh stool, the flagellates move very rapidly in a jerky, non-directional manner. The axostyle and undulating membrane are diagnostic. The flagellates are difficult to stain; however, the axostyle can be seen on a stained preparation and is diagnostic. **Table 3-1** details useful morphological features that are similar between species of flagellate and are used in laboratory diagnosis.

Chilomastix mesnili

Introduction

Chilomastix mesnili is cosmopolitan in distribution although found more frequently in warm climates. It is thought to be non-pathogenic although the trophozoite has been associated with diarrheic stool. This is the largest flagellate found in man with an incidence of 1-10% being in the large intestine.

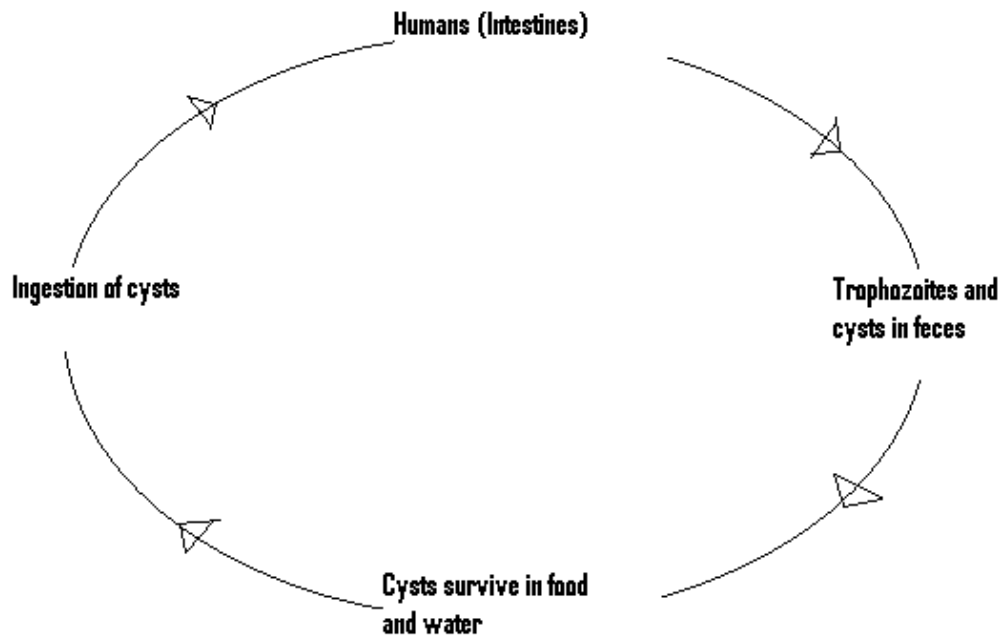


Illustration 3-4. The life cycle of *C. mesnili* (Cuomo)

Morphology of the Trophozoite

The trophozoites of *C. mesnili* are pear shaped and measure 6-20 μ m in length. They have one large nucleus with a small karyosome and three flagella that extend from the nucleus at the anterior end of the parasite. A distinct oral groove or cytosome can be seen near the nucleus with its sides being supported by two filaments. They are known to move in a directional manner.

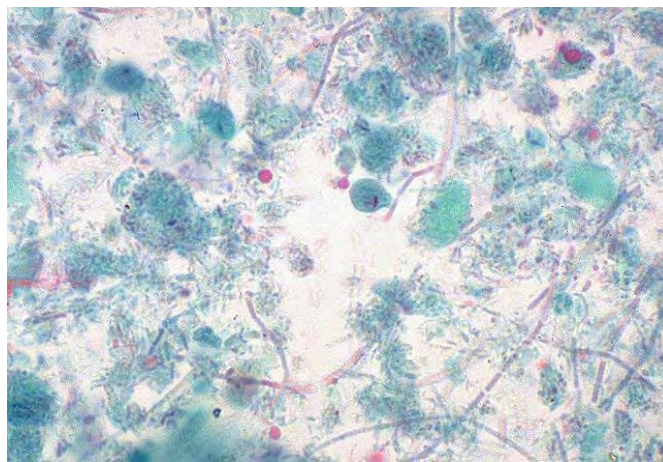


Image 3-7. *Chilomastix mesnili* cyst. (SOURCE: PHIL 426 - CDC /Dr. Mae Melvin)

Morphology of cysts

The cysts are 6-9 μ m; they have a large single nucleus with a large karyosome. They also have a prominent side knob giving it a characteristic lemon shape. The cytosome is evident with a curved shepherds crook fibril. It also has a characteristically coiled filament which when stained is darker in color.

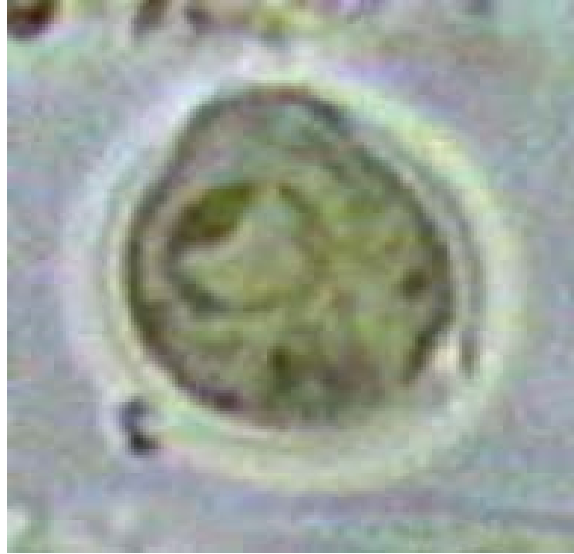

Image 3-8. *Chilomastix mesnili* cysts are excreted with feces and constitute the transmission form of the micro-organism. The uninucleated lemon shaped cysts are seen with a little protuberance at one end and a prominent cytostome. (Iodine stained). (6 μ m) (CDC)

Laboratory Diagnosis

The characteristic lemon shaped cysts can be seen in a formol-ether concentrate. Motile organisms can be seen in a wet preparation of a fresh stool however the characteristic morphology is evident in a permanently stained preparation. **Table 3-1** details useful morphological features that are similar between species of flagellate and are used in laboratory diagnosis.

Enteromonas hominis

Introduction

Enteromonas hominis is a small flagellate and is rarely encountered in man. It is found in both warm and temperate climates and is considered to be non-pathogenic.

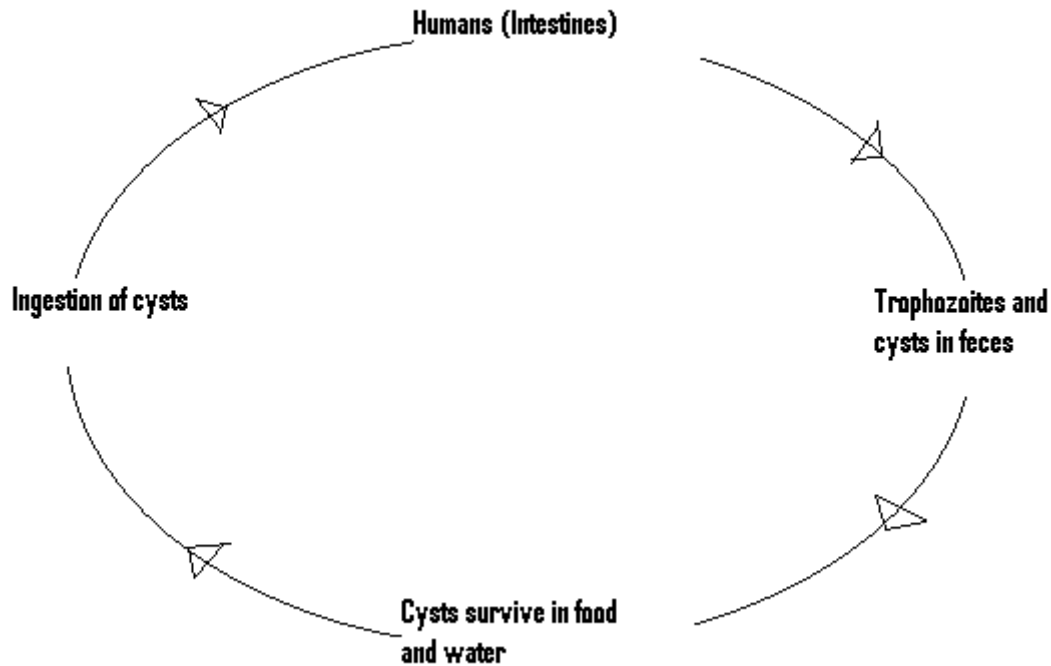


Illustration 3-5. The life cycle of *E. hominis* (Cuomo)

Morphology of the Trophozoite

The trophozoites are oval and 4-10 μ m in length. They have four flagella, three anterior flagella and one adheres to the body ending in a tail, producing a jerky rotational movement. They have one nucleus with a large karyosome that is evident in a stained preparation.

Morphology of the Cyst

The cysts are oval and range between 6-8 μ m in length. They have up to four nuclei with a bipolar tendency.

Laboratory Diagnosis

The cysts are seen in a formol-ether concentrate. The cysts have no distinguishing characteristics and thus can be confused with *E. nana* or even yeasts. The characteristic trophozoites can be seen in a permanently stained fecal smear. **Table 3-1.** details useful morphological feature's that are similar between species of flagellate and are used in laboratory diagnosis.

Retortamonas intestinalis

Introduction

Retortamonas intestinalis like *Enteromonas hominis* is a small flagellate and is rarely encountered. It is found in both warm and temperate climates and is considered to be non-pathogenic.

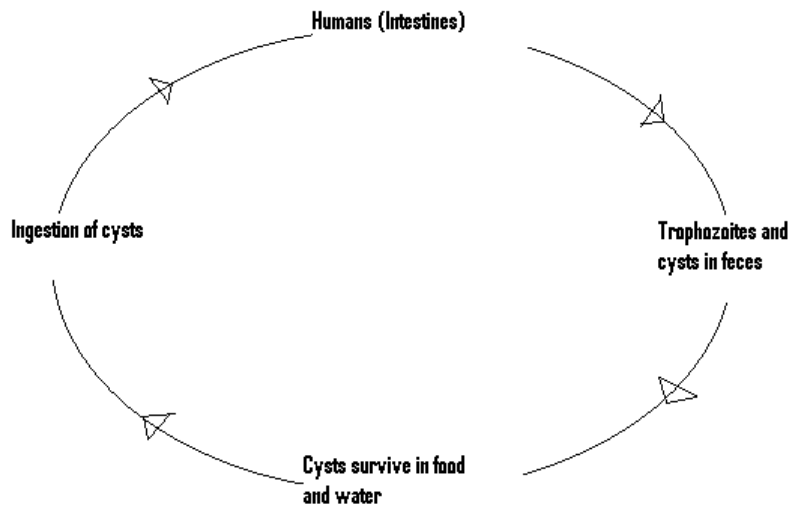


Illustration 3-6. Life cycle of *Retortamonas intestinalis* (Cuomo)

Morphology of the Trophozoite

The trophozoite is small, measuring between 4 μ m and 9 μ m. Its movement is jerky and rotational and has two anterior flagella and a prominent cytosome that can be seen in an unstained preparation. It has a relatively large nucleus at the anterior end with a small compact karyosome.

Morphology of the Cyst

The cysts are small and pear shaped. They range in size between 4-7 μ m with one large nucleus frequently near the centre. The fibril arrangement from the nucleus is suggestive of a birds beak. This is characteristic of *R. intestinalis* cysts.

Laboratory Diagnosis

The small pear shaped cysts are uncharacteristic in an unstained formol-ether preparation. However, the addition of iodine reveals the characteristic bird beak fibrillar arrangement in the

pear shaped cyst. In a fresh stool preparation, the two anterior flagella and cytosome can be seen in the trophozoite. In a permanently stained preparation, the large nucleus with small central karyosome is diagnostic. The below Tables detail useful morphological features which are similar between species of flagellate and are used in laboratory diagnosis.

3.2 Identifying Flagellates

It is important to know and understand the morphological features which differentiate each species of flagellate from one other. The below Tables details the important features that are used when identifying flagellates found in human stool samples. Trophozoites and cysts can be seen in saline mounts of fresh feces. On occasions, species identification may require stained preparations.

Species	Size (Length)	Shape	Motility	Number of Nuclei	Number of Flagella*	Other Features
<i>Trichomonas hominis</i>	8-20 μm . Usual range, 11-12 μm .	Pear shaped.	Nervous, jerky.	1 Not visible in unstained mounts.	3-5 anterior. 1 posterior.	Undulating membrane extending length of body.
<i>Chilomastix mesnili</i>	6-24 μm . Usual range, 10-15 μm .	Pear shaped.	Stiff, rotary.	1 Not visible in unstained mounts.	3 anterior. 1 in cytosome.	Prominent cytostome extending 1/3-1/2 length of body. Spiral groove across ventral surface.
<i>Giardia intestinalis</i>	10-20 μm . Usual range, 12-15 μm .	Pear shaped.	"Falling leaf."	2 Not visible in unstained mounts.	4 lateral. 2 ventral. 2 caudal.	Sucking disk occupying 1/2-3/4 of ventral surface. Median bodies lying horizontally or obliquely in lower part of body.
<i>Enteromonas hominis</i>	4-10 μm . Usual range, 8-9 μm .	Oval.	Jerky.	1 Not visible in unstained mounts.	3 anterior. 1 posterior.	One side of body flattened. Posterior flagellum extends free posteriorly or laterally.
<i>Retortamonas intestinalis</i>	4-9 μm . Usual range, 6-7 μm .	Pear shaped or oval.	Jerky.	1 Not visible in unstained mounts.	1 anterior. 1 posterior.	Prominent cytostome extending approximately 1/2 length of body.

* Not a normal feature for identifying species in routine stool samples

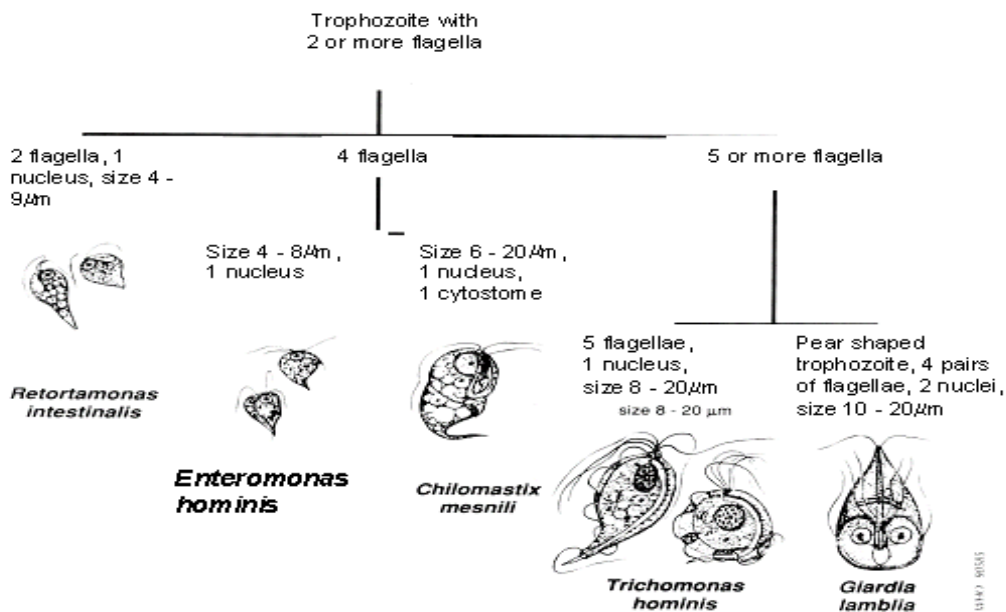
Table 3-1. Differential Morphology of Protozoa Found in Stool Specimens of Humans: Flagellates-Trophozoites (SOURCE: CDC)

Species	Size (Length)	Shape	Number of Nuclei	Other Features
<i>Trichomonas hominis</i>	No cyst.			
<i>Chilomastix mesnili</i>	6-10 μm . Usual range, 8-9 μm .	Lemon shaped with anterior hyaline knob.	1. Not visible in unstained preparations.	Cytostome with supporting fibrils. Usually visible in stained preparations.
<i>Giardia intestinalis</i>	8-19 μm . Usual range. 11-12 μm .	Oval or ellipsoidal.	Usually 4. Not distinct in unstained preparations. Usually located at one end.	Fibrils or flagella longitudinally in unstained cysts. Deep staining fibers or fibrils may be seen lying laterally or obliquely across fibrils in lower part of cyst. Cytoplasm often retracts from a portion of cell wall.
<i>Enteromonas hominis</i>	4-10 μm . Usual range, 6-8 μm .	Elongated or oval.	1-4, usually 2 lying at opposite ends of cyst. Not visible in unstained mounts.	Resembles <i>E. nana</i> cyst. Fibrils or flagella are usually not seen.
<i>Retortamonas intestinalis</i>	4-9 μm . Usual range, 4-7 μm .	Pear shaped or slightly lemon shaped.	1. Not visible in unstained mounts.	Resembles <i>Chilomastix</i> cyst. Shadow outline of cytostome with supporting fibrils extends above nucleus.

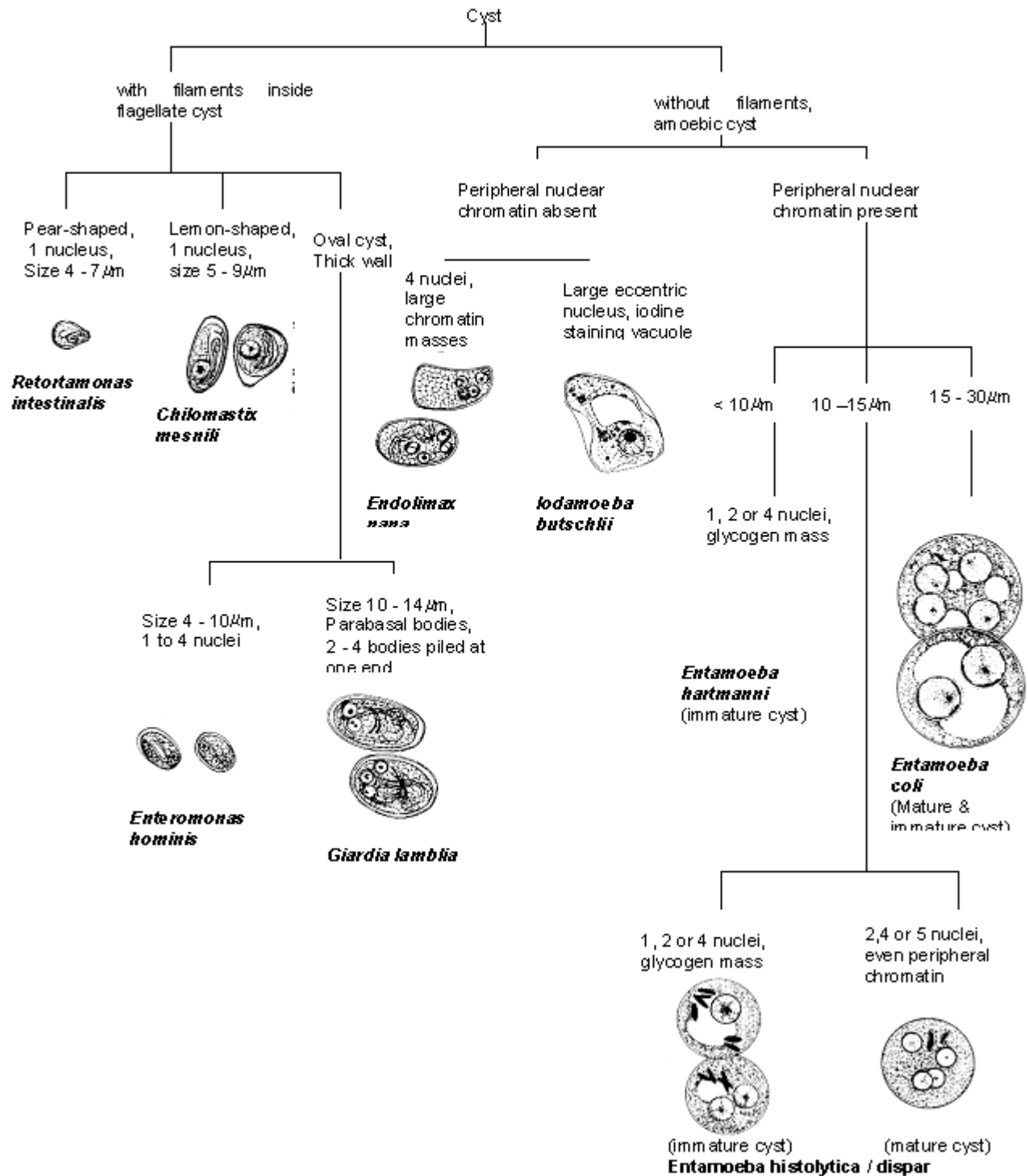
Table 3-2. Differential Morphology of Protozoa Found in Stool Specimens of Humans: Flagellates-Cysts (SOURCE: CDC)

Flagellate trophozoites are best identified in fresh saline mounts, allowing you to observe the way that they move. Use **Key 3-1.** to help to identify stained flagellate trophozoites. Iodine solutions are used primarily to stain flagellate cysts, this makes it possible to see the structure of the nuclei. Use **Key 3-2.** to help to identify amebic and flagellate cysts:

Key 3-1. Flagellates (Adapted and redrawn, WHO, 1991)



Key 2. Key to differentiating flagellate and amoebic cysts. (Adapted and redrawn, WHO, 1991)



Chapter 4.

The Cestodes

4.1 Identifying Intestinal Helminths

Helminth Parasites - The word "worm" is used loosely to describe organisms with elongated bodies and a more or less creeping habit.

Although the word "Helminth" does mean "worm," in zoological terms it is more restricted to members of the phyla Platyhelminths, Nematoda, and Acanthocephala.

There are three groups of medically important helminths; Cestodes (tapeworms), Nematodes (roundworms) and Trematodes (flukes).

These parasites live in both the body spaces (gut lumen, bile ducts, lungs, oral cavity, etc.) and in tissues (blood, muscles and skin).

4.2 Infections Acquired Through the Gastrointestinal Tract

The cestodes (or tapeworms) form a group of worms, exhibiting two unmistakable morphological features; they all possess flat, ribbon like bodies and lack an alimentary canal.

Adult tapeworms usually inhabit the alimentary canal of their hosts (though they occasionally are found in the bile or pancreatic ducts) and attach themselves to the mucosa by means of a scolex. Despite the lack of a digestive system they do absorb food from the hosts intestine; thereby providing the tapeworms a habitat that is associated with high nutritional levels, feeding the tapeworms high growth rate.

Larvae on the other hand show a wide range of habitat preferences, being found in almost any organ of both vertebrate and invertebrate hosts. Though most larval species show a preference for a particular site.

This lack of an alimentary canal markedly separates tapeworms from nematodes and trematodes. The outer tegument of the body must serve not only as a protective coating but also as a metabolically active layer through which nutritive material can be absorbed, along with secretions and waste material to be transported out of the body.

The body consists of a chain of segments or proglottids, which can be immature, mature or gravid; the latter of which contain a fully developed uterus packed with eggs. Therefore, each tapeworm is made up of a 'string of individuals' having a complete set of reproductive organs

in progressive degrees of sexual maturity and budding off from a body attached to the host tissue by a head or scolex.

Except for *Hymenolepis nana*, which can develop directly in the same host, the lifecycle of tapeworms involves both an intermediate and definitive host.

Species	Size	Shape	Color	Stage of Development When Passed	Specific Features and Variations
Cestodes					
<i>Taenia saginata</i> <i>Taenia solium</i>	35 µm. Range, 31-43 µm.	Spherical with thick striated shell.	Walnut brown.	Embryonated. 6-hooked oncosphere present inside a thick shell.	Thick, striated shell. Eggs of <i>T. solium</i> and <i>T. saginata</i> are indistinguishable and species identification should be made from proglottids or scoleces. " <i>Taenia</i> " spp. should be reported if only eggs are found.
<i>Hymenolepis nana</i>	47 µm x 37 µm. Range, 40-60 µm x 30-50 µm.	Oval. Shell consists of 2 distinct membranes. On inner membrane are two small "knobs" or poles from which 4 to 8 filaments arise and spread out between the two membranes.	Colorless, almost transparent.	Embryonated. 6-hooked oncosphere inside shell.	Polar filaments.
<i>Hymenolepis diminuta</i> *	72 µm. Range, 70-86 µm x 60-80 µm.	Round or slightly oval. Striated outer membrane and thin inner membrane with slight poles. Space between membranes may appear smooth or faintly granular.	Yellow.	Embryonated. 6-hooked oncosphere inside shell.	Resembles <i>H. nana</i> but lacks polar filaments. Poles are rudimentary and often hard to see.
<i>Dipylidium caninum</i> *	35-40 µm. Range, 31-50 µm x 27-48 µm.	Spherical or oval. 5-15 eggs (or more) are enclosed in a sac or capsule.	Colorless.	Embryonated. 6-hooked oncosphere inside shell.	Eggs are contained in a sac or capsule which ranges in size from 58 µm to 60 µm x 170 µm. Occasionally capsules are ruptured and eggs are free.
<i>Diphyllobothrium latum</i>	66 µm x 44 µm. Range, 58-76 µm x 40-51 µm.	Oval or ellipsoidal with an inconspicuous operculum at one end and a small "knob" at the other end.	Yellow to brown.	Unembryonated. Germinal cell is surrounded by a mass of yolk cells which completely fills inner area of shell. Germinal cell is usually not visible.	Egg resembles hookworm egg but has a thicker shell and an operculum.

Table 4-1. Differential Morphology of the Diagnostic Stages of Helminths Found in Humans: Eggs (Cestodes) (SOURCE: CDC)

Taenia species

Introduction

Taenia species are the most common cestode parasites of humans. More than 60 million people are infected with *T. saginata* (beef tapeworm) world wide and about four million are infected with *T. solium* (pork tapeworm). The life cycle of a *Taenia* species can be seen in **Illustration 4-1**. *T. saginata* has a cosmopolitan distribution, but is more common in developing countries where hygiene is poor and the inhabitants have a tendency of eating raw or insufficiently cooked meat. *T. saginata* is the most common adult tapeworm found in man. *T. solium* is virtually extinct in Europe and the USA.

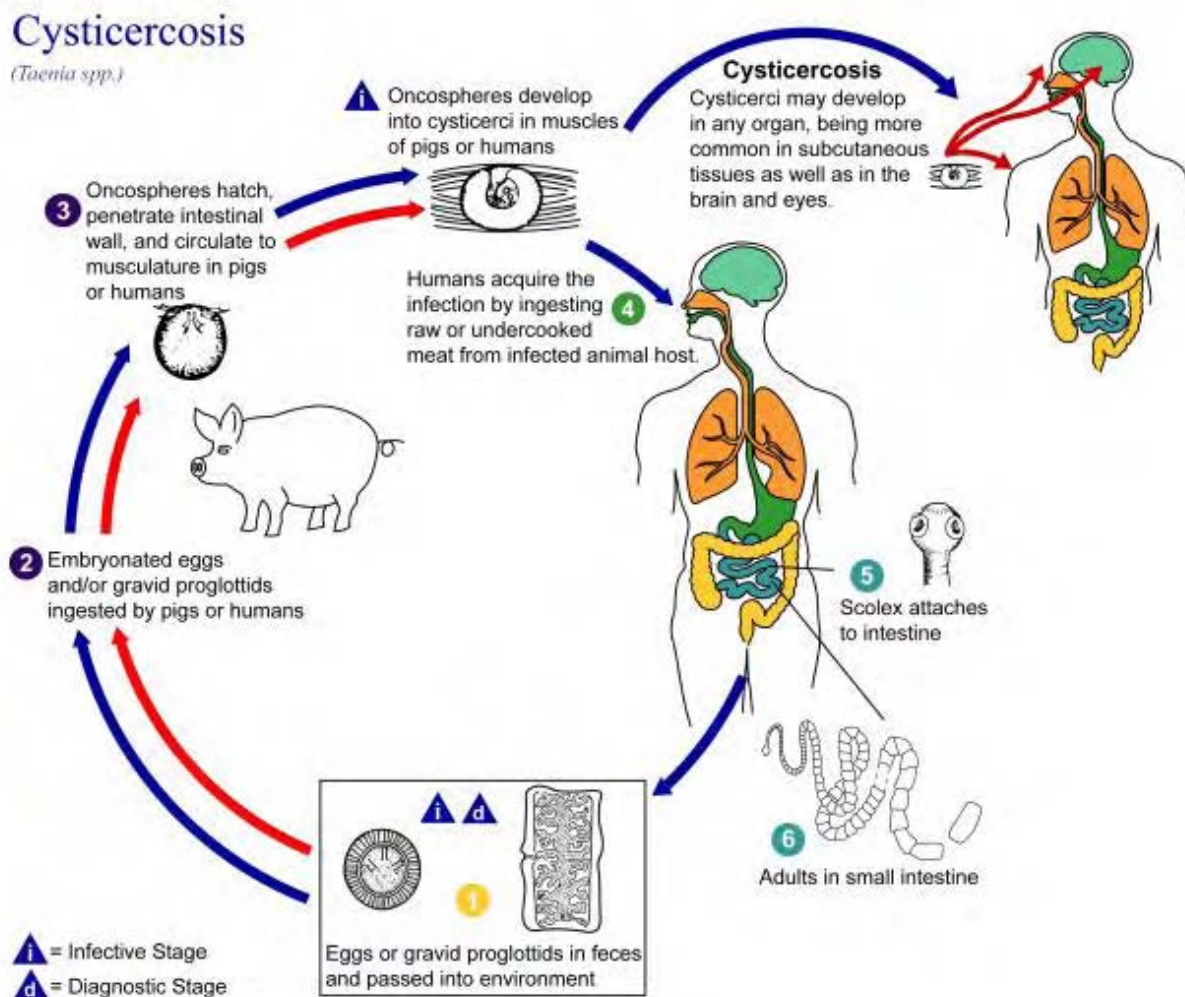


Illustration 4-1. This is the life cycle of *Taenia spp.*, the causal agents of Cysticercosis. Cysticercosis is an infection of both humans and pigs with the larval stages of the parasitic cestode, *Taenia solium*. This infection is caused by ingestion of eggs shed in the feces of a human tapeworm carrier **1**. Pigs

and humans become infected by ingesting eggs or gravid proglottids ², ⁷. Humans are infected either by ingestion of food contaminated with feces, or by autoinfection. In the latter case, a human infected with adult *T. solium* can ingest eggs produced by that tapeworm, either through fecal contamination or, possibly, from proglottids carried into the stomach by reverse peristalsis. Once eggs are ingested, oncospheres hatch in the intestine ³, ⁸ invade the intestinal wall, and migrate to striated muscles, as well as the brain, liver, and other tissues, where they develop into cysticerci ⁹. In humans, cysts can cause serious sequelae if they localize in the brain, resulting in neurocysticercosis. The parasite life cycle is completed, resulting in human tapeworm infection, when humans ingest undercooked pork containing cysticerci ⁴. Cysts evaginate and attach to the small intestine by their scolex ⁵. Adult tapeworms develop, (up to 2 to 7 m in length and produce less than 1000 proglottids, each with approximately 50,000 eggs) and reside in the small intestine for years ⁶. (SOURCE: PHIL 3387 - CDC/Alexander J. da Silva, PhD/Melanie Moser)

Both humans and cattle or pigs are necessary to the complete life cycle of *Taenia* species. (In Europe and the USA cattle are the normal intermediate hosts, but in the tropics several other ruminants, e.g. goat, sheep llama and giraffe, may serve as the intermediate hosts.) Eggs ingested by the intermediate hosts usually contain oncospheres. The oncospheres then hatch out in the duodenum, pass into the intestine where they penetrate the intestinal wall and are then carried by the circulation to be deposited in tissues (usually muscle). There they develop into cysticerci larva which are white and ovoid, measuring approximately 8 x 5µm.

Humans become infected by ingesting inadequately, cooked beef or pork with cysticerci, containing an invaginated protoscolex. The protoscolexes evaginate and pass into the small intestine where they attach themselves to the mucosa and develop into adult worms.

Eggs and proglottids are passed out in the feces, and are then eaten by the intermediate host, thus, perpetuating the life cycle.

Morphology

Ova of *Taenia* species are spherical, yellowish brown and measure 31-34µm in diameter. The shell is thick and radially striated. Within the shell, the oncosphere has 3 pairs of hooklets. However, the microscopic appearance of the ova of *T. saginata* and *T. solium* are identical. (Table 4-1. highlights some of the differences between the two species)

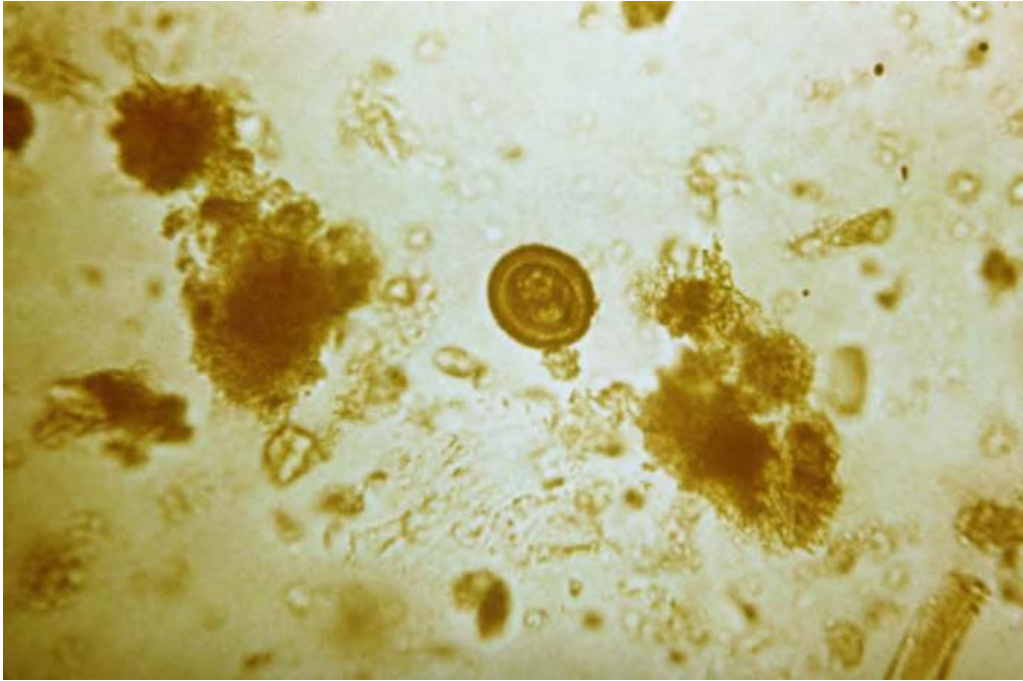

Image 4-1. The eggs *Taenia saginata* and *Taenia solium* are rounded or subspherical, with a thick radially striated brown shell. The diameter is 31 - 43 μm . Inside each shell is an embryonated oncosphere with 6 hooks. (SOURCE: PHIL 4832 – CDC)

The length of the adult *T. saginata* is 4-8 meters long and that of *T. solium* is 3-5 meters long.

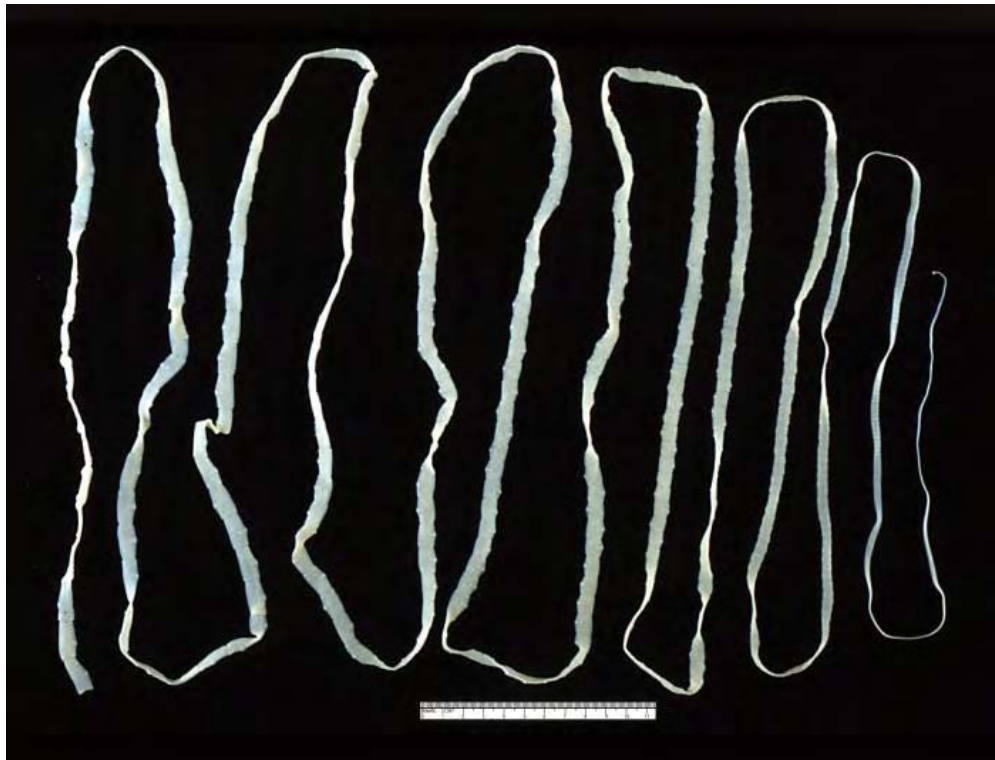


Image 4-2. This is an adult *Taenia saginata* tapeworm. (SOURCE: PHIL 5260 – CDC)

The proglottids of *Taenia* species can be identified by the number of uterine branches; 7-13 for *T. solium* and 15-20 for *T. saginata*.

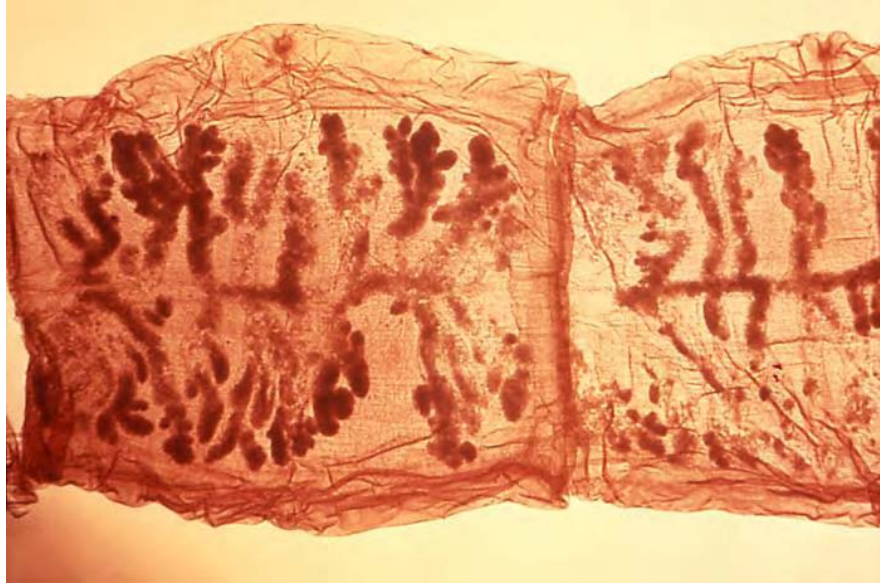


Image 4-3. This micrograph reveals the organ morphology within *Taenia solium* tapeworm proglottids. (SOURCE: PHIL 5261 – CDC)

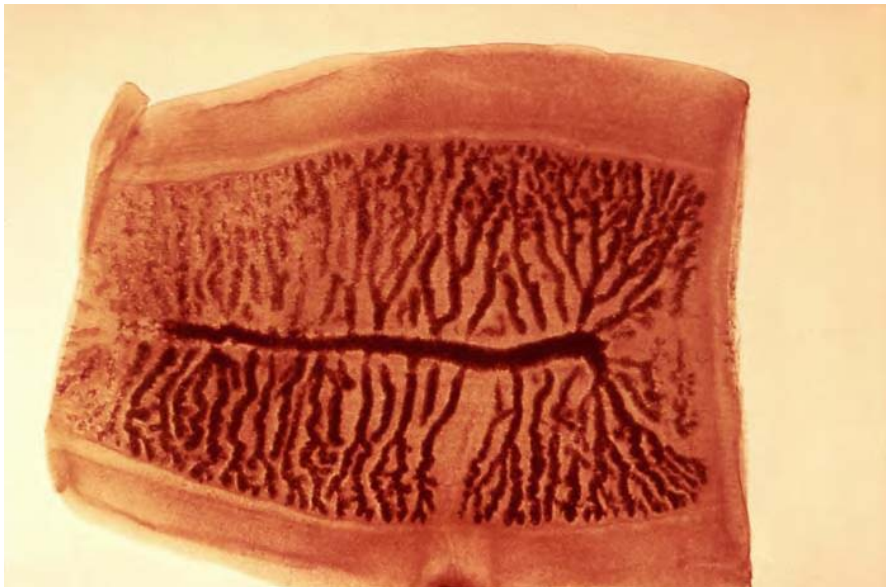


Image 4-4. This micrograph reveals the morphology of a gravid proglottid from the cestode *Taenia saginata*, a tapeworm. (SOURCE: PHIL 5259 – CDC)

If the scolex is recovered, the four suckers and rostellum of hooklets of *T. solium* will distinguish it from *T. saginata*, which has four suckers but no hooklets.

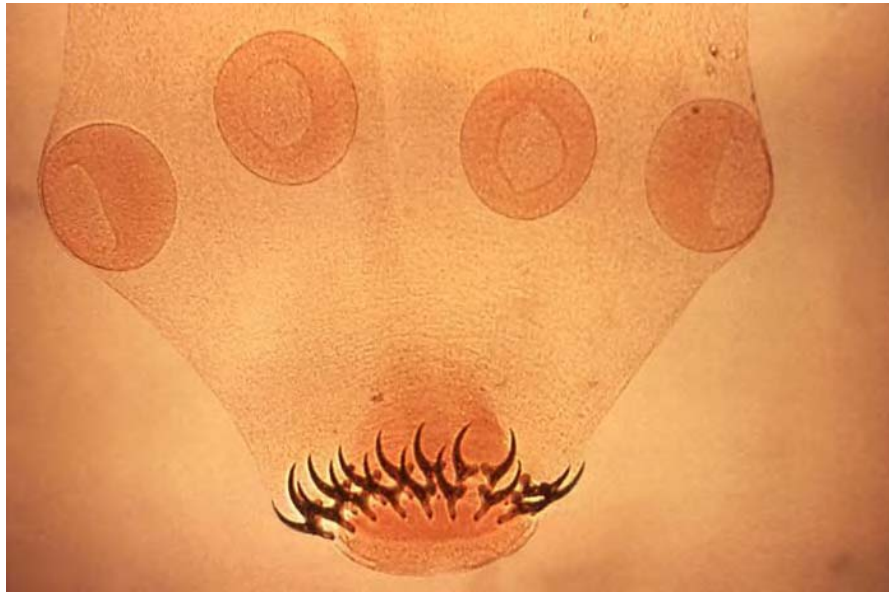

Image 4-5. This is an adult *Taenia solium* tapeworm scolex. (SOURCE: PHIL 5262 – CDC)

Clinical Disease

The presence of the adult worm rarely causes symptoms apart from slight abdominal irritation with diarrhea, constipation or indigestion. The accidental ingestion of the embryonated ova of *T. solium* may result in cysticercosis in man. An infection due to an adult *Taenia*, in man or animals, is referred to as *taeniasis*. *T. saginata* (the beef tapeworm) **does not** cause human cysticercosis.

When the embryonated eggs are ingested, the embryos hatch out, migrate through the intestinal wall and are carried around the body in the circulation and deposited in various tissues. Muscle and subcutaneous tissues are usually infected, but cysticerci can infect most organs and tissues. Human cysticercosis is usually asymptomatic unless the infection is particularly heavy or cysticerci are formed in some vital area e.g. the brain, resulting in neurological sequelae.

Table 4-2. Some characteristics differentiating *T. saginata* from *T. solium*.

Characteristic	<i>Taenia saginata</i>	<i>Taenia solium</i>
Intermediate Host	Cattle, reindeer	Pig, wild boar
Site of Development	Muscle, viscera	Brain, skin, muscle
Scolex: adult worm	No hooks	Hooks
Scolex: cysticercus	No rostellum	Rostellum & hooks
Proglottids: uterine branches	23 (14 – 32) *	8 (7 –11) *
Passing of proglottids	Single, spontaneous	In groups, passively
Ovary	Two lobes	Three lobes
Vagina: sphincter muscle	Present	Absent

* No universal agreement to the number of uterine branches in these two species. As a rough guide, specimens with more than 16 branches are likely to be those of *T. saginata* and those with less than ten branches are likely to be of *T. solium*. (SOURCE: CDC)

Laboratory Diagnosis

Diagnosis of intestinal taeniasis can be made by recovery of the characteristic ova in the stool. However, the ova of *T. solium* and *T. saginata* are identical and diagnosis is made by the recovery of the segments or scolex.

The diagnosis of cysticercosis depends upon serology. MRI scans may reveal the presence of lesions in the brain. Calcified cysticerci are less often seen in the brain: in about one-third of cases, 10 years or more after infection. Occasionally, the diagnosis is made histologically on surgical specimens. Calcification in muscles usually appears three to five years after initial infection, and are most typically seen as spindle-shaped calcifications, most numerous in the thighs.

Western Blots

Various Immunodiagnostic tests appear to give good results on serum or CSF.

Diagnosis using an immunodiagnostic test can be achieved using an *in vitro* qualitative assay for the detection of IgG antibodies in serum reactive with *T. solium* antigens present on a membrane.

Infected individuals develop a predominately IgG response to the parasite. ELISA has been used as a screening test, but low sensitivity and frequent artifactual cross reactions, or cross reactions with antibodies from other parasitic infections, limit its usefulness as a confirmatory diagnostic test. The Western Blot assay (US Patent No. 5,354,660) developed by Tsang *et al*, at the U.S. Centers for Disease Control has been shown to provide a reliable method for evaluation of sera from patients with clinically diagnosed active cysticercosis. Field studies support a sensitivity of 98% and specificity of 100% for this assay.

This assay is known as the QualiCode™ Cysticercosis Kit, the principle behind the test is that it is a qualitative membrane-based immunoassay manufactured from *T. solium* proteins. The *T. solium* proteins are fractionated according to molecular weight by electrophoresis on a polyacrylamide slab gel (PAGE) in the presence of sodium dodecyl sulfate (SDS). The separated *T. solium* proteins are then transferred via electrophoretic blotting from the gel to a nitrocellulose membrane. This antigen-bearing membrane has been cut into strips for testing of individual samples. Sera are tested at 100X dilution.

During the procedure, the strips containing the *T. solium* proteins are incubated with serum specimens and washed to remove unbound antibodies. Visualization of human immunoglobulins specifically bound to *T. solium* proteins is performed by sequential reaction with goat anti-human immunoglobulin-alkaline phosphatase conjugate and BCIP/NBT substrate. Bands corresponding to the positions of the resolved *T. solium* proteins will be visualized on the strip, indicating the presence in the serum sample of IgG antibodies direct against *Taenia* antigens. Band positions are compared to those on a reference strip developed using the cysticercosis positive control.

Hymenolepis nana

Introduction

Hymenolepis nana, the dwarf tapeworm, is the smallest tapeworm to infect humans. This cestode belongs to a large family known as Hymenolepididae. The diagnostic features of this family are: scolex armed with one cirlet of five hooks; one to three large testes and sacciform uterus. In addition to the *H. nana*, three other species, *H. diminuta*, *H. microstoma* and *H. citelli* have been used extensively for studies on cestodes.

Hymenolepis nana has a cosmopolitan distribution and is thought to be the most common tapeworm throughout the world. The infection is more frequently seen in children although adults are also infected, causing *hymenolepiasis*.

Life Cycle

The lifecycle of *H. nana* does not require an intermediate host, complete development occurring within the villi of a single host, resulting in a 'direct' life cycle. It can also utilize an insect as an intermediate host.

Hymenolepiasis

(*Hymenolepis nana*)

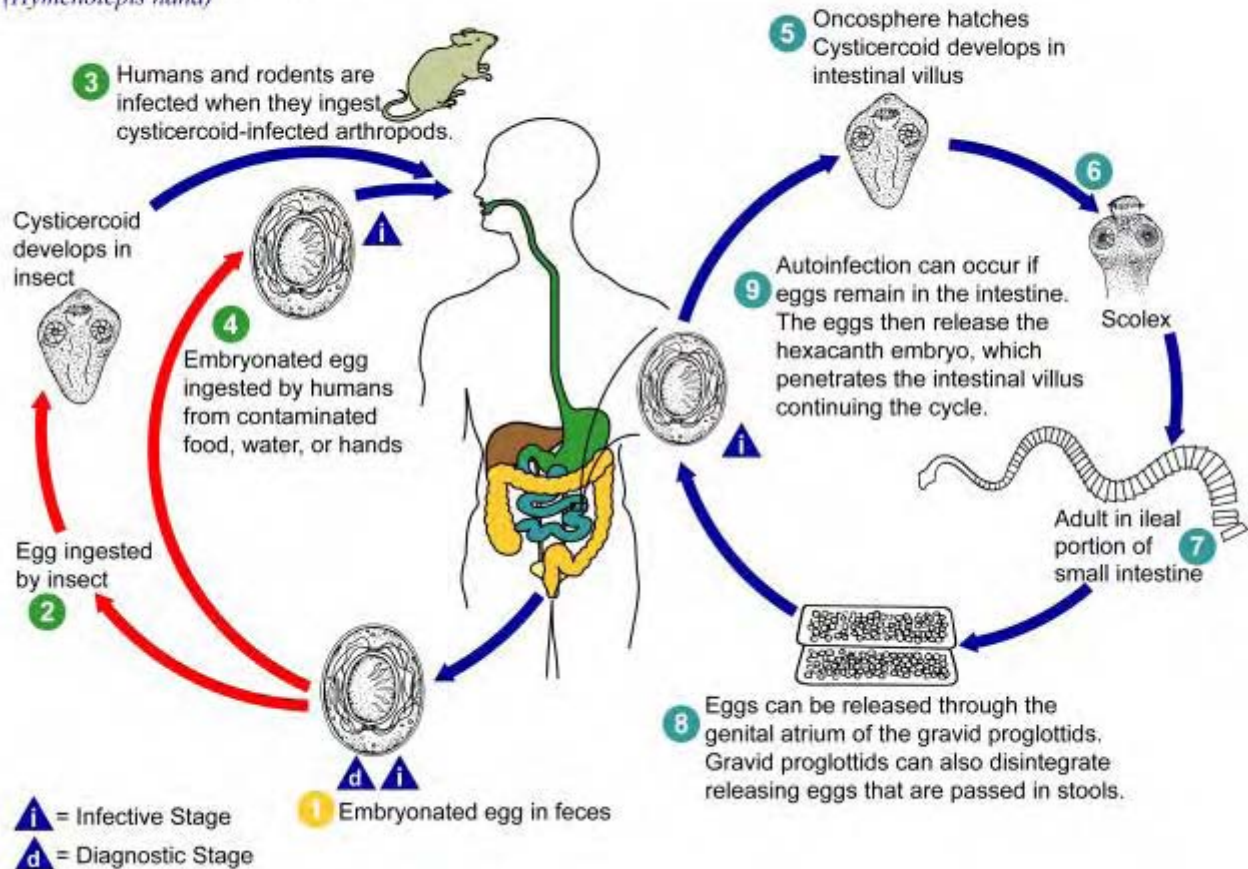


Illustration 4-2. This is an illustration of the life cycle of *Hymenolepis nana*, the causal agent of Hymenolepiasis. (SOURCE: PHIL 3396 - CDC/Alexander J. da Silva, PhD/Melanie Moser)

The eggs that are released from mature proglottids in the upper ileum are usually passed out in the feces. If swallowed by another human they develop into hexacanth oncospheres and burrow into the villi of the small intestine. This is where they develop into tailless cysticercoids and then migrate towards the ileum and attach to commence the formation of proglottids. The eggs which are ingested by insects, such as fleas, beetles or cockroaches hatch to form tailed cysticercoids which remain unmodified as long as they are inside the insect. If they are accidentally swallowed by a human they pass down to the ileum and establish themselves.

Morphology

The egg containing the oncosphere bears three pairs of hooklets and is surrounded by a membrane. This membrane has two polar thickenings from which arise threadlike filaments extending into the space between the membrane and the colorless hyaline shell, unlike those of *H. diminuta* which do not possess any filaments.

The adult tapeworm is normally 2.5-4cm long. The scolex is knob like in shape, has a rostellum with hooklets and four suckers. The segments are wider than they are long. Ova are spherical or ovoid measuring 30-47 μ m in diameter. This is what distinguishes it morphologically from *H. diminuta*.

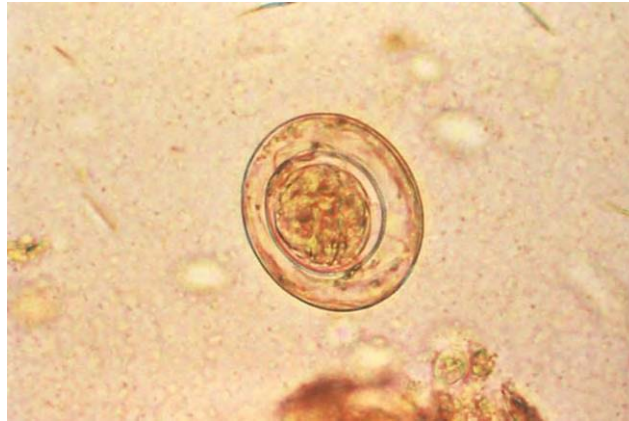


Image 4-6. This micrograph depicts an egg of the dwarf tapeworm *Hymenolepis nana*. On the inner of the two membranes surrounding the *Hymenolepis nana* egg are two poles, from which 4 to 8 polar filaments spread out between the two membranes. The oncosphere, or larval stage, has six hooks. (SOURCE: PHIL 5265 – CDC)

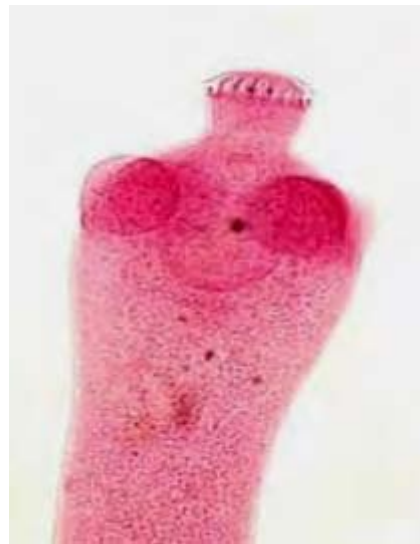

Image 4-7. *Hymenolepis nana* scolex. Stained to show the scolex with a knob like rostellum bearing a ring of hooklets. They possess four suckers, two of which can be seen just below the protruding rostellum. (SOURCE: D. Scott Smith, M.D./CDC)

Clinical Disease

Infections due to *H. nana* may cause no symptoms even with heavy worm burdens. However, symptoms of restlessness, irritability, anorexia, abdominal pain and diarrhea have been reported. Heavy worm burdens may be caused by auto-infection which can be a problem in the immunocompromised.

Laboratory Diagnosis

Diagnosis is based on recovery and identification of the characteristic ova in a formol-ether concentrate of feces. Adult worms and proglottids are rarely seen in stool samples.

Hymenolepis diminuta

Introduction

Hymenolepis diminuta is a small tapeworm commonly found in rats and mice. It has a world wide distribution in these hosts but is infrequently found in humans, with only sporadic cases being reported.

Life cycle and Transmission

The life cycle of *H. diminuta* requires an intermediate arthropod host e.g. earwigs, larval fleas and various beetles. Human infection occurs by the accidental ingestion of an infected arthropod, which contains the cysticercoids.

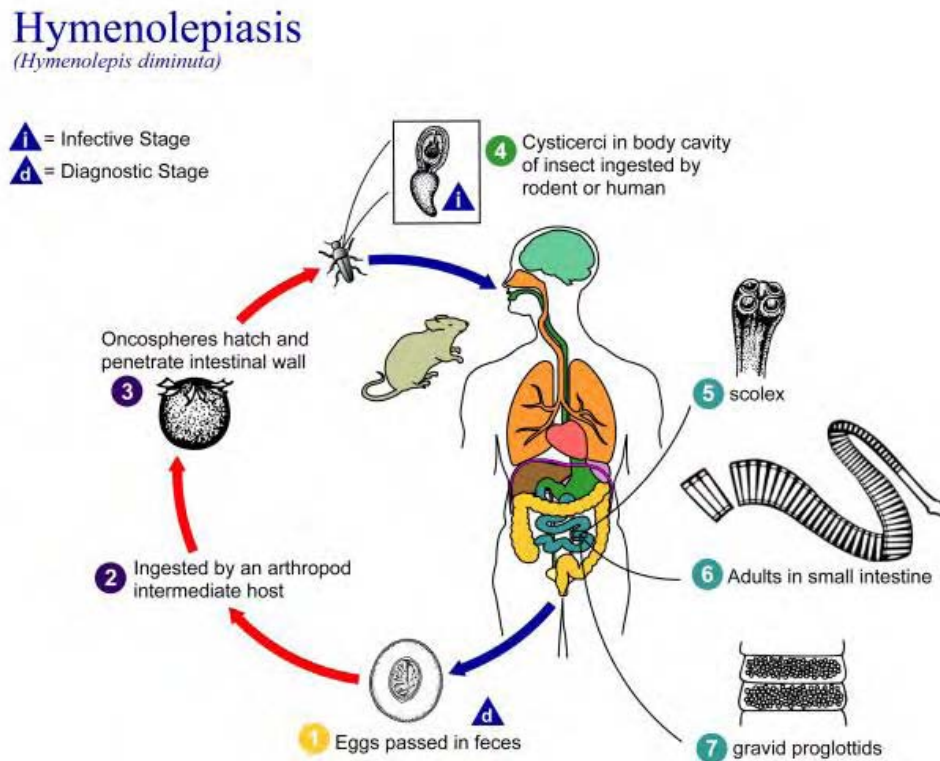


Illustration 4-3. This is an illustration of the life cycle of *Hymenolepis diminuta*, the causal agent of Hymenolepiasis. (SOURCE: PHIL 3395 - CDC /Alexander J. da Silva, PhD/Melanie Moser)

Morphology

The ova are large, ovoid and yellowish with a moderately thick shell. They contain an oncosphere with six hooklets and a clear area between the oncosphere and the shell. They measure 70-85 μ m by 60-80 μ m.

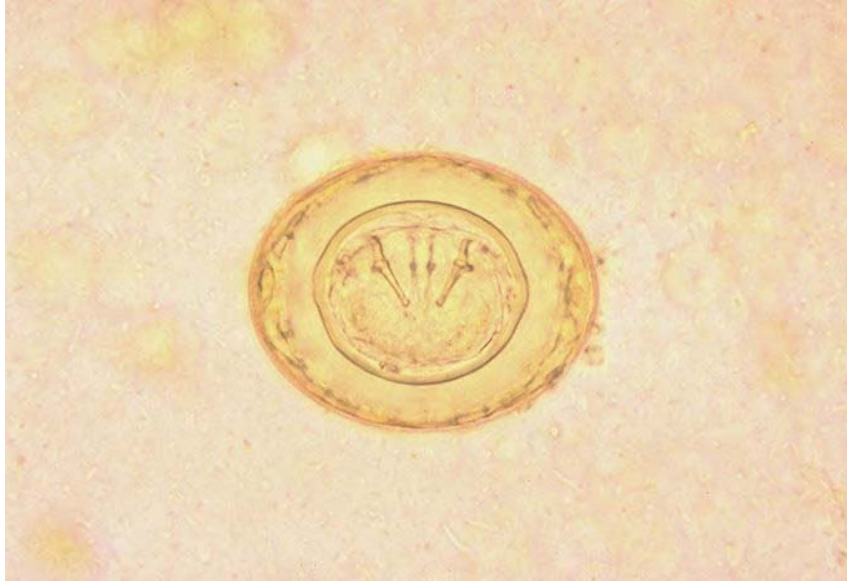

Image 4-8. *Hymenolepis diminuta* egg. (SOURCE: PHIL 658 - CDC/Dr. Mae Melvin)

The adult worm is 20–60cm long. It has a knob like scolex with a rostellum but no hooklets and four suckers (in contrast to *H. nana*). The rostellum can be withdrawn into a rostellar sac. The tapeworm contains about 1000 proglottids, each of which is wider than long.

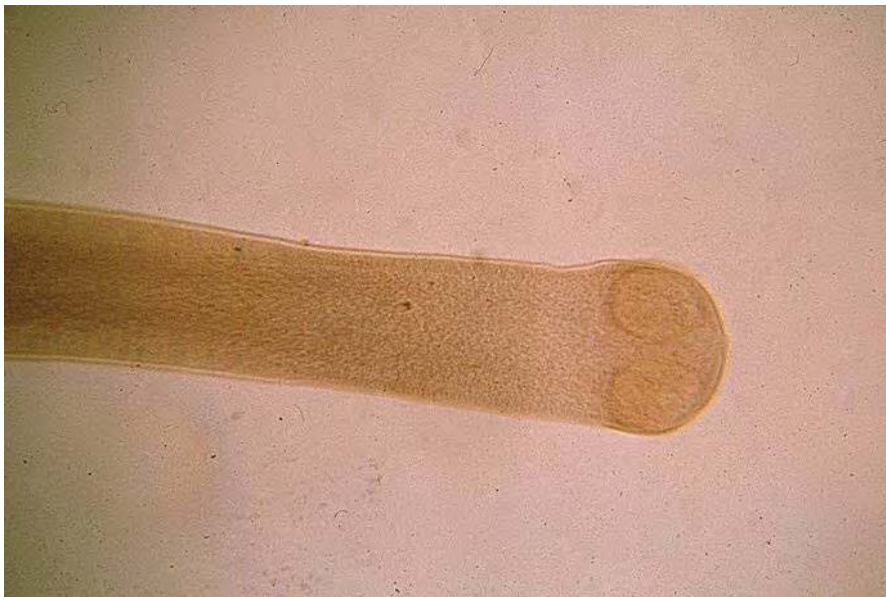


Image 4-9. *Hymenolepis diminuta* scolex. (SOURCE: PHIL 370 – CDC)

Clinical Disease

The symptoms associated with *H. diminuta* infections are few if any.

Laboratory Diagnosis

Diagnosis is based on recovery and identification of the characteristic ova in a formol-ether concentrate of feces. Adult worms and proglottids are rarely seen in stool samples.

Diphyllobothrium latum

Introduction

Members of this order, commonly known as pseudophyllids, are chiefly parasites of fish-eating mammals, birds and fish. They typically are found with a scolex which is characterized by two shallow elongated bothria situated with one dorsally and one ventrally. The proglottids are flattened dorsoventrally.

Diphyllobothrium latum is an intestinal tapeworm, known as the human 'broad' tapeworm. It is the largest tapeworm found in man. The term 'broad' relates to the fact that the proglottids are generally wider than they are long. It is an important human parasite. The adult worms of two other species of the genus, *D. dendriticum* and *D. ditremum* are chiefly parasite of fish-eating birds and mammals.

The tapeworm, *D. latum* has a wide distribution, occurring especially in countries bordering the Baltic Sea (Finland, Sweden etc.): and also in Russia, Switzerland and North America. It is in these countries where the populations are known to eat uncooked or partly cooked (i.e. smoked) fish.

Apart from man they are found in many other hosts, especially the dog, cat and pig. This is due to the host countries allowing the domestic animals access to the offal from the infected fish.

Life Cycle and Transmission

The life cycle of this tapeworm requires two intermediate hosts.

The eggs are passed out in human feces, once in water they hatch out into small ciliates coracidium larvaem which swim until ingested by Copepods. It is in these intermediate hosts that growth and development of the 1st larval stage are completed (They are now known as procercoids). When these crustaceans (fresh water) are eaten by fish, the procercoid larvae continue to develop in the flesh of the fish and become known as plerocercoid larvae. It is this stage of the larvae which develops in man when they eat undercooked fish and they grow into adult worms in the small intestine.

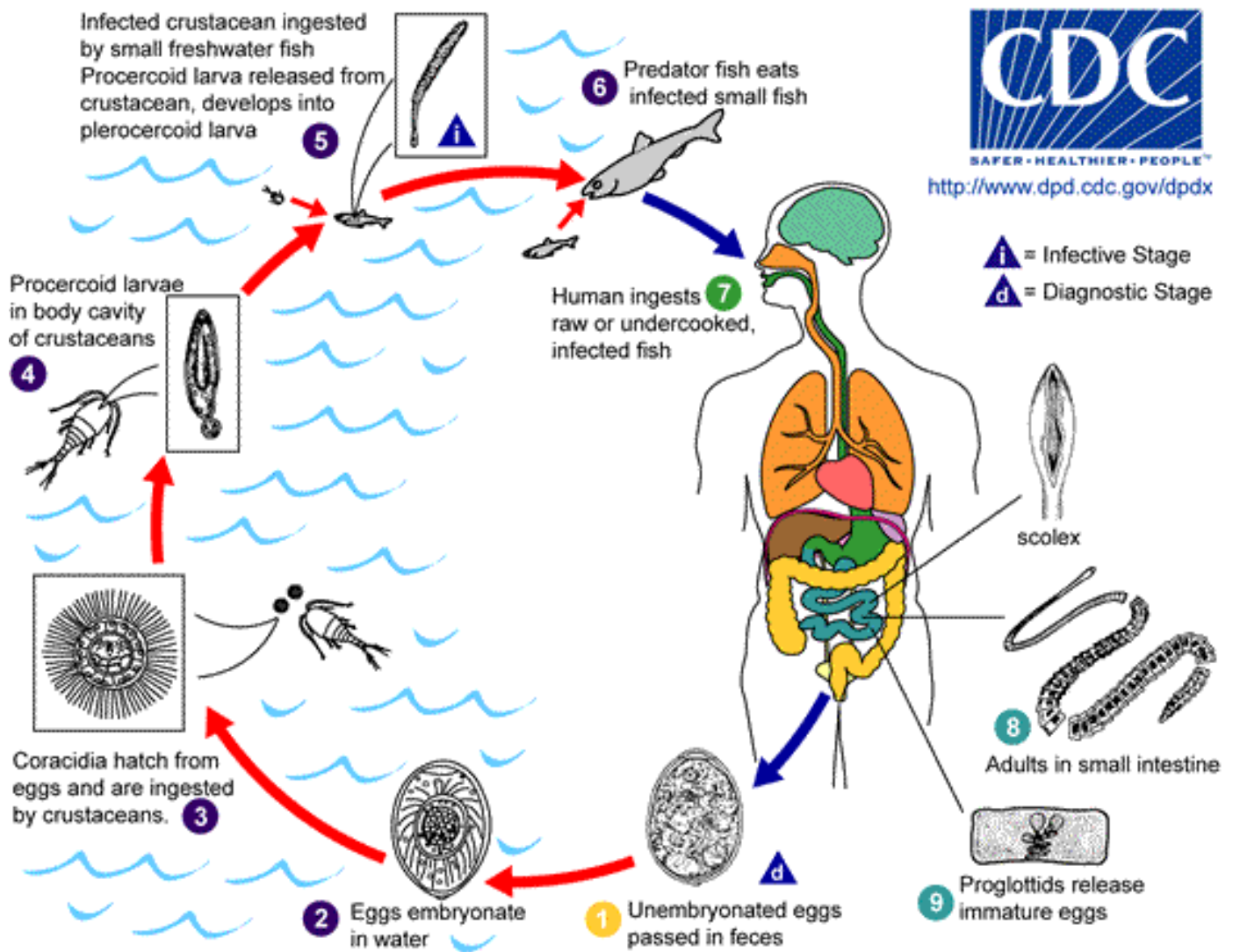


Illustration 4-4. Immature eggs are passed in feces **1**. Under appropriate conditions, the eggs mature (approx. 18 to 20 days) **2** and yield oncospheres which develop into a coracidia **3**. After ingestion by a suitable freshwater crustacean (the copepod first intermediate host) the coracidia develop into proceroid larvae **4**. Following ingestion of the copepod by a suitable second intermediate host, typically minnows and other small freshwater fish, the proceroid larvae are released from the crustacean and migrate into the fish flesh where they develop into a plerocercoid larvae (sparganum) **5**. The plerocercoid larvae are the infective stage for humans. Because humans do not generally eat undercooked minnows and similar small freshwater fish, these do not represent an important source of infection. Nevertheless, these small second intermediate hosts can be eaten by larger predator species, e.g., trout, perch, walleyed pike **6**. In this case, the sparganum can migrate to the musculature of the larger predator fish and humans can acquire the disease by eating these later intermediate infected host fish raw or undercooked **7**. After ingestion of the infected fish, the plerocercoid develop into immature adults and then into mature adult tapeworms which will reside in the small intestine. The adults of *D. latum* attach to the intestinal mucosa by means of the two bilateral grooves (bothria) of their scolex **8**. The adults can reach more than 10 m in length, with more than 3,000 proglottids. Immature eggs are discharged from the proglottids (up to 1,000,000 eggs per day per worm) **9** and are passed in the feces **1**. Eggs appear in the feces 5 to 6 weeks after infection. In addition to humans, many other mammals can also serve as definitive hosts for *D. latum*. (SOURCE: CDC)

Morphology

The egg is usually ovoid and has a small knob at the opercular end and is yellowish-brown in color with a smooth shell, of moderate thickness. They measure 58-75µm by 40-50µm in size.

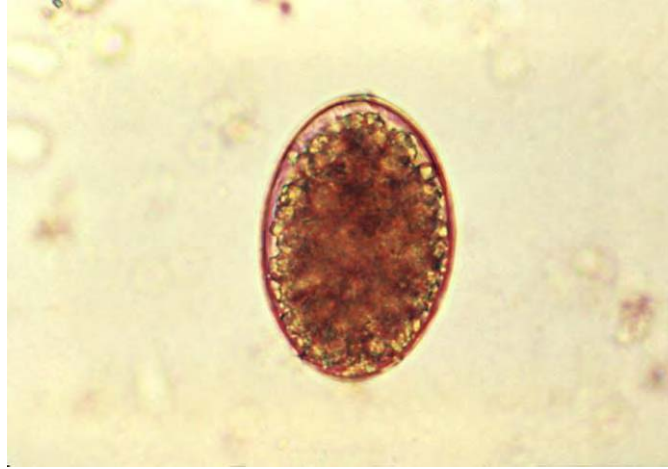

Image 4-10. This micrograph reveals an egg of tapeworm cestode parasite *Diphyllbothrium latum*. *Diphyllbothrium sp.* unembryonated eggs passed in the stool, are oval or ellipsoidal with an operculum at one end that can be inconspicuous. At the opposite (abopercular) end is a small knob that can be barely discernible. (SOURCE: PHIL 5258 – CDC)

Adult worms can reach up to a length of 10 meters or more and may contain up to 3,000 proglottids. The scolex is spatulate with no rostellum or hooklets. It has two shallow grooves or bothria, which are unlike the typical four suckers seen on the *Taenia* species. The proglottids measure 3µm long and 11µm wide and have a rosette shaped central uterus.

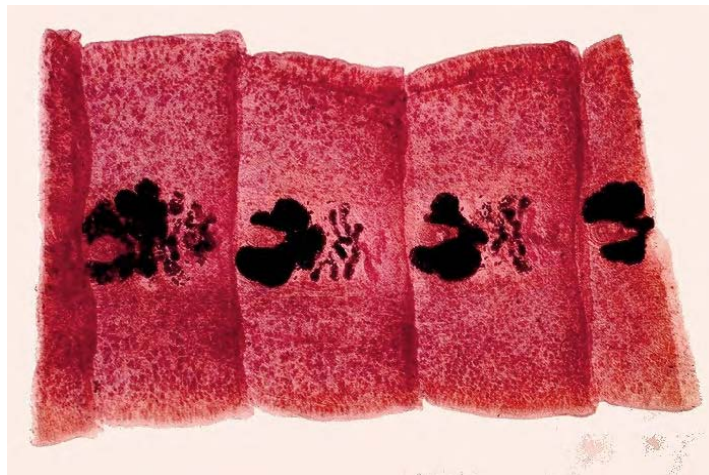


Image 4-11. Gravid proglottids of *Diphyllbothrium latum*. (SOURCE: PHIL 1516 - CDC /Dr. Mae Melvin)

Clinical Disease

The infection caused by *D. latum* is due to the ingestion of raw, poorly cooked or pickled fresh water fish. The symptoms associated with *D. latum* infection may be absent or minimal with eosinophilia. There may be occasional intestinal obstruction, diarrhea, and abdominal pain. The most serious symptom is the onset of pernicious anemia. This is due to a vitamin B₁₂ deficiency, caused by excessive absorption of the vitamin by the adult worm and the absorption of cobalamins from the host intestine (occurring only in a small percentage of people).

Laboratory Diagnosis

Laboratory diagnosis depends on the recovery of characteristic eggs from a formol ether concentrate of feces. Proglottids may also be seen in fecal samples usually in a chain of segments from a few centimeters to about half of a meter in length.

4.3 Identifying Intestinal Helminths

The usual diagnostic stages for identifying medically important helminths are the eggs and larvae. Occasionally, adult worms like *Ascaris* and *Enterobius* may be seen and segments or proglottids are used for diagnosing certain tapeworms.

If an egg, is found with the following features as described below, it should be carefully observed in order to make a specific identification.

1. Size: The length and width are measured and are generally within a specific range.
2. Shape: Each species has its own particular shape.
3. Stage of development when passed: In some species, the eggs consist of a single cell; in some, there may be several cells; and some species are usually embryonated (i.e., they contain a larva) when passed in the feces. Occasionally, if the stool specimens are several hours or 1–2 days old, eggs may develop to more advanced stages. *Ascaris* eggs usually have only one cell when passed in the feces; however, the single cell may divide and, in old specimens, eggs with two or four cells may be seen. Hookworm eggs in specimens that are several hours old may contain 16, 32 or more cells. In 12–24 hours, the egg may be embryonated and later still the larvae may hatch. Therefore, when observing the stage of development of helminth eggs, be sure that the stool specimen is freshly passed. If it is several hours or a day old, expect to see changes in the stage of development of some species. Ideally only fresh samples should be accepted for diagnosis.
4. Thickness of the egg shell: Some species, like *Ascaris*, have thick shells; others, like hookworm, have thin shells.

5. Color: Some eggs are colorless (e.g., hookworm, *Enterobius*), others are yellow or brown (*Ascaris*, *Trichuris*).
6. Presence of characteristic like opercula (lids), spines, plugs, hooklets, or mammillated outer coats.

Chapter 5.

The Nematodes

5.1 Infections Acquired Through the Gastrointestinal Tract

Nematodes (or round worms) are non-segmented helminths known as make up a large assemblage of relatively simple structured organisms. They possess bilateral symmetry and a complete digestive tract with oral and anal openings; they taper to a relative point at both ends. They are also found to have separate sexes, with the male being smaller than the female, ranging in size from a few millimeters to over a meter in length. Their cylindrical non-segmented bodies allow them to be easily distinguishable from other helminths.

Nematode infections have a widespread distribution being found in both Temperate and Tropical climates. They can be found in fresh water, in the sea and the soil, successfully invading both animals and plants. The nematodes found in man invade the body fluids such as the blood or lymph channels and also the intestine. The ones that successfully invade the intestine are generally larger but, the nematodes which invade the tissues can grow to relatively enormous lengths.

Once hatched in the intestine they undergo an incredible migration. The larvae initially burrow into the mucosa, penetrate blood vessels and appear as second stage larvae in the liver within six hours post-infection. Here they remain for several days and develop into third stage larvae, L₃. These larvae then migrate to the heart and are carried to the lungs via the pulmonary arteries, arriving within four to seven days. From there they break out of the capillaries into the alveoli and finally work their way up the trachea to the pharynx and reach the small intestine on the 8th or 10th day post-infection.

Within the intestine, the larvae begin their third molt and become fourth stage larvae by the tenth day. The pre-patent period of *A. suum* in pigs (40–53 days) is less than that of *A. lumbricoides* (54–61 days) in humans. Two to three months after ingestion of the eggs, the females lay eggs in the intestine.

The fertilized female can lay about 200,000 eggs per day. Eggs require oxygen and moisture to embryonate and the worm is often found associated with *Trichuris trichiura* (see the *Trichuris trichiura* section).

Species	Size	Shape	Color	Stage of Development When Passed	Specific Features And Variations
Nematodes					
<i>Enterobius vermicularis</i>	55 µm x 26 µm Range, 50-60 µm 20-32 µm.	Elongated, asymmetrical with one side flattened, other side convex.	Colorless.	Embryonated. Contains C shaped or tadpole-like embryo.	Smooth, thin eggshell with one flattened side. Occasionally may contain a fully developed larva. (More readily found on anal swabs than in feces).
<i>Ascaris lumbricoides</i>					
fertile egg	60 µm x 45 µm. Range, 45-70 µm x 35-45 µm.	Round or ovoidal. with thick shell.	Brown or yellow brown.	1 cell, separated from the shell at both ends.	Mammillated albuminous coat or covering on outer shell. Coat is sometimes lost and decorticated eggs have a colorless shell with gray or black internal material. Eggs may be in 2, 4, or more cells, or contain a fully developed larva.
infertile egg	90 µm x 40 µm. Range, 85-95 µm x 35-45 µm.	Elongated, occasionally triangular, kidney shaped or other bizarre forms. Shell often very thin.	Brown.	Internal material is a mass of irregular globules and granules that fills shell.	Mammillated covering attenuated or missing in many cases.
<i>Trichuris trichiura</i>	54 µm x 22 µm. Range, 49-65 µm x 20-29 µm.	Elongated, barrel-shaped with a polar "plug" at each end.	Yellow to brown. "Plugs" are colorless.	1 cell or unsegmented.	Polar plugs are distinctive. Eggs occasionally are oriented in a vertical or slanted position and may not be readily recognized. A gentle tap on the coverslip will usually reorient the egg. On rare occasions, atypical eggs lacking polar plugs may be seen.
Hookworm					
<i>Ancylostoma duodenale</i>	60 µm x 40 µm. Range, 57-76 µm x 35-47 µm.	Oval or ellipsoidal with a thin shell.	Colorless with grayish cells.	4- to 8-cell stage.	Occasionally, eggs in advanced cleavage (16 or more cells) or even embryonated may be seen. Rhabditiform larvae may be present if the specimens are old. Species identification can not be made on eggs alone; therefore, eggs should be reported simply as hookworm.
<i>Necator americanus</i>	65 µm x 40 µm. Range, 57-76 µm x 35-47 µm.				
<i>Trichostrongylus</i> species	90 µm x 40 µm. Range, 75-95 µm x 40-50 µm.	Elongated with one or both ends more pointed than hookworm.	Colorless with grayish cells.	May be in advanced cleavage or morula stage.	Egg resembles hookworm egg but is larger and more pointed at the ends.

Table 5-1. Differential Morphology of the Diagnostic Stages of Helminths Found in Humans: Eggs (Nematodes) (SOURCE: CDC)

Ascaris lumbricoides

Morphology

Ascaris lumbricoides is the largest of the intestinal nematodes found in man. The male measures 15cm with a diameter of 3-4 μ m and has a curled tail with protruding spicules. The female is 20-35cm long with a diameter of 5 μ m with a straight pointed posterior end. The mouth has one dorsal and two ventral lips. Both are creamy white and the cuticle has fine circular striations.

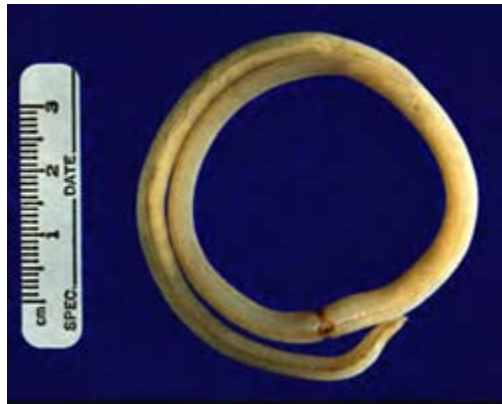

Image 5-1. Adult worm of *Ascaris lumbricoides*. They appear creamy white with fine circular striations, for diagnosis they require to be distinguished from earthworms. Females measure approximately 20-35cm long (SOURCE: CDC)

The ova can be unfertilized, fertilized or decorticated and can show considerable variation in shape and size. They measure 85-95 μ m by 43-47 μ m. The fertilized ova are easily recognized, oval in shape with a thick wall showing an irregular bumpy surface. They measure 45-75 μ m by 35-50 μ m. The outer covering has an albuminoid coat, stained golden brown by bile. The outer wall lies directly on top of a thick smooth shell, which is not easily distinguishable. Some have lost their albuminoid wall. The unfertilized ova are longer and narrower than the fertile ova, measuring 75-85 μ m by 35-50 μ m.

The shell layers of the egg provide a very resistant structure which can withstand many chemicals which make them ideal parasites of the intestine.

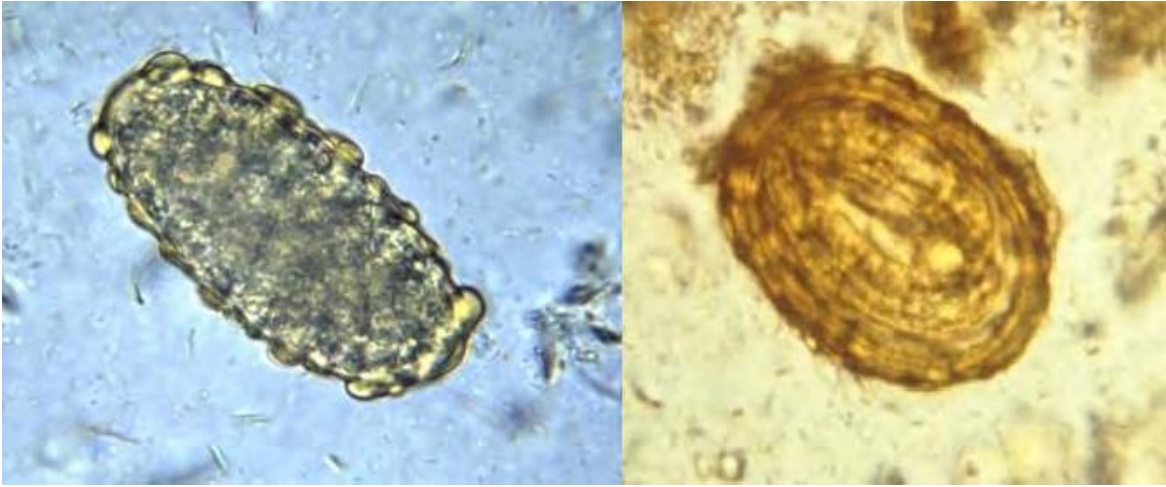


Image 5-2. Unfertilized (left) and fertilized (right) *Ascaris lumbricoides* eggs. The unfertilized eggs are longer and narrower than fertilized eggs, measuring 75-85 μ m by 35-50 μ m wide. The fertilized eggs have a thick and bumpy outer wall which is stained golden brown with bile. (Saline wet prep) (SOURCE: PHIL 411/4821 - CDC/Dr. Mae Melvin)

Clinical Disease

Small burdens of worms in the intestine may cause no symptoms. The patient may have symptoms of pneumonitis with cough and low grade fever during the migration of the larvae through the liver and lungs. This can be accompanied by wheezing, coughing and eosinophilia. In heavy worm burdens the adult worms actively migrate in the intestine resulting in intestinal blockage, vomiting and abdominal pain but infections may also be asymptomatic. The worms can penetrate through the wall of the intestine, or into the appendix, travel up the common bile duct, which may become blocked or they may then enter the gal bladder or liver. A heavy worm burden in children may lead to severe nutritional impairment and retardation in growth.

Laboratory Diagnosis

The adults of *A. lumbricoides* may be expelled through the anus, mouth or nose. It is important to distinguish the adult worms from earthworms which are segmented and are often collected as a contaminant from toilets.

The microscopic examination of stool deposits after concentration reveals the characteristic bile stained ova. Eggs may be difficult to identify if an excess of iodine is added to the wet preparation as they retain the stain thus resembling debris. Ova may also become decorticated. In most symptomatic cases identification is easy due to the vast number of eggs, which can be found within a few seconds of starting to scan the slide.

Hookworm Species

Introduction

Hookworms infective to man comprise of two species, *Necator americanus* and *Ancylostoma duodenale*. They are classed as one of the most destructive of human parasitic helminths. There is no intermediate host, with man being the only definitive host.

It is estimated that there are some 900 million cases of infection world wide (Crompton, 1989). The infection is serious where the worms insidiously undermine the health of their hosts.

They occur in areas where sanitary and environmental conditions favor the development of the eggs and larval infections (e.g., warm, damp soil).

The geographic distributions of the two species are remarkably divided into:

Necator americanus which predominately is a New World hookworm, where it was introduced from Africa to the Western Hemisphere. It can also be found in the Far East, Asia, Africa, South America, and Oceania.

Ancylostoma duodenale is an Old World hookworm; it is the only species of Europe and areas bordering the Mediterranean. It can also be found in the Middle East, North China, Africa, Asia, and South America.

Life Cycle

The adult worms live in the small intestine, attached firmly to the mucous membrane of the gut lining, and feed on blood and tissue. The adult females deposit their eggs whilst in the gut (they can produce up to 20,000 eggs per day), the eggs are then passed out in the feces. The rhabditiform larvae hatch in warm, damp soil (light sandy loam), feeding on bacteria. After about one week during which they have gone through two molts become infective and climb into a suitable position waiting for a suitable host to pass by. The larvae enter the host by penetrating unbroken skin (it is now recognized that *A. duodenale* can successfully enter man by oral ingestion, this may be more important for this species than skin penetration). The larvae then enter blood vessels and are carried to the heart, lungs and trachea. They are then swallowed and develop into adult worms in the small intestine. Larvae that are initially swallowed may not show this migration.

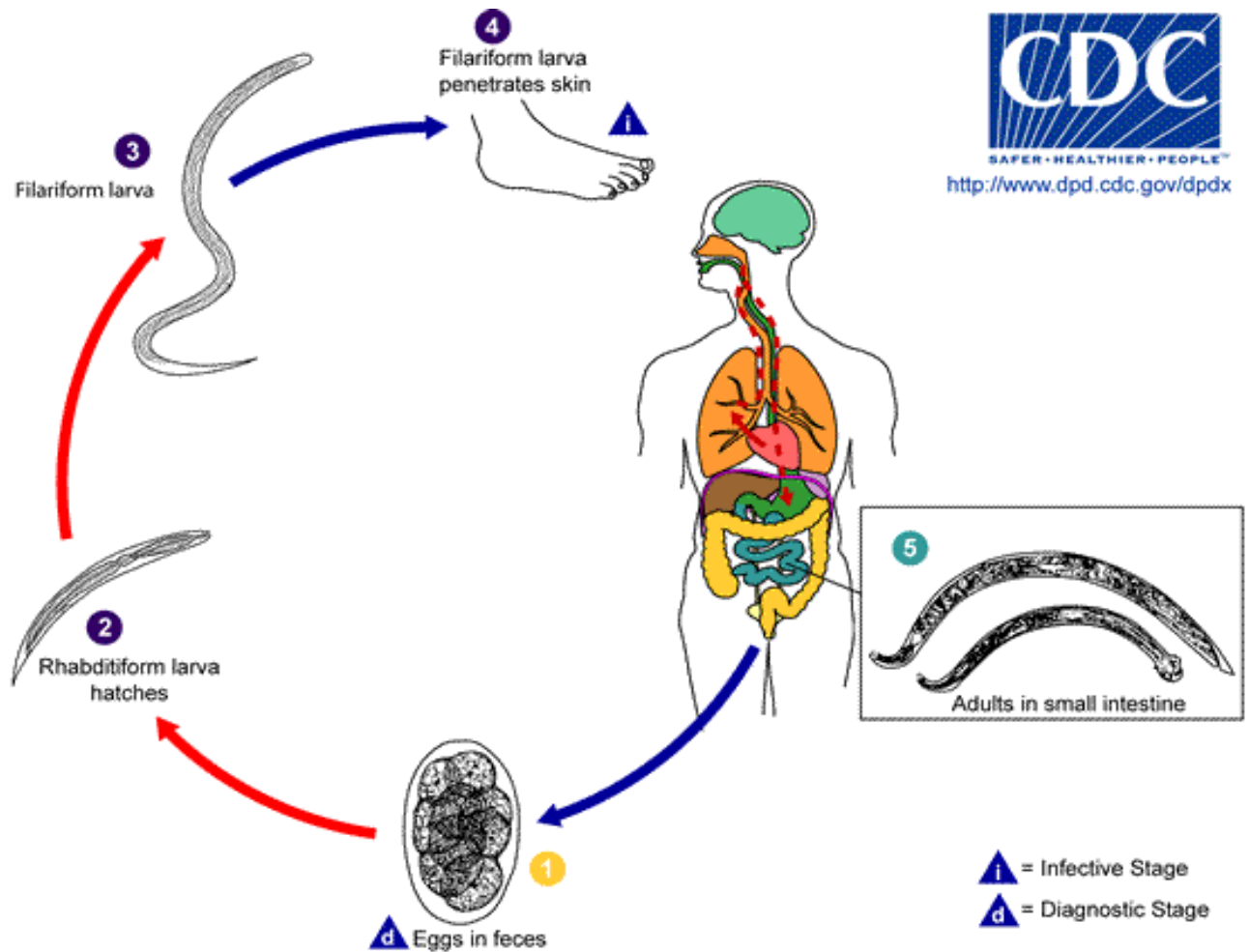


Illustration 5-1. Eggs are passed in the stool **1**, and under favorable conditions (moisture, warmth, shade), larvae hatch in 1 to 2 days. The released rhabditiform larvae grow in the feces and/or the soil **2**, and after 5 to 10 days (and two molts) they become become filariform (third-stage) larvae that are infective **3**. These infective larvae can survive 3 to 4 weeks in favorable environmental conditions. On contact with the human host, the larvae penetrate the skin and are carried through the veins to the heart and then to the lungs. They penetrate into the pulmonary alveoli, ascend the bronchial tree to the pharynx, and are swallowed **4**. The larvae reach the small intestine, where they reside and mature into adults. Adult worms live in the lumen of the small intestine, where they attach to the intestinal wall with resultant blood loss by the host **5**. Most adult worms are eliminated in 1 to 2 years, but longevity records can reach several years. Some *A. duodenale* larvae, following penetration of the host skin, can become dormant (in the intestine or muscle). In addition, infection by *A. duodenale* may probably also occur by the oral and transmammmary route. *N. americanus*, however, requires a transpulmonary migration phase. (SOURCE: CDC)

Larvae live for an average of 3–6 weeks in the tropics (*A. duodenale* can live at lower temperatures than *N. americanus* can, and so is found in more temperate climates).

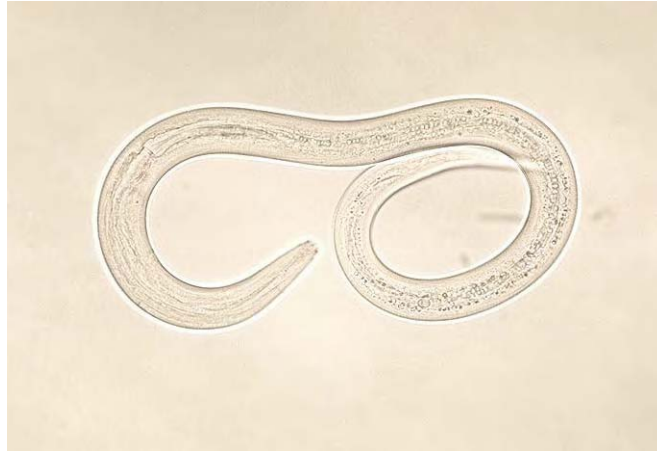


Image 5-3. Hookworm larva. Both *Ancylostoma duodenale* and *Necator americanus* larvae have similar general morphology and measuring approximately 10-13 μ m for females and 8-11 μ m for males. (SOURCE: PHIL 1513 – CDC/Dr. Mae Melvin)

Morphology

Both species have similar general morphology and measure approximately, females 10–13 μ m and males 8–11 μ m. The general morphology of the two species resemble those of *Nippostrongylus brasiliensis*, the rat hookworm, but they are approximately twice the size of the rat hookworm (*Nippostrongylus brasiliensis* a species not discussed here).

The male species has a posterior copulate bursa which is absent from the female. The females though possess a vulva opening which is found almost one third of the body length from the posterior end, they also have two ovaries. Most of the female body is occupied with eggs.

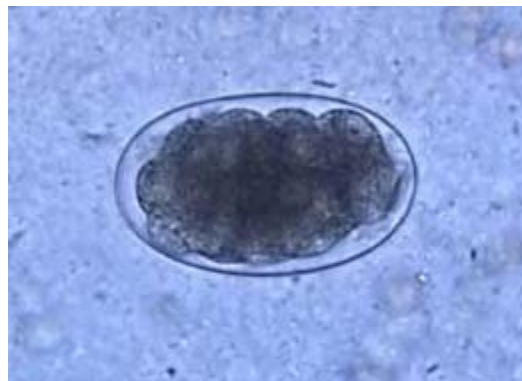

Image 5-4. Hookworm egg, normally passed in feces during the 4 - 8 cell stage. The ova of both species are similar with the shape being oval and transparent with a smooth thin shell and measuring 56-75 μ m by 36-40 μ m. (SOURCE: PHIL 5220 – CDC)

The mouth (or buccal cavity) of the two species show a conspicuous pair of chitinous plates on the dorsal surface. *Ancylostoma duodenale* buccal cavity bears two hook like teeth on the top and two triangular cutting plates on the bottom. While the mouth of *N. americanus* has four cutting plates, two on the ventral and two on the dorsal surfaces. The head is curved in both

species but *Necator* adults it is finer but more pronounced forming a definite “hook” at the anterior end. The buccal cavity is used to attach the worms securely to the mucosa of the small intestine. With the teeth and cutting plates used to pierce the mucosa.

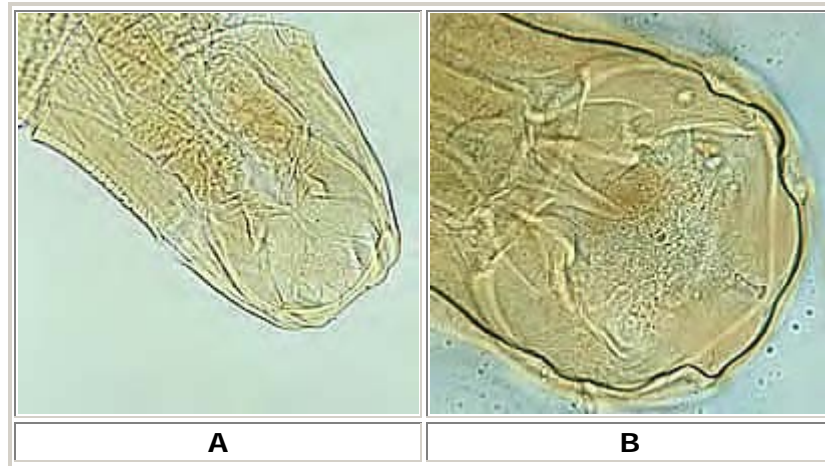


Illustration 5-2. A: Adult worm of *Ancylostoma duodenale*. Anterior end is depicted showing cutting teeth. **B:** Adult worm of *Necator americanus*. Anterior end showing mouth parts with cutting plates. (SOURCE: CDC)

The ova are oval and transparent with a smooth thin shell and measure 56-75µm by 36-40µm. They are usually passed in the 4-8 cell stage in feces and may be embryonated. The ova of both species of Hookworm are similar.

The bursa (the characteristic external feature which forms an umbrella-like extension surrounding the cloaca) of both male species is well developed, *Necator americanus* adults are distinguished from *Ancylostoma duodenale* by the split dorsal rays and the close arrangement of the lateral rays.

Simplistically the life cycle has three phases:

The parasitic adult females lay eggs while they are in the duodenum where they hatch producing rhabditiform (non-infective) larvae.

1. The larvae can have two fates in life, one where they are passed out in the feces to continue down the free-living path or they develop into infective filariform larvae whilst traveling down the small intestine.

2. The larvae which, develop in the environment can also undergo different development. Some larvae undergo direct development (homogonic) or indirect development (heterogonic).

The non-infective first stage (rhabditiform) larvae develop into free living adults in the soil within 2–5 days and produce infective third stage or filariform larvae which can penetrate exposed skin (heterogonic development). This phase is common in moist, warm tropical countries.

The non-infective rhabditiform larvae which are excreted in the feces develop into infective filariform larvae in the soil (homogonic development). These infective larvae penetrate exposed skin. There is no development of free living adult worms and this phase is common in temperate zones. The larvae never undergo sexual maturity.

Both types of larvae can become established in the host by penetrating the skin or by oral ingestion.

The larvae which infect the host by penetrating the skin undergo a migration through the dermal tissues and into the circulation to the heart and lungs, then up the bronchi and trachea, where they are eventually swallowed and pass down into the intestine. On reaching the mucosa of the duodenum the females develop and produce eggs. Adult males are unable to attach themselves to the mucosa, therefore, for any copulation to take place they must mate in the lumen of the intestine.

3. The non-infective rhabditiform larvae develop into infective filariform larvae while passing down the small intestine. Autoinfection occurs when the larvae reinfect the host by penetrating the intestinal mucosa or the perianal or perineal skin. The larvae migrate to the lungs via the circulatory system and then return to the intestine.

From initial infection to maturity usually takes less than four weeks.

Hyperinfection Syndrome

The autoinfective capability of larvae may be responsible for long term infections which persist for many years. The parasite and host reach an equilibrium state where neither host nor parasite suffers any adverse reactions. If this equilibrium is disturbed e.g. immunosuppression, the infection proliferates with immense numbers of larvae migrating to every tissue in the body, especially the lungs. This condition is referred to as disseminated strongyloidiasis. This results in tissue damage, pneumonitis, brain damage or respiratory failure.

Laboratory Diagnosis

Microscopy

Laboratory diagnosis depends on finding larvae in stool, sputum or duodenal aspirates.

Strongyloides larvae may be present in the stool in very small numbers and culture methods may be needed to encourage the rhabditiform larvae to develop into filariform larvae and migrate from the sample. The Enterotest or string test can be used to recover larvae from duodenal aspirates.

Larvae must be distinguished from hookworm larvae especially if it is an older sample. Rhabditiform larvae are most commonly seen.

A good concentration technique is essential to increase the chances of seeing larvae, though they are easily killed making diagnosis more difficult.

Serology

Serological tests are of value in the diagnosis of strongyloidiasis when larvae cannot be found. An enzyme linked immunosorbent assay (ELISA) using larva antigen, is usually employed.

Little can be used to distinguish between the two species, but using the curved shape of the head is a good indicator.

Clinical Disease

Larval penetration of the skin may lead to pruritis, often termed as 'ground itch' at the site of penetration. Respiratory symptoms may arise during the larval migration.

The adult worm in the intestine may cause intestinal necrosis and blood loss as a result of the attachment of the adult to the intestinal mucosa. Patients with acute infections may experience nausea, vomiting, abdominal pain, diarrhea and eosinophilia.

Chronic infections may lead to iron deficiency and anemia resulting from the excessive loss of iron. Heavy worm burden in children may have serious consequences including death.

Laboratory Diagnosis

Adults of Hookworm species may be passed out spontaneously in feces. The microscopic examination of stool deposits after an iodine stained, formol-ether concentration method concentration reveals the characteristic ova.

Cutaneous Larva Migrans

If man comes in contact with hookworm larva of the dog (or cat), *A. braziliense* or *A. caninum*, penetration of the skin may take place. The larvae are unable to complete the migration to the small intestine and become trapped. Trapped larvae may survive for weeks or even months, migrating through the subcutaneous tissues.

Trapped larvae have been known to produce severe reaction, forming tunnels through the tissues, causing intense itchy skin eruption, producing a red, track under the skin which demonstrates accurately the wanderings of the larvae.

Often intense pruritis and scratching may lead to secondary bacterial invasion, known as 'creeping eruption' or 'cutaneous larval migrans'.

Trichuris trichiura

Introduction

Trichuris trichiura, more commonly known as the Whip Worm, due to the whip-like form of the body. These nematodes are most commonly seen in tropical climates and in areas where sanitation is poor. They seem to occur in areas particularly where *Ascaris* and Hookworms are found due to the eggs requiring the same conditions to allow for embryonation. Both species can be found in humans together. There are several species within this genus each infecting specific hosts, but only *T. trichiura* infects man. Causing human trichuriasis. It is a parasite that infects many more people than is generally appreciated, up to 800 million people throughout the tropics and temperate regions.

Life cycle eggs require a warm, moist environment with plenty of oxygen to ensure embryonation, but once they have embryonated they are extremely resistant to environmental conditions.

Adult worms are found in the cecum and upper part of the colon of man. In heavy infection they can be found in the colon and the terminal ileum. They attach to the mucosa by the anterior end or by embedding the anterior portion of the body in the superficial tissues, obtaining nutrition from the host tissues.

Once fertilized the female worms lay several thousands of eggs, which are unsegmented at the oviposition and are passed out in the feces. Once they have been passed out they require an embryonation period in the soil which may last from two weeks to several months, after which they become infective.

When embryonated eggs are swallowed by human hosts larvae are released into the upper duodenum. They then attach themselves to the villi lower down the small intestine or invade the intestinal walls. After a few days the juveniles migrate slowly down towards the cecum attaching themselves to the mucosa, reaching their final attachment site simultaneously.

The larvae reach maturity within three weeks to a month after infection, during which they undergo four molts. There is no lung migration and the time from ingestion of infective eggs to the development of adult worms is about three months.

Infection is achieved by swallowing soil that contains embryonated eggs. Therefore, children are most commonly seen to possess the infections, as they are more likely to swallow soil.

Morphology

The adult worms of *T. trichuria* are characterized by the enormously elongated capillary-like esophagus (anterior end); with the anus situated in the extreme tip.

The thin anterior portion of the worm is found embedded in the mucosa. There are no lips and the vulva is at the junction of the thread-like and thickened regions of the body. The posterior end is much thicker and lies free in the lumen of the large intestine.

The female measures 35-50µm long and the male 30-45µm long.

The ova are characteristically barrel shaped, bile stained with bipolar plugs. They measure 50-54µm by 20-23µm.

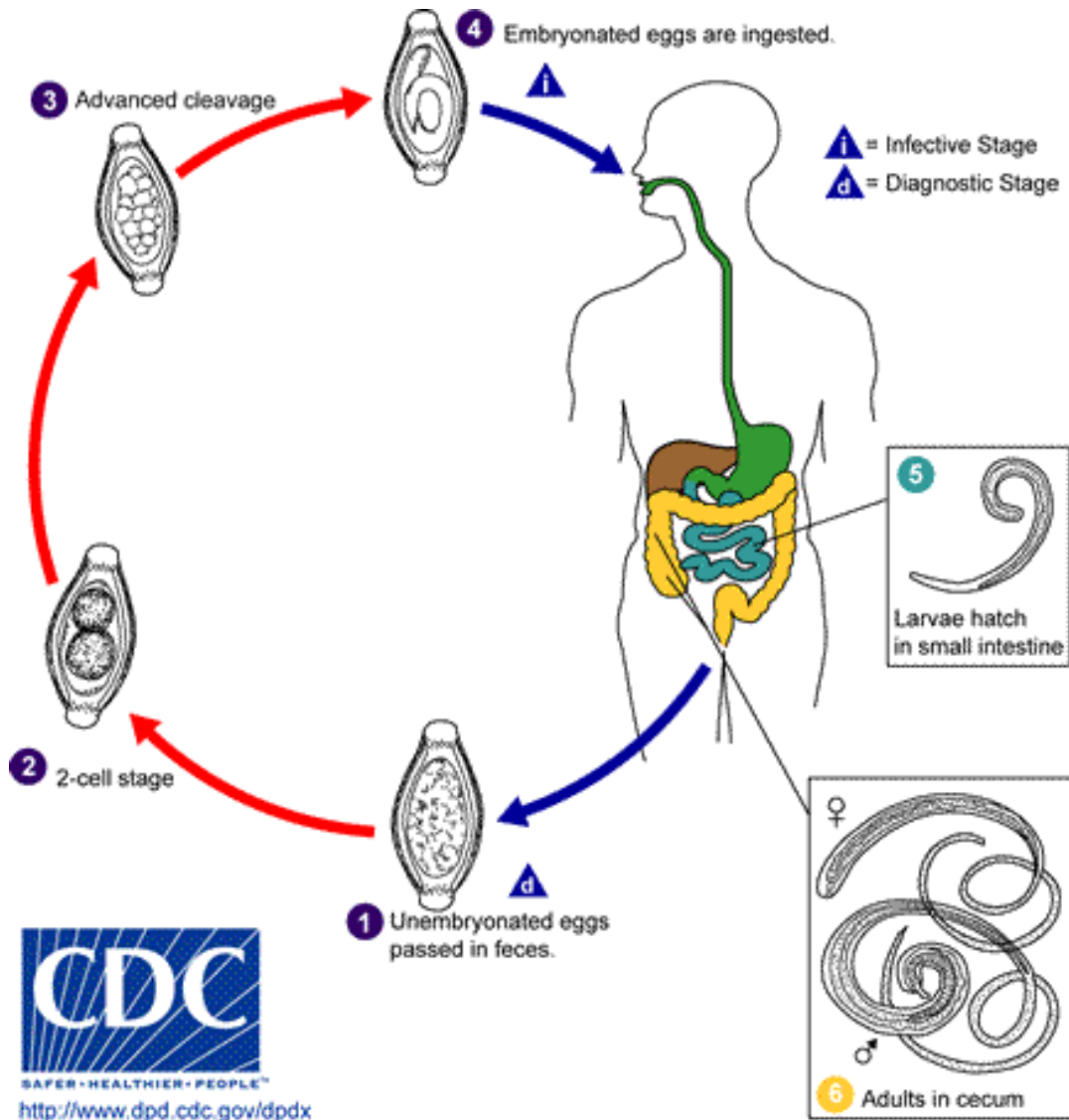


Illustration 5-3. The unembryonated eggs are passed with the stool **1**. In the soil, the eggs develop into a 2-cell stage **2**, an advanced cleavage stage **3**, and then they embryonate **4**; eggs become infective in 15 to 30 days. After ingestion (soil-contaminated hands or food), the eggs hatch in the small intestine, and release larvae **5** that mature and establish themselves as adults in the colon **6**. The adult worms (approximately 4 cm in length) live in the cecum and ascending colon. The adult worms are fixed in that location, with the anterior portions threaded into the mucosa. The females begin to oviposit 60 to 70 days after infection. Female worms in the cecum shed between 3,000 and 20,000 eggs per day. The life span of the adults is about 1 year. (SOURCE: CDC)

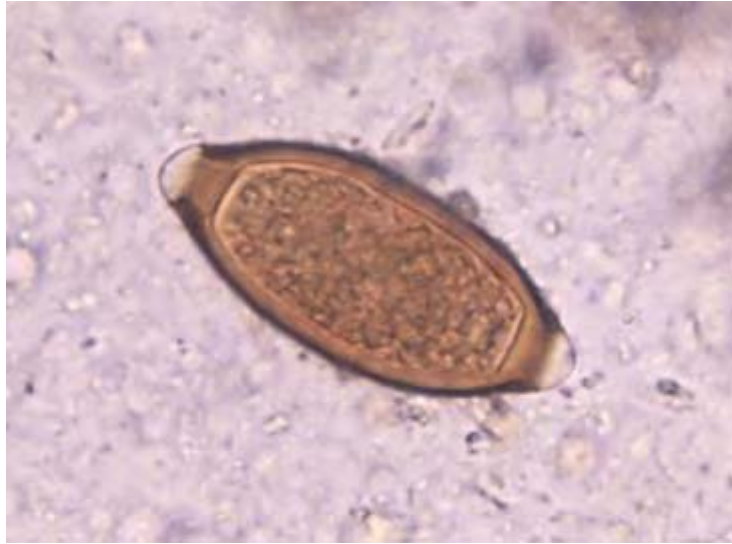


Image 5-5. *Trichuris trichuria* ovum with its opercular plugs, shown as white gaps at either end of the egg. (Saline wet prep) (SOURCE: PHIL 652 – CDC/Dr. Mae Melvin)

Clinical Disease

Most infections due to this nematode are light to moderate with minimal or no symptoms. However, a heavy worm burden may result in mechanical damage to the intestinal mucosa due to the adult worm being threaded into the epithelium of the cecum. Abdominal cramps, tenesmus, dysentery and prolapsed rectum may occur in these cases.

If a prolapsed rectum is observed, many worms may be seen adhering to the mucosa of the rectum.

Symptomatic infections are usually only seen in children. The majority of infections are chronic and mild, with nonspecific symptoms like diarrhea, anemia, growth retardation, eosinophilia.

Laboratory Diagnosis

The adult worms of *T. trichiura* are rarely seen in the feces. The microscopic examination of stool deposits after an iodine stained, formol-ether concentration method concentration reveals the characteristic barrel shaped ova. In symptomatic infections numerous numbers of eggs can be seen due to the prolific nature of the female worms, even in light infections many eggs can be seen in the smear.

Strongyloides stercoralis

Introduction

Strongyloides stercoralis is an intestinal nematode commonly found in warm areas, although it is known to survive in the sub-tropics (hot and humid conditions). The geographic range of *Strongyloides* infections tend to overlap with that of Hookworm due to the eggs requiring the same environmental conditions to induce embryonation.

This parasite is interesting in that it contains a free-living stage (exogenous) and a parasitic stage (endogenous) where the larvae undergo development in both stages.

Life cycle

The life cycle of *S. stercoralis* is a complex one as demonstrated in the diagram below.

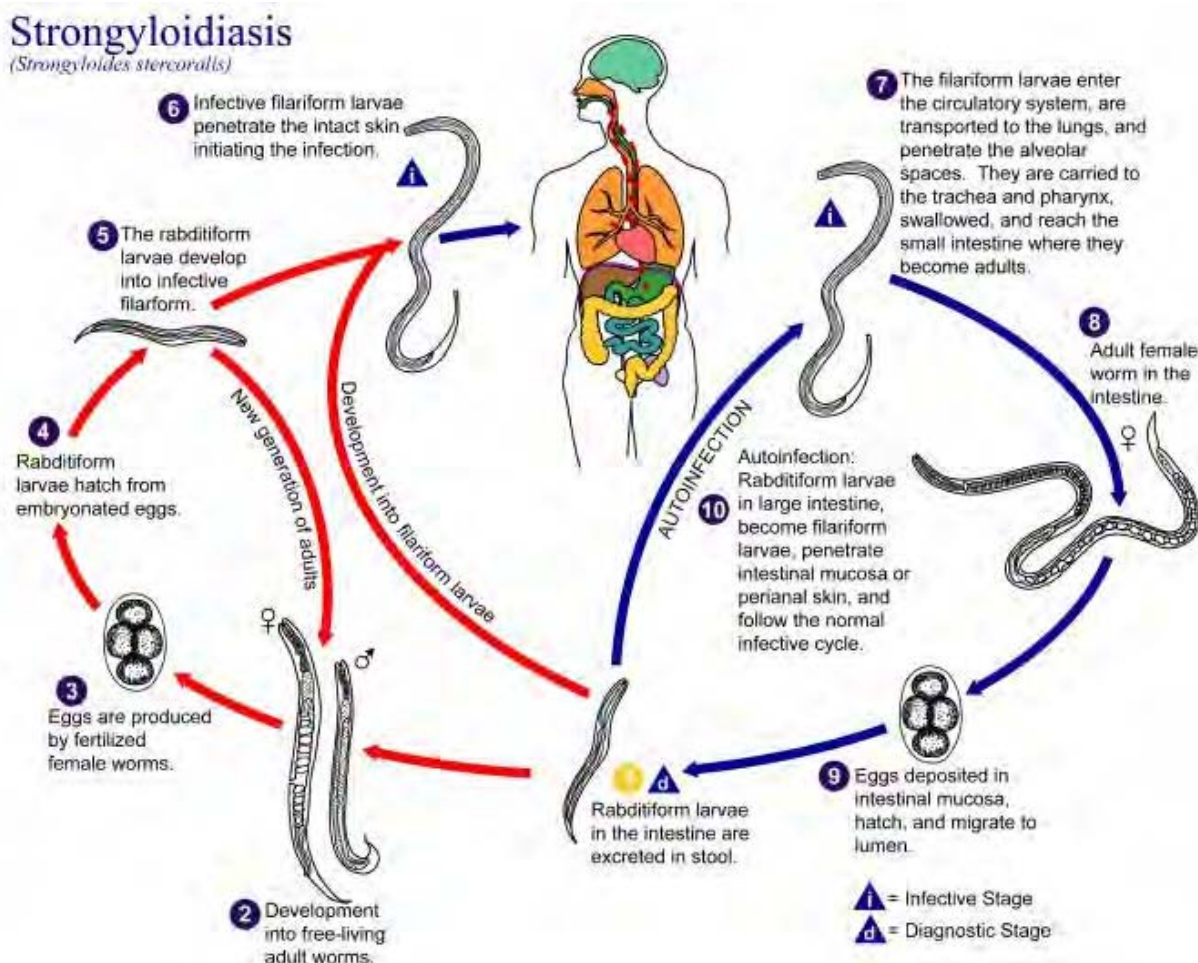


Illustration 5-4. Diagram of the life cycle of *Strongyloides stercoralis*. (SOURCE: PHIL 3419 – CDC/ Alexander J. da Silva, PhD/Melanie Moser)

Morphology

The first stage rhabditiform larvae measure approximately 250µm long by 20µm wide. They have a bulbed esophagus and a short buccal cavity. In an old specimen, rhabditiform larvae of *S. stercoralis* must be differentiated from those of hookworm which have a longer buccal cavity. The third stage or filariform larva is approximately 500µm long and has a notched tail (see below) compared with that of hookworm which is sheathed and has a long slender tail.

Adults are slender and possess an extremely long esophagus which in the female extends 1/3 to 1/2 of the body. The anal opening is ventral and the tail is pointed.

	RHABDITIFORM LARVA (First Stage. Has bulbed esophagus.)			FILARIFORM LARVA (Third Stage. Lacks prominent bulb in esophagus.)		
Species	Size	Genital Primordium	Buccal Cavity	Size	Length of Esophagus	Tip of Tail
<i>Strongyloides stercoralis</i>	225 µm × 16 µm. Range, 200- 300 µm × 16-20 µm.	Prominent. Is an elongate, tapered, or pointed structure located along ventral wall about the body length.	Short, about 1/3-1/2 as long as the width of the anterior end of the body.	550 µm × 20 µm. Range, 500-550 µm × 20-24 µm.	Extends approximately 1/2 length of body.	Notched.
Hookworm	250 µm × 17 µm. Range, 200- 300 µm × 14-17 µm.	Inconspicuous. Rarely distinct. When seen, is small, located nearer the tail than that of <i>Strongyloides</i> .	Long. Approximately as long as the width of the body.	500 µm. Range, 500-700 µm × 20-24 µm.	Extends about 1/4 length of body.	Pointed.

Table 5-2. Differential Morphology of the Diagnostic Stages of Helminths Found in Humans: Larvae (SOURCE: CDC)

Eggs are rarely found in the stool as they hatch in the intestine. They are oval and thin shelled, resembling those of hookworm but are smaller measuring 50-58µm by 30-34µm.

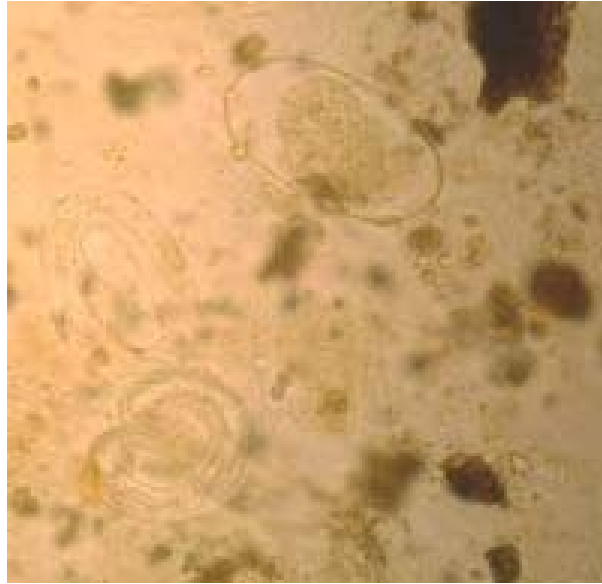

Image 5-6. Thin shelled ova of *Strongyloides stercoralis*. Measuring 50µm by 30µm, they are smaller than Hookworm eggs. (SOURCE: CDC)

Clinical Disease

Disease associated with infections due to *S. stercoralis* is varied, ranging from some patients being totally asymptomatic to the hyperinfection syndrome. There are three areas of involvement in *Strongyloides* infections; skin, lungs and intestine.

1. Initial skin penetration of the filariform larvae usually causes very little reaction, however with repeated infections the patient may mount a hypersensitive reaction thus preventing the larvae from completing its life cycle. The term larva currens is used when there is a rapidly progressing urticarial track.
2. The migration of larvae through the lungs may stimulate an immune response which can result in a cough, wheezing and fever.
3. Symptoms associated with intestinal strongyloidiasis may mimic a peptic ulcer due to ulceration of the intestinal mucosa. In heavy infections the intestinal mucosa may be severely damaged resulting in malabsorption. There may also be lower gastrointestinal bleeding. Eosinophila may be high.

Chapter 6.

The Trematodes

6.1 Infections of the Alimentary Canal and Associated Organs

Introduction

The trematodes (or flukes) are leaf shaped with an outer cover called the tegument which may be smooth or spiny. There are two suckers or attachment organs, an anterior oral sucker and a posterior ventral sucker. The suckers form a characteristic feature of the group, from which the name Trematode is derived from the Greek word for "hole." They can occur in a variety of host environments, with the majority being endoparasites but some are found to be ectoparasitic.

Most trematodes are hermaphroditic and most of the body consists of reproductive organs and their associated structures. The digestive system is well developed; they generally feed on intestinal debris, blood, mucus and other tissues, depending on the host environment.

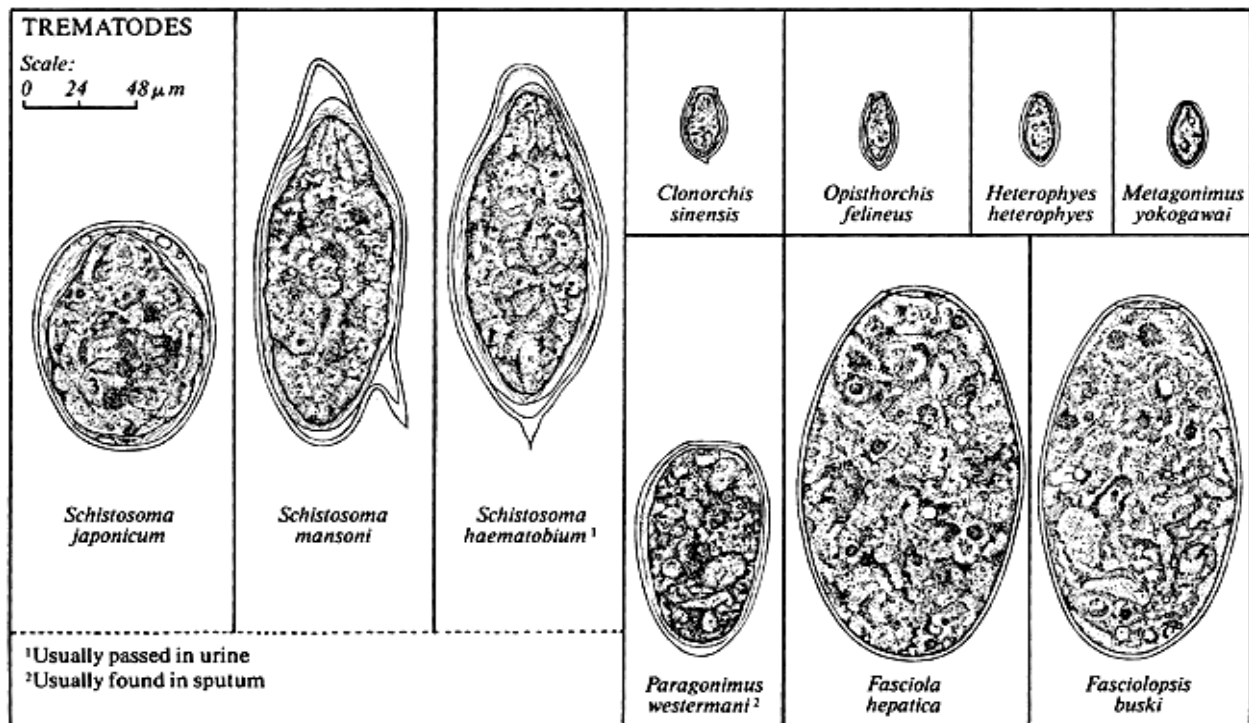


Illustration 6-1. Trematode Eggs Found in Stool Specimens of Humans. (SOURCE: CDC/Adapted from Melvin, Brooke, and Sadun, 1959)

Species	Size	Shape	Color	Stage of Development When Passed	Specific Features and Variations
Trematodes					
<i>Schistosoma mansoni</i>	140 µm x 66 µm. Range, 114-180 µm x 45-73 µm.	Elongated with prominent lateral spine near posterior end. Anterior end tapered and slightly curved.	Yellow or yellow brown.	Embryonated. Contains mature miracidium.	Lateral spine. Found in feces; in rare cases, in urine also. Eggs are discharged at irregular intervals and may not be found in every stool specimen. Are rare in chronic stages of infection.
<i>Schistosoma japonicum</i>	90 µm x 70 µm. Range, 68-100 µm x 45-80 µm.	Oval. Small lateral spine is often seen or may appear as a small hook or "knob" located in a depression in the shell.	Yellow or yellow brown.	Embryonated. Contains mature miracidium.	Found in feces. Often coated with debris and may be overlooked.
<i>Schistosoma haematobium</i>	143 µm x 60 µm. Range, 112-170 µm x 40-70 µm.	Elongated with rounded anterior end and terminal spine at posterior end.	Yellow or yellow brown.	Embryonated. Contains mature miracidium.	Terminal spine. Found in urine, occasionally in feces. Egg often covered with debris.
<i>Schistosoma intercalatum</i>	175 µm x 60 µm. Range, 140-240 µm x 50-85 µm.	Elongated with tapered anterior end and terminal spine. Sometimes "spindle-shaped."	Yellow or yellow brown.	Embryonated. Contains mature miracidium.	Terminal spine long, slender with bent tip. Resembles <i>S. haematobium</i> egg except it is longer, is thinner, and has a longer spine. Found in feces. May have debris adhering to shell.
<i>Schistosoma mekongi</i>	69 µm x 56 µm* Range, 51-73 µm x 39-66 µm.	Spherical. Small lateral spine, not always visible or may appear as a small "knob" in a depression in the shell.	Yellow or yellow brown.	Embryonated. Contains mature miracidium.	Found in feces. Closely resembles <i>S. japonicum</i> egg except it is smaller. May be coated with debris.
<i>Clonorchis sinensis</i>	30 µm x 16 µm. Range, 27-35 µm x 11-20 µm.	Small, ovoidal, or elongated with broad rounded posterior end and a convex operculum resting on "shoulders." A small "knob" may be seen on the posterior end.	Yellow brown.	Embryonated. Contains mature miracidium.	Small size, operculum and "knob" on posterior end. Shell often is covered by adhering debris.
<i>Opisthorchis felineus</i>	30 µm x 12 µm. Range, 26-30 µm x 11-15 µm.	Elongated with operculum on anterior end and pointed terminal "knob" on posterior end.	Yellow brown.	Embryonated. Contains mature miracidium.	Lacks prominent shoulders characteristic of <i>Clonorchis</i> and has more tapered end.
<i>Heterophyes heterophyes</i>	28 µm x 15 µm. Range, 28-30 µm x 15-17 µm.	Small, elongated or slightly ovoidal. Operculum. Slight "knob" at posterior end.	Yellow brown.	Embryonated. Contains mature miracidium.	Resembles <i>Clonorchis</i> egg but with less distinct shoulders. Operculum is broader than in <i>Clonorchis</i> .
<i>Metagonimus yokogawai</i>	28 µm x 17 µm. Range, 26-30 µm x 15-20 µm.	Small, elongated or ovoidal. Operculum. No "shoulders" at anterior end. Small "knob" often seen on posterior end.	Yellow or yellow brown.	Embryonated. Contains mature miracidium.	Resembles <i>Clonorchis</i> and <i>Heterophyes</i> eggs. Shell is slightly thinner than <i>Heterophyes</i> . Operculum is broader than <i>Clonorchis</i> .
<i>Paragonimus westermani</i>	85 µm x 53 µm. Range, 68-118 µm x 39-67 µm.	Ovoidal or elongate with thick shell. Operculum is slightly flattened and fits into shoulder area of shell. Posterior end is thickened. Egg often asymmetrical with one side slightly flattened.	Yellow brown to dark brown.	Unembryonated. Filled with yolk material in which a germinal cell is imbedded. Cells are irregular in size.	Found in sputum, occasionally in feces. Resembles egg of <i>D. latum</i> but is larger, slightly asymmetrical and the operculum is smaller and flatter. The widest part of the <i>Paragonimus</i> egg is usually anterior to the center; in a <i>D. latum</i> , the widest area is around the center.

<i>Fasciola hepatica</i>	145 µm x 80 µm. Range, 120-150 µm x 63-90 µm.	Ellipsoidal, thin shell. Small, indistinct operculum.	Yellow to light brown.	Unembryonated. Filled with yolk cells in which an indistinct germinal cell is imbedded.	Large size. Broadly oval eggs.
<i>Fasciolopsis buski</i>	140 µm x 80 µm. Range, 130-159 µm x 78-98 µm.	Ellipsoidal, thin shell. Small, indistinct operculum.	Yellow brown.	Unembryonated. Filled with yolk cells in which an indistinct germinal cell is imbedded.	Large size. Resembles <i>F. hepatica</i> egg and cannot be easily distinguished from <i>Fasciola</i> .

Table 6-1. Differential Morphology of the Diagnostic Stages of Helminths Found in Humans: Eggs (Trematodes) (SOURCE: CDC)

Trematodes require an intermediate host in their life cycle with vertebrates being the definitive host. Larval stages may occur in either invertebrate or vertebrate hosts.

There are three groups of trematodes:

- Monogenea, which typically are external parasites of fish with direct life cycles
- Aspidogastrea, these are endoparasites with the entire ventral surface as an adhesive organ
- Digenea, these are endoparasites with simpler adhesive organs and life cycles involving one or more intermediate hosts (indirect life-cycle). This section concentrates on the Digenean trematodes.

Most Digenean trematodes inhabit the alimentary canal of vertebrates and many of the associated organs, such as the liver, bile duct, gall bladder, lungs, bladder and ureter. These organs are rich in cavities containing food such as blood, mucus, bile and intestinal debris.

The Digenean trematodes have a complex life cycle, with rare exceptions, always involve a mollusk host. There may be six larval stages – the miracidium, sporocyst, redia, cercaria, mesocercaria (rare) and the metacercaria (the majority have 4 or 5 stages).

Trematode eggs have a smooth hard shell and the majority of them are operculate.

***Fasciola* species**

Introduction

Fasciola, *Fasciolopsis* and *Echinostoma* species are trematodes which parasitize the liver and intestines of a variety of vertebrates. They are hermaphroditic and their distinguishing characteristics are shown in **Table 6-2**.

Fasciola hepatica trematodes are not thought to infect man but in fact man is not an unusual host, with infections being reported in many countries including Europe and the USA. The eating of unwashed watercress appears to be the source of infection, with them ending up in the liver. The most common host is sheep where they can cause severe disease.

Fasciolopsis buski (giant intestinal fluke) is a duodenal parasite infecting both man and pigs. They are found widespread in Asia and China, but they have been found to be endemic in Taiwan, Thailand, Bangladesh and India. Night soil (human excreta) is used as a fertilizer in these countries on plants such as water chestnut and caltrops. The snails graze on these crops and also the definitive hosts eat them raw and unwashed, peeling the edible water plants with their teeth.

Infection with *Echinostoma* species is thought to be contracted by ingestion of fresh water snails containing metacercaria. Such as *Echinostoma ilocannum* which occurs in the Philippines. The metacercariae infect the large snail *Piolo luzionica* and in return are eaten raw.

Despite the large numbers of these flukes they are of little medical importance, the most important being *F. buski*.

Species	Geographic Distribution	Reservoir Hosts	Location of adult in host	Size of Ova
<i>Fasciola hepatica</i>	Cosmopolitan	Sheep	Bile Ducts	130-150µm by 63-90µm
<i>Fasciola gigantica</i>	Africa, the Orient and Hawaiian Islands	Camels, Cattle and Water Buffalo	Bile Ducts	160-190µm by 70-90µm
<i>Fasciolopsis buski</i>	Far-East and Indian Sub-continent	Pigs, Dogs and Rabbits	Intestine	130-140µm by 80-85µm
<i>Echinostoma species</i>	South East Asia and Japan	Variety of Mammals	Intestine	88-116µm by 58-69µm

Table 6-2. Table describing the characteristics which differentiate the various *Fasciola* species which are important to man.

Life Cycle and Transmission

The life cycles of *Fasciola*, *Fasciolopsis* and *Echinostoma* species are complex, requiring more than one intermediate host.

Adult worms inhabit the liver or bile ducts of the definitive host (human), where they lay many eggs which are deposited into the environment in the feces. They are immature when passed. If they are passed into water they become mature in nine to 15 days at the optimum temperature of 22-25°C.

Fasciolopsiasis

(*Fasciolopsis buski*)

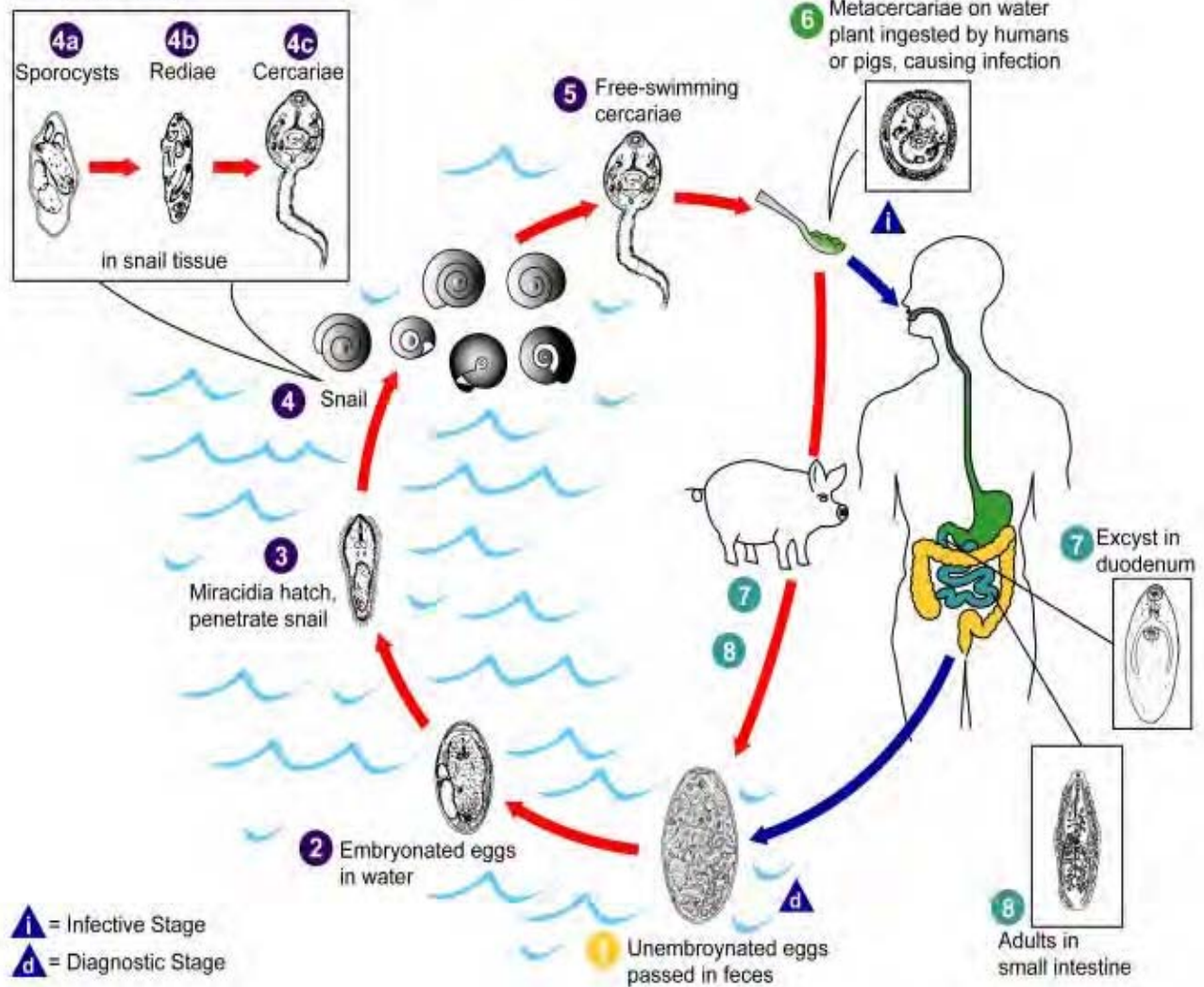


Illustration 6-2. The general life cycle of *Fasciola*, *Fasciolopsis* and *Echinostoma* species. Immature eggs are discharged in the biliary ducts and in the stool (1). Eggs become embryonated in water (2), eggs release miracidia (3), which invade a suitable snail intermediate host (4), including many species of the genus *Lymnae*. In the snail the parasites undergo several developmental stages (sporocysts (4a), rediae (4b), and cercariae (4c)). The cercariae are released from the snail (5) and encyst as metacercariae on aquatic vegetation or other surfaces. Mammals acquire the infection by eating vegetation containing metacercariae. Humans can become infected by ingesting metacercariae-containing freshwater plants, especially watercress (6). After ingestion, the metacercariae excyst in the duodenum (7) and migrate through the intestinal wall, the peritoneal cavity, and the liver parenchyma into the biliary ducts, where they develop into adults (8). In humans, maturation from metacercariae into adult flukes takes approximately 3 to 4 months. The adult flukes (*Fasciola hepatica*: up to 30 μm by 13 μm ; *F. gigantica*: up to 75 μm) reside in the large biliary ducts of the mammalian host. *Fasciola hepatica* infect various animal species, mostly herbivores.

The life cycle of the *Echinostomes* differs by one minor point: the cercariae (4c) encyst within the tissues of the intermediate host (4) in which sporocysts (4a) and rediae (4b) develop, or penetrate and encyst in other animals such as amphibians or fish. (SOURCE: PHIL 3393 - CDC/Alexander J. da Silva, PhD/Melanie Moser)

Morphology

The morphology of the adult flukes of *Fasciola*, *Fasciolopsis* and *Echinostoma* species is well documented. They are large leaf-shaped parasites about 2–3cm long. There are two suckers, an anterior oral sucker surrounding the mouth and a ventral sucker (acetabulum) on the ventral surface.

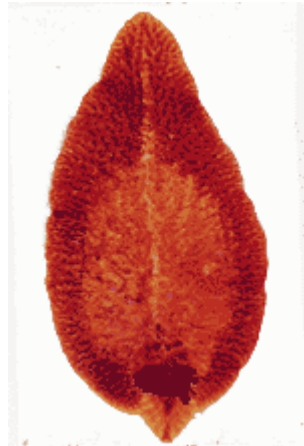

Image 6-1. Adult fluke of a *Fasciola* Trematode. Their morphology shows a large leaf-shape about 2–3cm long with two suckers, an oral and a ventral one. (SOURCE: CDC)

The outer tegument is covered in tiny spines which face backwards enabling them to attach themselves along with their suckers to the tissues.

Ova are all thin shelled, ellipsoid, quinone colored (bile stained) with an operculum that is often inconspicuous. Although ova of *Echinostoma* species can usually be differentiated by size due these flukes being much smaller in size than *F. Buski* and *F. hepatica*, there is much cross-over in the size of *Fasciola* and *Fasciolopsis* species.

Pathogenesis

Light infections due to *Fasciola hepatica* may be asymptomatic. However, they may produce hepatic colic with coughing and vomiting; generalized abdominal rigidity, headache and sweating, irregular fever, diarrhea and anemia.

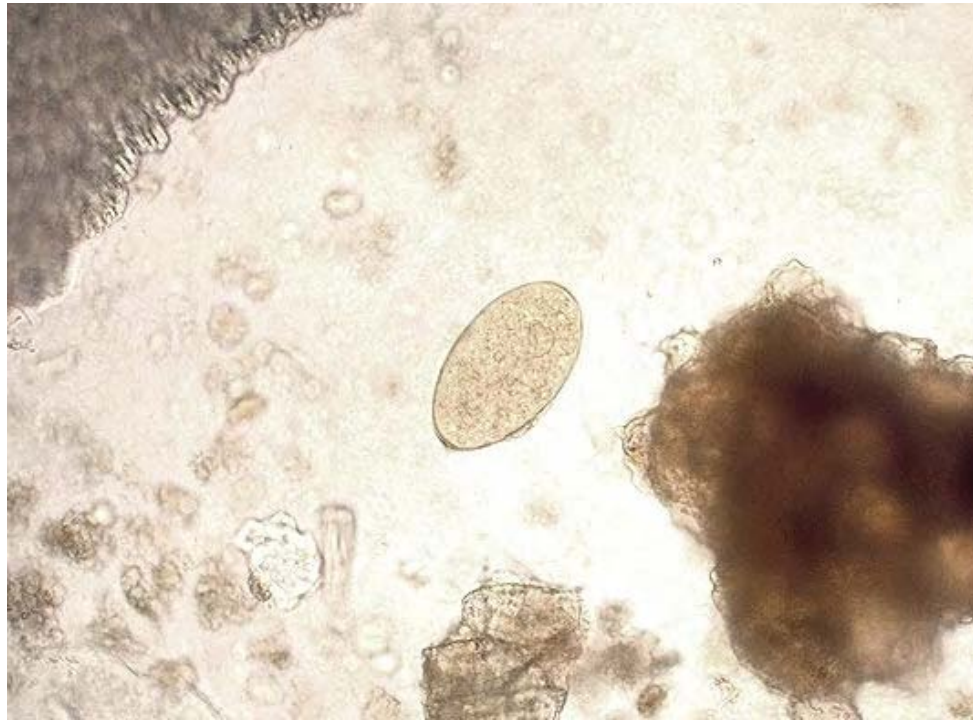


Image 6-2. Ova of *Fasciola* are ovoid in shape, quinone color and often showing an inconspicuous operculum. *Fasciola hepatica* ova measure 130 - 150 μ m by 63 - 90 μ m. There is much cross-over in ova size between all of the *Fasciola* species. (SOURCE: PHIL 1540 - CDC/Dr. Mae Melvin)

Infections due to *Fasciola gigantica* occur mainly in cattle raising areas and cause clinical symptoms similar to those of *Fasciola hepatica* although human infections are less common.

The adult flukes of *Fasciolopsis buski* attach to the intestine, resulting in local inflammation and ulceration. Heavier infections may subsequently lead to abdominal pain, malabsorption and persistent diarrhea, edema and even intestinal obstruction. Marked eosinophilia may be seen.

The adult flukes of *Echinostoma* species attach to the intestine resulting in little damage to the intestinal mucosa. Light infections are generally asymptomatic and heavy infections may produce light ulceration, diarrhea and abdominal pain.

Laboratory Diagnosis

Definitive diagnosis is made by observing the ova in feces, since the flukes are very prolific any significant infection will be easily picked up. Where identification cannot be made from the size of the ova, clinical information and the source of infection may help to provide a diagnosis. Serological techniques are available for the diagnosis of *Fasciola hepatica*.

Clonorchis sinensis

Introduction

Clonorchis sinensis, also known as the Chinese (aka Oriental) liver fluke is a narrow elongate liver fluke found in the Far East, mainly Japan, Korea, China, Taiwan and Vietnam.

It belongs to the group of Oriental liver flukes where there are three main species which commonly infect man. The other two species are *Opisthorchis felineus* and *Opisthorchis viverrini*. (Table 6-2) The three species are so similar in their morphology, life cycles and pathogenicity that they are very rarely discussed as separate species.

All members of this group are parasites of fish-eating mammals, particularly in Asia and Europe. Man is the definitive hosts and water snails and fish are the intermediate hosts. Infections can be easily avoided by man not eating raw fish since this is the only way that infection can be passed on.

Clonorchis sinensis parasitize the biliary duct in humans who become infected by eating raw or undercooked fish. Dogs and cats are the most important reservoir hosts.

Life Cycle and Transmission

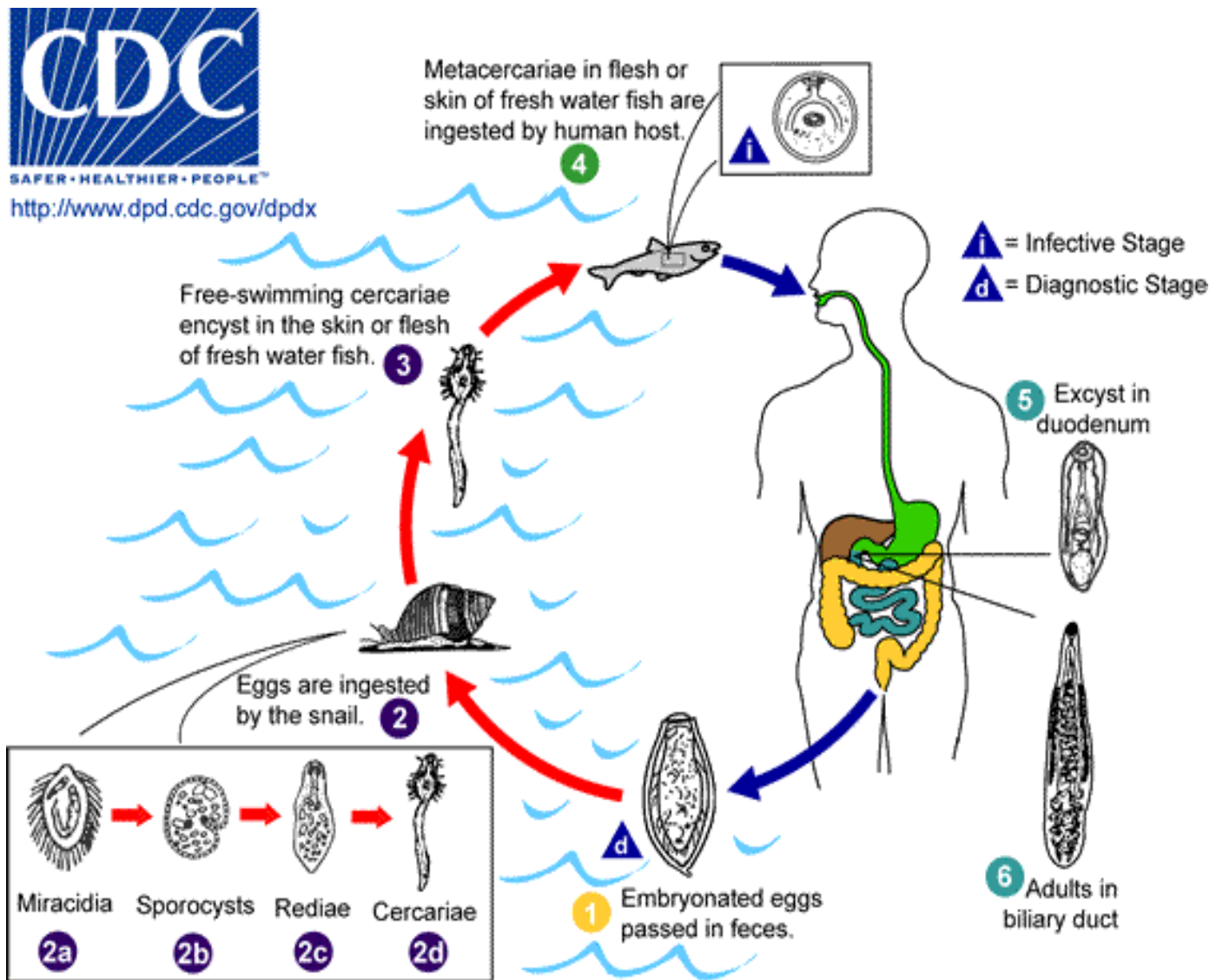


Illustration 6-3. Diagram illustrating the life cycle of *Clonorchis sinensis* (Chinese Liver Fluke). This parasite requires the involvement of two intermediate hosts (fresh water snails and fish) to complete the life cycle. Embryonated eggs are discharged in the biliary ducts and in the stool **1**. Eggs are ingested by a suitable snail intermediate host **2**; there are more than 100 species of snails that can serve as intermediate hosts. Each egg releases a miracidia **2a**, which go through several developmental stages (sporocysts **2b**, rediae **2c**, and cercariae **2d**). The cercariae are released from the snail and after a short period of free-swimming time in water, they come in contact and penetrate the flesh of freshwater fish, where they encyst as metacercariae **3**. Infection of humans occurs by ingestion of undercooked, salted, pickled, or smoked freshwater fish **4**. After ingestion, the metacercariae excyst in the duodenum **5** and ascend the biliary tract through the ampulla of Vater **6**. Maturation takes approximately one month. The adult flukes (measuring 10 to 25 μm by 3 to 5 μm) reside in small and medium sized biliary ducts. In addition to humans, carnivorous animals can serve as reservoir hosts. (SOURCE: PHIL 3385 - CDC/Alexander J. da Silva, PhD/Melanie Moser)

Morphology

The adult flukes measure 11–20 μ m by 3–4.5 μ m and are lanceolate in shape, translucent and brownish in color. They are all hermaphroditic. Keeping in common with other flukes they possess two suckers.

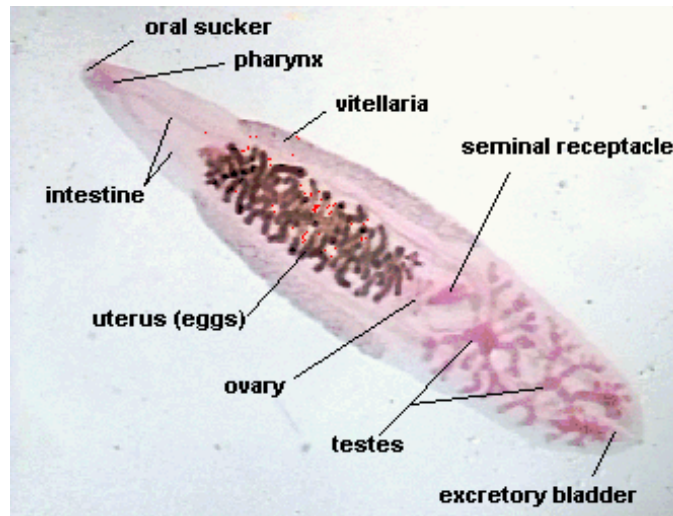


Image 6-3. Diagram illustrating the internal morphology of the Oriental liver fluke, *Clonorchis sinensis*. (SOURCE: SFSU.EDU)

The ova of *Clonorchis sinensis* contain fully developed miracidia and possess prominent opercular shoulders (flask shaped egg) and are operculate. They are bile stained and measure 29 μ m by 16 μ m. In wet mounts they are transparent and you can quite easily see their anatomy. There can be up to 6,000 worms present and a daily egg output of 1,000 eggs per microliter of bile or 600 per gram of feces.

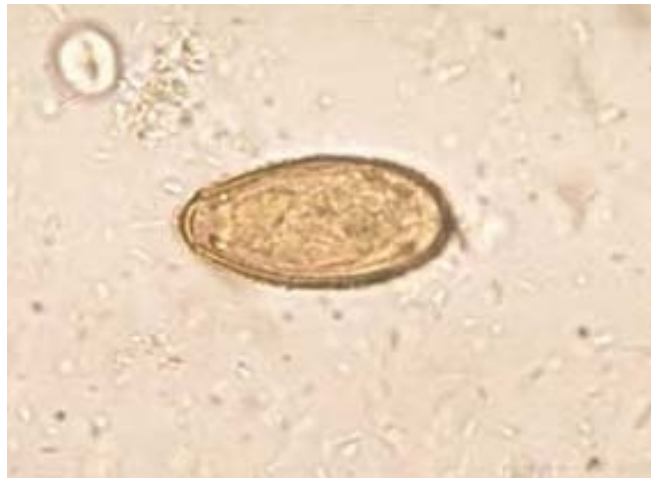

Image 6-4. Ova of *Clonorchis sinensis*. Showing the prominent opercular shoulders which makes identifying this trematode easy. They are described as flask shaped, bile stained. (SOURCE: PHIL 695 – CDC/Dr. Mae Melvin)

The cercariae possess eyespots, the penetration and cystogenous glands are also well developed.

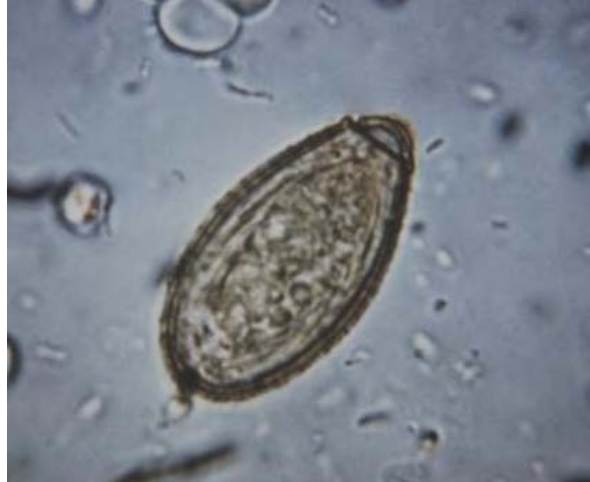

Image 6-5. Saline smear showing the characteristic flask shape of the *Clonorchis sinensis* ova. They are bile stained with a smooth outer coat. (SOURCE: PHIL 4845 – CDC)

Pathogenesis

Many millions of people become infected every year but only a minority suffers from any illness. The pathology is related to the number of parasites present. Light infections of up to 50 eggs or more are usually asymptomatic. A heavy infection of 500 or more eggs may cause serious illness.

Acute infections may be characterized by fever, diarrhea, epigastric pain, enlargement and tenderness of liver and sometimes jaundice. The invasion by these worms in the gall bladder may cause cholecystitis, due to flukes becoming impacted in the common bile duct.

Laboratory Diagnosis

Definitive diagnosis is made by observing the characteristic ova in feces following an iodine stained, formol-ether concentration method of the feces or from duodenal aspirates when there is complete obstructive jaundice or from the Entero-Test.

	<i>Heterophyes heterophyes</i>	<i>Metagonimus yokogawai</i>	<i>Opisthorchis viverrini</i>	<i>Dicrocoelium dendriticum</i>
Geographic distribution	Far East	Far East	Thailand	Far East
Location of adult in host	Small intestine	Small intestine	Liver and bile ducts	Liver and bile ducts
Size of ova	26.5-30µm by 15-17µm	26.5-30µm by 15-17µm	26.7µm by 15µm	38-45µm by 22-30µm
Shape of ova	Prominent opercular shoulders Bile stained	Prominent opercular shoulders Bile stained	Prominent opercular shoulders Bile stained	Dark brown, thick shelled and large operculum
Infection acquired by	Eating raw or pickled fish	Eating raw or pickled fish	Eating raw fresh water fish	Eating infected ants
Symptoms	Occasionally diarrhea and vomiting	Occasionally diarrhea and vomiting	Malaise and right upper quadrant pain	Biliary and digestive problems

Table 6-3. Table summarizing the less common flukes that are known to infect man. (CDC)

Paragonimus westermani

Introduction

Paragonimus westermani is a lung fluke found in both humans and animals. The adults are 12µm long and are found in capsules in the lung. Although they are hermaphroditic, it is necessary for worms to be present in the cyst for fertilization to occur. The disease is seen in the Far East, China, South East Asia, and America.

Life Cycle

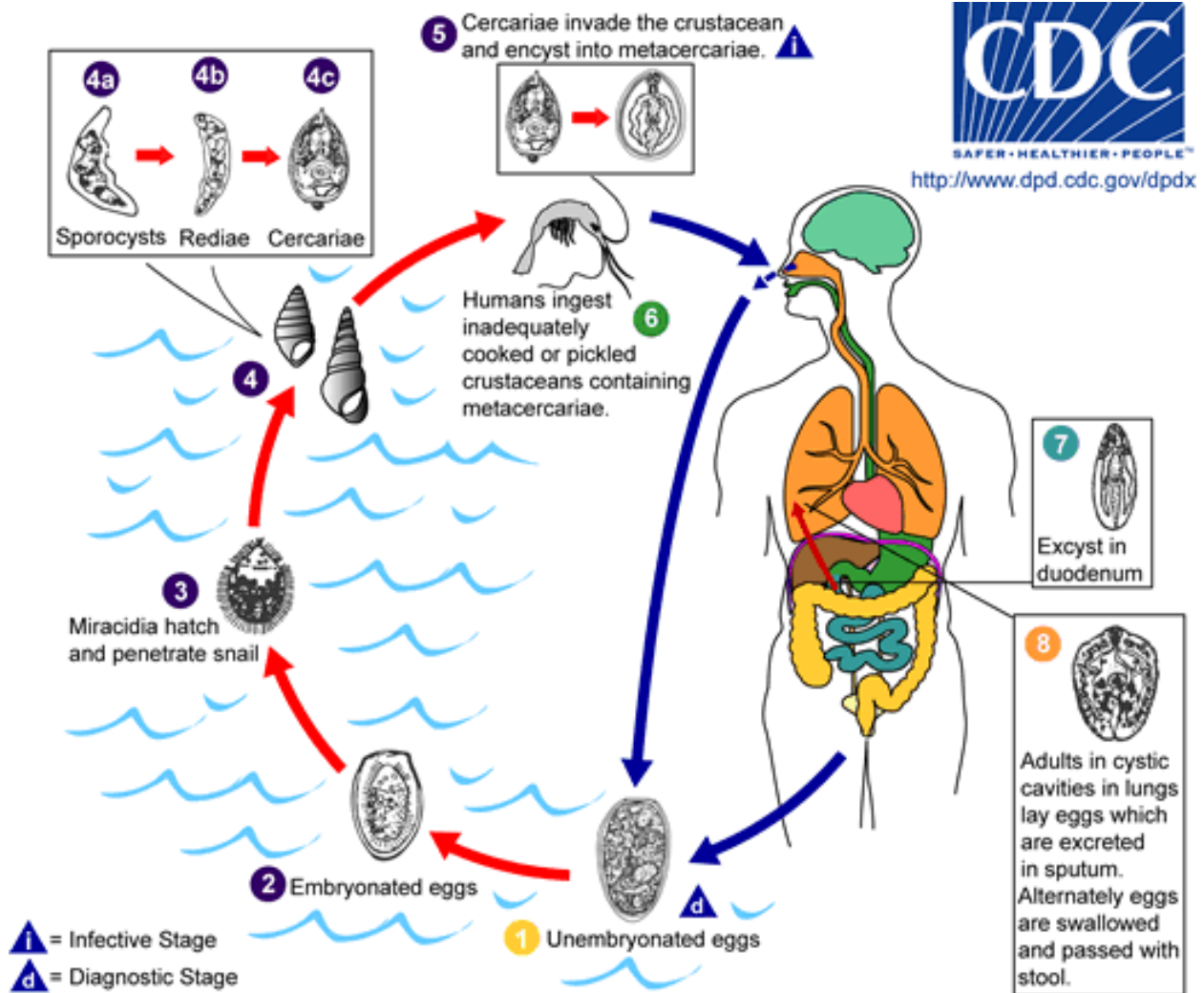


Illustration 6-4. Diagram of the general life cycle of the lung fluke, *Paragonimus westermani*. The eggs are excreted unembryonated in the sputum, or alternately they are swallowed and passed with stool **1**. In the external environment, the eggs become embryonated **2**, and miracidia hatch and seek the first intermediate host, a snail, and penetrate its soft tissues **3**. Miracidia go through several developmental stages inside the snail **4**: sporocysts **4a**, rediae **4b**, with the latter giving rise to many cercariae **4c**, which emerge from the snail. The cercariae invade the second intermediate host, a crustacean such as a crab or crayfish, where they encyst and become metacercariae. This is the infective stage for the mammalian host **5**. Human infection with *P. westermani* occurs by eating inadequately cooked or pickled crab or crayfish that harbor metacercariae of the parasite **6**. The metacercariae excyst in the duodenum **7**, penetrate through the intestinal wall into the peritoneal cavity, then through the abdominal wall and diaphragm into the lungs, where they become encapsulated and develop into adults **8** (7.5 to 12 μm by 4 to 6 μm). The worms can also reach other organs and tissues, such as the brain and striated muscles, respectively. However, when this takes place completion of the life cycles is not achieved, because the eggs laid cannot exit these sites. Time from infection to oviposition is 65 to 90 days. (SOURCE: PHIL 3415 - CDC/Alexander J. da Silva, PhD/Melanie Moser)

Infections may persist for 20 years in humans. Animals such as pigs, dogs, and a variety of feline species can also harbor *P. westermani*.

Morphology

The adult worm is an ovoid, reddish brown fluke about 12µm long.

The eggs are ovoid, brownish yellow, thick shelled and operculated. They measure 80-100µm by 45-65µm and may be confused with the ova of *Diphyllobothrium latum*.

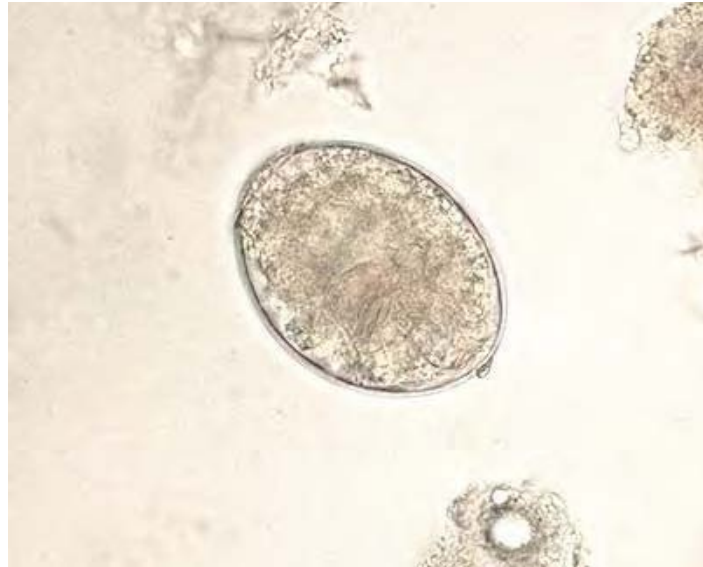

Image 6-6. Saline smear of *Paragonimus westermani* egg. The egg shells are thick and operculated.
(SOURCE: PHIL 1541 – CDC/ Dr. Mae Melvin)

Clinical Disease

As the parasites grow in the lung cyst, inflammatory reaction and fever occurs. The cyst ruptures and a cough develops resulting in an increase in sputum. The sputum is frequently blood tinged and may contain numerous dark brown eggs and Charcot-Leyden crystals. Hemoptysis may occur after paroxysms of coughing. Dyspnea and bronchitis develop with time. Bronchiectasis may occur and pleural effusion is sometimes seen. The disease resembles pulmonary tuberculosis. Cerebral calcification may also occur.

Laboratory Diagnosis

Diagnosis is based on finding the characteristic eggs in brown sputum. The eggs can also be found in the feces due to swallowing sputum. A chest x-ray may show cystic shadows and calcification. Serological tests, in particular, the ELISA method, are useful diagnostic tests.

Schistosomes

Introduction

The Schistosomes are blood trematodes belonging to the Phylum *Platyhelmintha*. They differ from other trematodes in that they have separate sexes. The male worms resemble a rolled leaf where they bear the longer and more slender female in a ventral canal (the gynaecophoric canal). They require definitive and intermediate hosts to complete their life cycle. There are five species of *Schistosomes* responsible for human disease; *S. mansoni*, *S. haematobium* and *S. japonicum* with *S. mekongi* and *S. intercalatum* being less common.

They are the only trematodes that live in the blood stream of warm-blooded hosts. The blood stream is rich in glucose, and amino acids, so along with the plasma and blood cells, it represents an environment which is suitable for egg producing trematodes.

Over 200 million people are infected over at least 75 countries with 500 million or more people exposed to infection. With the disease spreading due to improved water supplies being created therefore, forming potentially new habits for snails. The disease caused is called schistosomiasis or Bilharzia and is the most important of helminth diseases.

Infection by the three most common species is the same in both sexes and in all age groups. Though, *S. mansoni* and *S. haematobium* is seen to occur more often and most heavily in teenagers especially males.

Life Cycle

Adult worms of *S. mansoni* live in the plexus of veins draining the rectum and colon, and in branches of the portal vein in the liver.

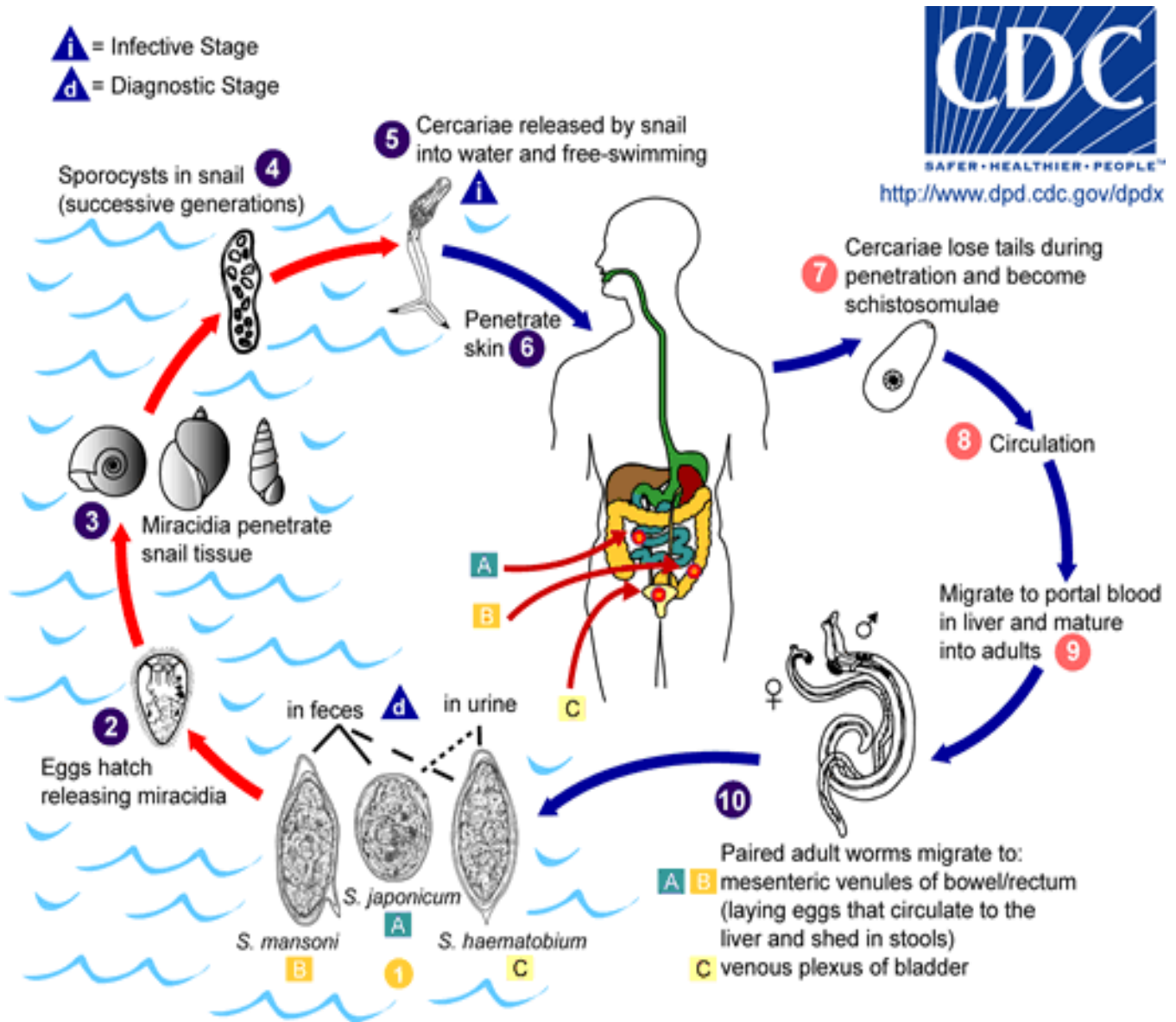


Illustration 6-5. Diagram illustrating the general life cycle of the *Schistosomes*. Eggs are eliminated with feces or urine **1**. Under optimal conditions the eggs hatch and release miracidia **2**, which swim and penetrate specific snail intermediate hosts **3**. The stages in the snail include 2 generations of sporocysts **4** and the production of cercariae **5**. Upon release from the snail, the infective cercariae swim, penetrate the skin of the human host **6**, and shed their forked tail, becoming schistosomulae **7**. The schistosomulae migrate through several tissues and stages to their residence in the veins (**8**, **9**). Adult worms in humans reside in the mesenteric venules in various locations, which at times seem to be specific for each species **10**. For instance, *S. japonicum* is more frequently found in the superior mesenteric veins draining the small intestine **A**, and *S. mansoni* occurs more often in the superior mesenteric veins draining the large intestine **B**. However, both species can occupy either location, and they are capable of moving between sites, so it is not possible to state unequivocally that one species only occurs in one location. *S. haematobium* most often occurs in the venous plexus of bladder **C**, but it can also be found in the rectal venules. The females (size 7 to 20 μm ; males slightly smaller) deposit eggs in the small venules of the portal and perivesical systems. The eggs are moved progressively toward the lumen of the intestine (*S. mansoni* and *S. japonicum*) and of the bladder and ureters (*S. haematobium*), and are eliminated with feces or urine, respectively **1**. Pathology of *S. mansoni* and *S. japonicum* schistosomiasis includes: Katayama fever, hepatic perisinusoidal egg granulomas, Symmers' pipe stem periportal fibrosis, portal hypertension, and

occasional embolic egg granulomas in brain or spinal cord. Pathology of *S. haematobium* schistosomiasis includes: hematuria, scarring, calcification, squamous cell carcinoma, and occasional embolic egg granulomas in brain or spinal cord. Human contact with water is thus necessary for infection by schistosomes. Various animals, such as dogs, cats, rodents, pigs, hourse and goats, serve as reservoirs for *S. japonicum*, and dogs for *S. mekongi*. (SOURCE: CDC)

Adults of *S. japonicum* live in the anterior mesenteric blood vessels and in the portal vein in the liver; while the adults of *S. haematobium* live in the vesical plexus draining the bladder.

Once the eggs are laid by the adult female worms the majority of them first pass through the veins of the blood vessel in which the worm is living, and then into the lumen of the intestine and are passed in the feces (*S. mansoni* and *S. japonicum*), or into the lumen of the bladder, and are then passed in the urine (*S. haematobium*). Those eggs that reach fresh water hatch, releasing a miracidium which, to develop further must infect a snail of the correct species within 24 hours. The eggs of each species are markedly different but each produce virtually identical miracidium.

Asexual multiplication takes place in the snail, and results in the release of cercariae (minute in size with forked tails, 200µm long) into the water about 3–6 weeks later. Cercariae actively swim around and when they have located, or come into contact with, a definitive host they actively penetrate the skin. They can stay active looking for a host for 24–48 hours after which if they don't find a host they will die. The head of the cercariae migrates to the liver and develops into either adult male or female worms (flukes), here they pair up and then migrate to their region of the venous blood system (species specific sites). The females leave the males and moves to smaller venules closer to the lumen of the intestine or bladder to lay her eggs (about six weeks after infection). The majority of adult worms live from 2–4 years, but some can live considerably longer.

Schistosoma mansoni

Introduction

S. mansoni occurs in West and Central Africa, Egypt, Malagasy, the Arabian Peninsula, Brazil, Surinam, Venezuela and the West Indies. The intermediate host is an aquatic snail of the genus *Biomphalaria*. Man is the most common definitive host, occasionally baboons and rats are infected.

The adult worms live in smaller branches of the inferior mesenteric vein in the lower colon.

Morphology

The adult males measure up to 15 millimeters in length and females up to 10µm. The schistosomes remain in copula throughout their life span, the uxorious male surrounding the female with his gynaecophoric canal. The male is actually flat but the sides roll up forming the

groove. The cuticle of the male is covered with minute papillae. The female only possesses these at the anterior and posterior end as the middle section being covered by the male body. Oral and ventral suckers are present, with the ventral one being larger serving to hold the worms in place, preventing them being carried away by the circulatory current.

The ova of *S. mansoni* are 114-175µm long by 45-68µm wide. They are light yellowish brown, elongate and possess a lateral spine. The shell is acid fast when stained with modified Ziehl-Neelsen Stain.

A non-viable egg is dark colored and shows no internal structural detail or flame cell movement. Eggs can become calcified after treatment and are usually smaller, appear black and often distorted with a less distinct spine.

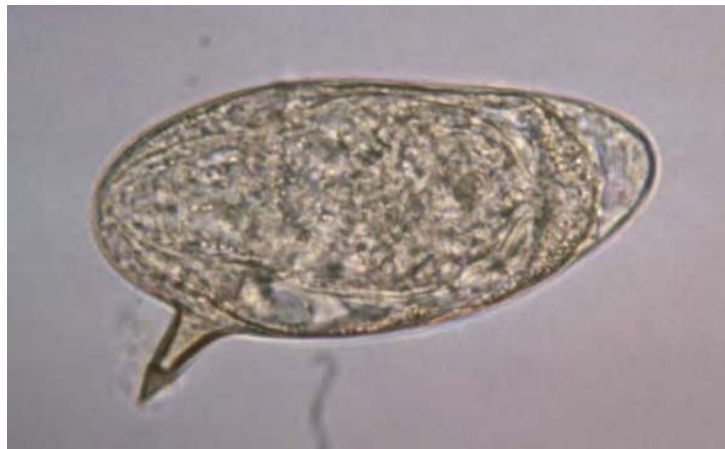

Image 6-7. Micrograph of a *S. mansoni* ova, clearly showing its lateral spine which is a good distinguishing factor when identifying *Schistosoma* ova. They range in size between 114-175µm long by 45-68µm wide. (SOURCE: PHIL 4841 – CDC)

The schistosomes differ from other trematodes in that they are dioecious, digenetic, their eggs are not operculate and infection is acquired by penetration of cercaria through the skin.

Clinical Disease

The clinical disease is related to the stage of infection, previous host exposure, worm burden and host response. Cercarial dermatitis (swimmers itch) follows skin penetration and results in a maculopapular rash which may last 36 hours or more.

After mating, the mature flukes migrate to the venules draining the large intestine. Their eggs are laid and they penetrate the intestinal wall. They are then excreted in the feces, often accompanied by blood and mucus.

It is the eggs and not the adult worms, which are responsible for the pathology associated with *S. mansoni* infections. The adult flukes acquire host antigen which protects them from the host's immune response.

The host's reaction to the eggs which are lodged in the intestinal mucosa, leads to the formation of granulomata and ulceration of the intestinal wall. Some of the eggs reach the liver via the portal vein. The granulomatous response to these eggs can result in the enlargement of the liver with fibrosis, ultimately leading to portal hypertension and ascites. The spleen may also become enlarged. Other complications may arise as a result of deposition of the eggs in other organs e.g. lungs.

Katayama fever is associated with heavy primary infection and egg production. Clinical features include high fever, hepatosplenomegaly, lymphadenopathy, eosinophilia and dysentery. This syndrome occurs a few weeks after primary infection.

Laboratory Diagnosis

Microscopy

Laboratory confirmation of *S. mansoni* infection can be made by finding the eggs in the feces after an iodine stained, formol-ether concentration method. When eggs cannot be found in the feces, a rectal biopsy can be examined.

Serology

Serological tests are of value in the diagnosis of schistosomiasis when eggs cannot be found. An enzyme linked immunosorbent assay (ELISA) using soluble egg antigen, is employed at HTD.

Schistosoma japonicum

Introduction

Schistosoma japonicum is found in China, Japan, the Philippines, and Indonesia. It causes disease of the bowel with the eggs being passed out in the feces.

It differs from *S. mansoni* and *S. haematobium* in that it is a zoonosis in which a large number of mammals serve as reservoir hosts; cats, dogs and cattle playing major roles in the transmission of the disease.

The life cycle is not very different from that of *S. mansoni*, the intermediate hosts are from the subspecies *Oncomelania hupensis*. Sexual maturity is reached in about four weeks and eggs may be seen in the feces as quickly as five weeks.

The worms live coupled together in the superior, mesenteric veins and deposit 1500–3500 eggs per day in the vessels of the intestinal wall. The eggs infiltrate through the tissues and are passed in the feces.

Morphology

The adult worms are longer and narrower than the *S. mansoni* worms. The ova are about 55-85 μ m by 40-60 μ m, oval with a minute lateral spine or knob.

Clinical Disease

The main lesions are again due to the eggs, occurring in the intestine and liver. The eggs which are sequesters in the intestine mucosa or submucosa initiate granulomatous reactions, resulting in the formation of pseudotubercles.

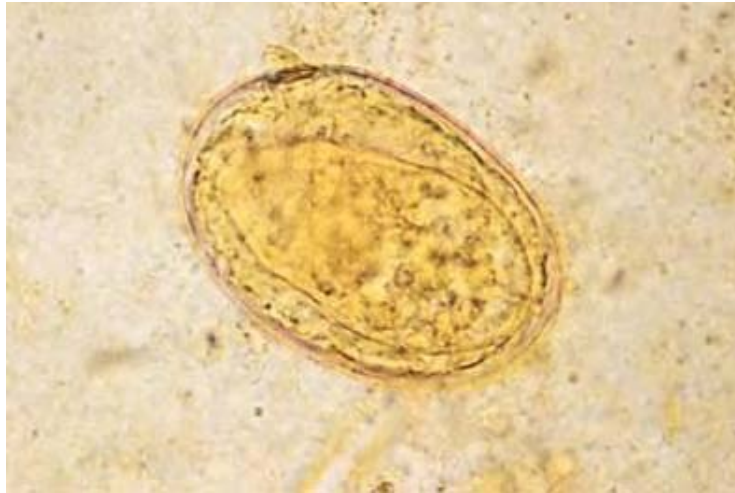

Image 6-8. Unstained micrograph of a *S. japonicum* ova. They are oval in shape with a minute lateral spine or knob. (SOURCE: PHIL 649 – CDC/Dr. Moore)

Due to the number of eggs released by the females the infection is more severe than one with *S. mansoni*. This is also due to the parasite being less well adapted to man, therefore, the circumoval granuloma is very large. The initial illness can be prolonged and sometimes fatal.

Laboratory Diagnosis

Microscopy

Laboratory confirmation of *S. japonicum* infection can be made by finding the eggs in the feces after an iodine stained, formol-ether concentration method. When eggs cannot be found in the feces, a rectal biopsy can be examined.

Other Intestinal *Schistosome* species

Other Schistosome species which are responsible for human disease are *S. mekongi* and *S. intercalatum*. These two species cause similar symptoms to that of *S. mansoni* and can be summarized in Table 6-3.

	<i>S. mekongi</i>	<i>S. intercalatum</i>
Geographic location	Mekong River basin	Central and west Africa
Diagnostic specimen	Stool, rectal biopsy, serology	Stool, rectal biopsy, serology
Egg size	30-55µm by 60-65µm	140-240µm by 50-85µm
Egg shape	Oval, minute lateral spine or knob	Elongate, terminal spine

Table 6-4. Table describing the other less common intestinal Schistosome species that are known to cause disease in man. (SOURCE: CDC)

Schistosoma haematobium

Introduction

Schistosoma haematobium is different from the other two species previously mentioned in that it causes urinary schistosomiasis. It occurs in Africa, India and the Middle East. The intermediate host is the *Bulinus* snail.

Just like *S. mansoni*, its distribution runs parallel to the irrigation projects and in areas which favor the intermediate hosts. They are exclusively parasites of man.

The mature worms live in copula mainly in the inferior mesenteric veins and the females deposit their eggs in the walls of the bladder and finally making their way into the urine. The life cycle is very similar to that of *S. mansoni*, with sexual maturity being reached within 4–5 weeks, but eggs may not appear in the urine until 10–12 weeks or even later.

Morphology

The adult worms are longer than those of *S. mansoni*. The ova are relatively large, measuring 110-170µm in length and 40-70µm in width. They have an elongated ellipsoid shape with a prominent terminal spine.

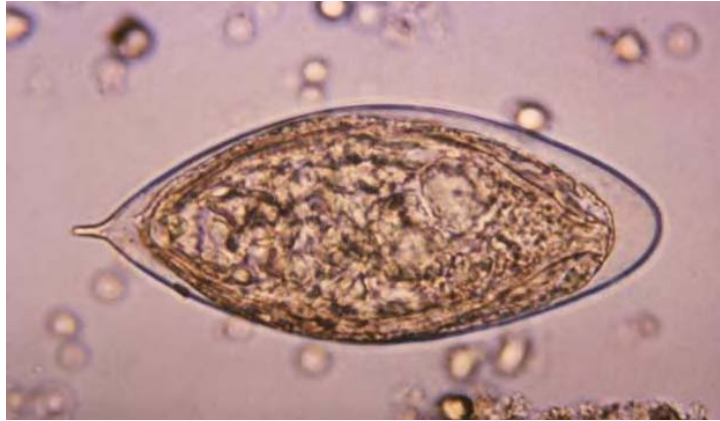


Image 6-9. *Schistosoma haematobium* eggs are elongated with a prominent terminal spine. The larva inside the egg produces an enzyme that passes through the egg-shell. (SOURCE: PHIL 4843 – CDC)

Clinical Disease

The clinical disease is related to the stage of infection, previous host exposure, worm burden and host response. Cercarial dermatitis (Swimmer's Itch) following skin penetration, results in a maculopapular rash and can last 36 hours or more. The mature flukes of *S. haematobium* migrate to the veins surrounding the bladder. After mating, the eggs are laid in the venules of the bladder and many penetrate through the mucosa, enter the lumen of the bladder and are excreted in the urine accompanied by blood. Thus hematuria and proteinuria are characteristic, though not invariable features of urinary schistosomiasis.

As with all *Schistosoma* species, it is the eggs and not the adult worms which are responsible for the pathology associated with *S. haematobium*. In chronic disease, eggs become trapped in the bladder wall resulting in the formation of granulomata. Following prolonged infection, the ureters may become obstructed and the bladder becomes thickened resulting in abnormal bladder function, urinary infection and kidney damage. Chronic urinary schistosomiasis is associated with squamous cell bladder cancer. Heavy infections in males may involve the penis resulting in scrotal lymphatics being blocked by the eggs.

Laboratory Diagnosis

The definitive diagnosis of urinary schistosomiasis is made by finding the characteristic ova of *S. haematobium* in urine. Terminal urine should be collected as the terminal drops contain a large proportion of the eggs. The urine can either be centrifuged and the deposit examined microscopically for ova. Eggs can sometimes be found in seminal fluid in males.

A bladder biopsy is seldom necessary to make the diagnosis. A rectal snip may show the presence of ova as they sometimes pass into the rectal mucosa.

Serological tests can be of value when eggs cannot be found in clinical samples. An enzyme linked immunosorbent assay using soluble egg antigen to detect antischistosome antibody is most sensitive.

There is a marked periodicity associated with the time when most eggs are passed out. Higher numbers of eggs are encountered in urine specimens passed between 1000 and 1400 hours, presumably as a result of changes in the host's metabolic and physical activities.

Chapter 7.

Tissue Dwelling Nematodes

7.1 Unusual Tissue Dwelling Nematodes

Many species of nematodes are known to indirectly infect man causing an array of symptoms and diseases. Many of the larvae of these parasites cause serious zoonosis in man. These parasites are known to infect many intermediate hosts during their life cycle with a variety of animals being the definitive host, while man is normally an accidental definitive host.

Angiostrongylus (Parastrongylus) cantonensis

Introduction

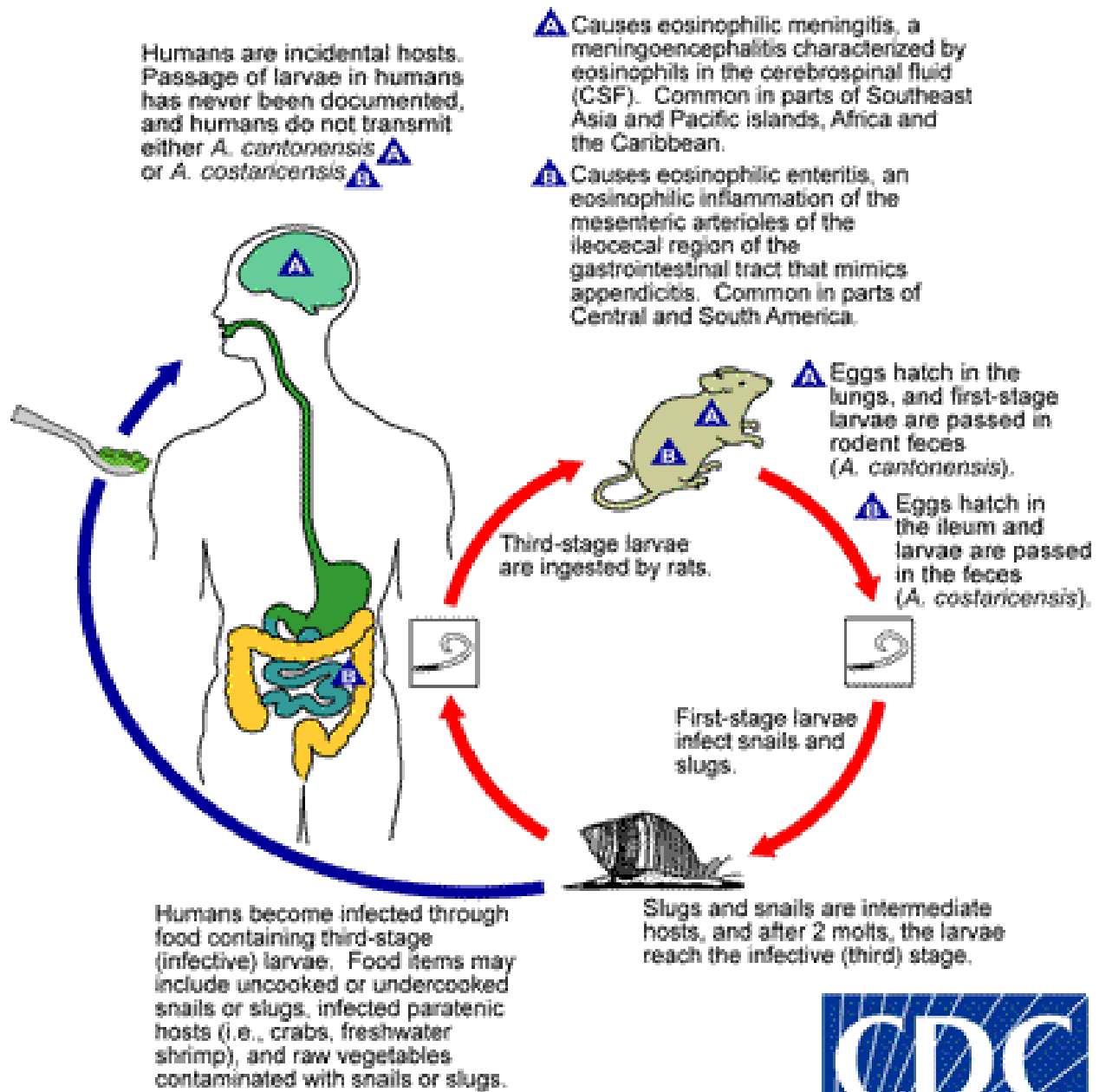
Angiostrongylus cantonensis was first described in 1944 in Taiwan from a boy with suspected meningitis. Since then it has been recognized throughout the Pacific areas with sporadic cases reported in other parts of the world including Central America and Cuba. It is associated with eosinophilic meningitis. The species *A. cantonensis* and *A. costaricensis* have now been reclassified into the genus *Parastrongylus*.

Angiostrongylus cantonensis is also known as the rat nematode where the main cause of eosinophilic meningitis is infection with the larvae of this nematode. Man and rats become infected by eating infected mollusks of the giant land snail (intermediate hosts) or food which is contaminated by the snails' bodies.

Life Cycle and Transmission

Adult worms of *A. cantonensis* live in the pulmonary arteries of rats. The females lay eggs that hatch, yielding first-stage larvae, in the terminal branches of the pulmonary arteries. The first-stage larvae migrate to the pharynx, are swallowed, and passed in the feces. They penetrate, or are ingested by, an intermediate host (snail or slug). After two molts, third-stage larvae are produced, which are infective to mammalian hosts. When the mollusk is ingested by the definitive host, the third-stage larvae migrate to the brain where they develop into young adults. The young adults return to the venous system and then the pulmonary arteries where they become sexually mature. Of note, various animals act as paratenic (transport) hosts: after ingesting the infected snails, they carry the third-stage larvae which can resume their development when the paratenic host is ingested by a definitive host. Humans can acquire the infection by eating raw or undercooked snails or slugs infected with the parasite; they may also

acquire the infection by eating raw produce that contains a small snail or slug, or part of one. There is some question whether or not larvae can exit the infected mollusks in slime (which may be infective to humans if ingested, for example, on produce). The disease can also be acquired by ingestion of contaminated or infected paratenic animals (crabs, freshwater shrimp). In humans, juvenile worms migrate to the brain, or rarely in the lungs, where the worms ultimately die. The life cycle of *Angiostrongylus (Parastrongylus) costaricensis* is similar, except that the adult worms reside in the arterioles of the ileocecal area of the definitive host. In humans, *A. costaricensis* often reaches sexual maturity and release eggs into the intestinal tissues. The eggs and larvae degenerate and cause intense local inflammatory reactions and do not appear to be shed in the stool.



SAFER • HEALTHIER • PEOPLE™
<http://www.dpd.cdc.gov/dpdx>

Illustration 7-1. Life cycle of the rat nematode *Angiostrongylus cantonensis*. Adult worms of *A. cantonensis* live in the pulmonary arteries of rats. The females lay eggs that hatch, yielding first-stage larvae, in the terminal branches of the pulmonary arteries. The first-stage larvae migrate to the pharynx, are swallowed, and passed in the feces. They penetrate, or are ingested by, an intermediate host (snail or slug). After two molts, third-stage larvae are produced, which are infective to mammalian hosts. When the mollusk is ingested by the definitive host, the third-stage larvae migrate to the brain where they develop into young adults. The young adults return to the venous system and then the pulmonary arteries where they become sexually mature. Of note, various animals act as paratenic (transport) hosts: after ingesting the infected snails, they carry the third-stage larvae which can resume their development when the paratenic host is ingested by a definitive host. Humans can acquire the infection by eating raw or undercooked snails or slugs infected with the parasite; they may also acquire the infection by eating raw produce that contains a small snail or slug, or part of one. There is some question whether or not larvae can exit the infected mollusks in slime (which may be infective to humans if ingested, for example, on produce). The disease can also be acquired by ingestion of contaminated or infected paratenic animals (crabs, freshwater shrimps). In humans, juvenile worms migrate to the brain, or rarely in the lungs, where the worms ultimately die. The life cycle of *Angiostrongylus (Parastrongylus) costaricensis* is similar, except that the adult worms reside in the arterioles of the ileocecal area of the definitive host. In humans, *A. costaricensis* often reaches sexual maturity and release eggs into the intestinal tissues. The eggs and larvae degenerate and cause intense local inflammatory reactions and do not appear to be shed in the stool. (SOURCE: CDC)

Morphology

Angiostrongylus cantonensis is a long slender worm measuring between 17 and 25 μm long by 0.26 to 0.34 μm wide.

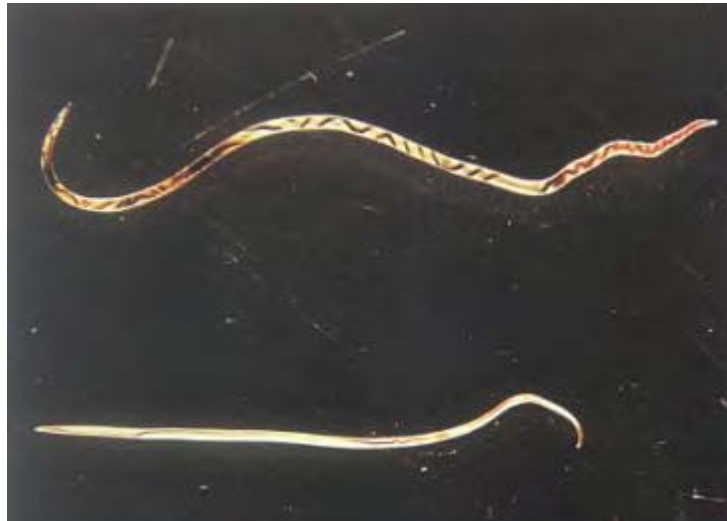

Image 7-1. The adult worms of *Angiostrongylus cantonensis*. They measure between 17–25 μm long and reside in the pulmonary arteries and arterioles of the definitive hosts. (x 3.5) (SOURCE: CDC)

Symptoms

The incubation period is usually about 20 days but can be up to 47 days. Infection in man is usually self-limiting but can result in fatalities. The main symptom is severe headache but other symptoms include convulsions, vomiting, facial paralyses, paresthesia, neck stiffness

and fever. It is accompanied by moderate eosinophilia in the CSF (i.e. the cell count is 100 – 2000/ μm^3). Blood eosinophilia is also common. Eye involvement is accompanied by visual impairment, ocular pain, keratitis and retinal edema. Living worms have been reported and are removed surgically.

Laboratory Diagnosis

Presumptive diagnosis can be made on the basis of the patients' symptoms (i.e. fever, meningitis, ocular involvement and severe headache). Eosinophilia in CSF and peripheral blood is also suggestive. Larvae or young adults can be recovered in the CSF. ELISA methods can also provide confirmation.

Angiostrongylus (Parastrongylus) costaricensis

Introduction

Angiostrongylus costaricensis was first described in 1971. Human infections are most common in Costa Rica but have been reported in Mexico, Central and South America.

Life Cycle

The life cycle is similar to *A. cantonensis*, (above) with the human being an *accidental* host by consumption of snails and salad vegetables which have become contaminated by infective larvae that have been shed by slugs in their mucus. Unlike *A. cantonensis*, the larvae of *A. costaricensis* penetrates the intestinal wall and results in inflammatory lesions of the bowel wall. Here the life cycle ends.

Morphology

The eggs are 90 μm , oval, thin shelled and can be embryonated. The adult female measures 42 x 300 μm and the males measure 22 x 140 μm .

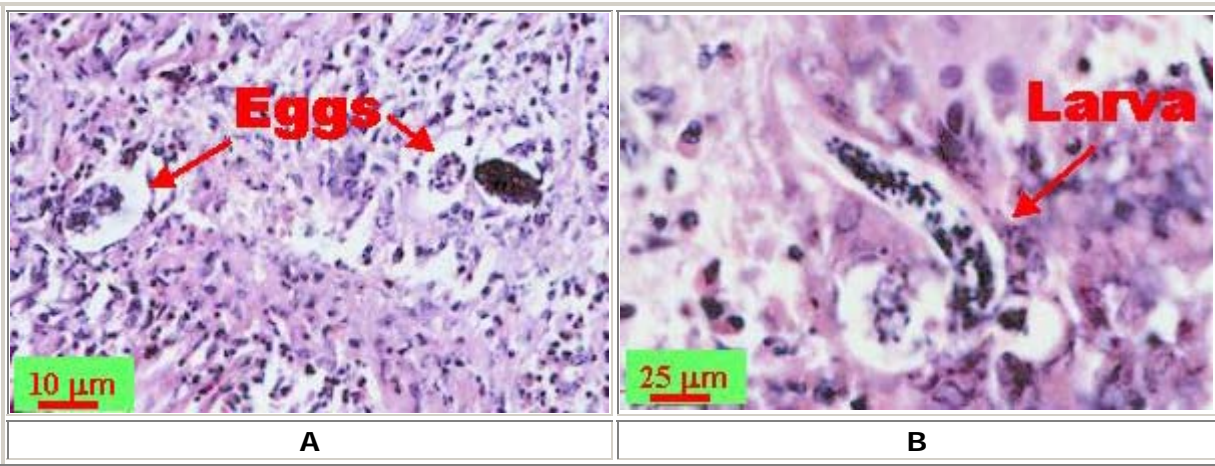


Image 7-2. **A:** Eggs of *Angiostrongylus costaricensis*. **B:** Larva of *A. costaricensis*. In humans, eggs and larvae are not normally excreted, but remain sequestered in tissues. Both eggs and larvae (occasionally adult worms) of *A. costaricensis* can be identified in biopsy or surgical specimens of intestinal tissue. The larvae need to be distinguished from larvae of *Strongyloides stercoralis*; however, the presence of granulomas containing thin shelled eggs and/or larvae serve to distinguish *A. costaricensis* infections. (SOURCE: CDC)

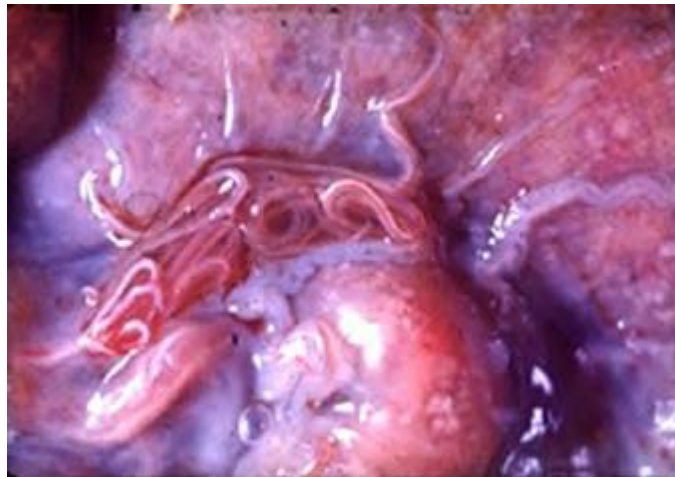


Image 7-3. Picture showing the adult *Angiostrongylus costaricensis* worms in the natural host of a rat. The worms normally localize within the mesenteric arteries, especially those of the ileocecal region of the natural definitive host. (SOURCE: CDC)

Clinical Disease

The most common symptoms are pain and tenderness with fever, vomiting and diarrhea. A tumor-like mass is often palpable and can mimic malignancy. The symptoms of abdominal pain, vomiting and diarrhea, and anorexia, are often mistaken for those of appendicitis. Worms can be found in the regional lymph nodes and mesenteric arteries. They can also be found in the spermatic arteries causing testicular obstruction and necrosis. Occasionally the larvae and the ova reach the liver and symptoms may mimic visceral larvae migrans. Eosinophilia is also present.

Anisakiasis

Introduction

Anisakiasis is a collective name for infections belonging to the genera of nematodes, *Anisakis*, *Phokanema*, *Terranova* and *Contracaecum*. The adult worms from the many species belonging to this family, *Anisakidae*, occur in various sea mammals, seals, dolphins, porpoises and whales, the larvae can cause a serious zoonosis, *anisakiasis*, in man. Anisakiasis was first reported in the Netherlands in 1960 and since then cases have been reported from Japan, North America, Canada, Chile, and the United Kingdom with the increase in popularity of 'sushi'.

Two species of nematode have been especially implicated worldwide in causing human anisakiasis, *Anisakis simplex* and *Pseudoterranova osculatum*. The larvae of *P. osculatum* can be distinguished from *A. simplex* by the possession of a cecum.

Life Cycle

These nematodes are parasites in a large number of marine animals including seals, sea-lions, whales, and dolphins. It is in these mammals that the adult worm is found. Eggs are passed out in the feces of these mammals, they embryonate and hatch to liberate the first stage larvae into the sea water. These larvae then become ingested by crustaceans and molt to become L₂ and L₃ larvae. If fish and squid eat the infected crustaceans, the third stage larvae become liberated and penetrate the intestine or muscles of that host. These larvae then encyst. Over 100 species of fish can act as intermediate hosts. The marine mammals ingest the fish and thus the cycle is completed.

Humans become infected by consuming raw or improperly cooked fish which contain the third stage larvae.

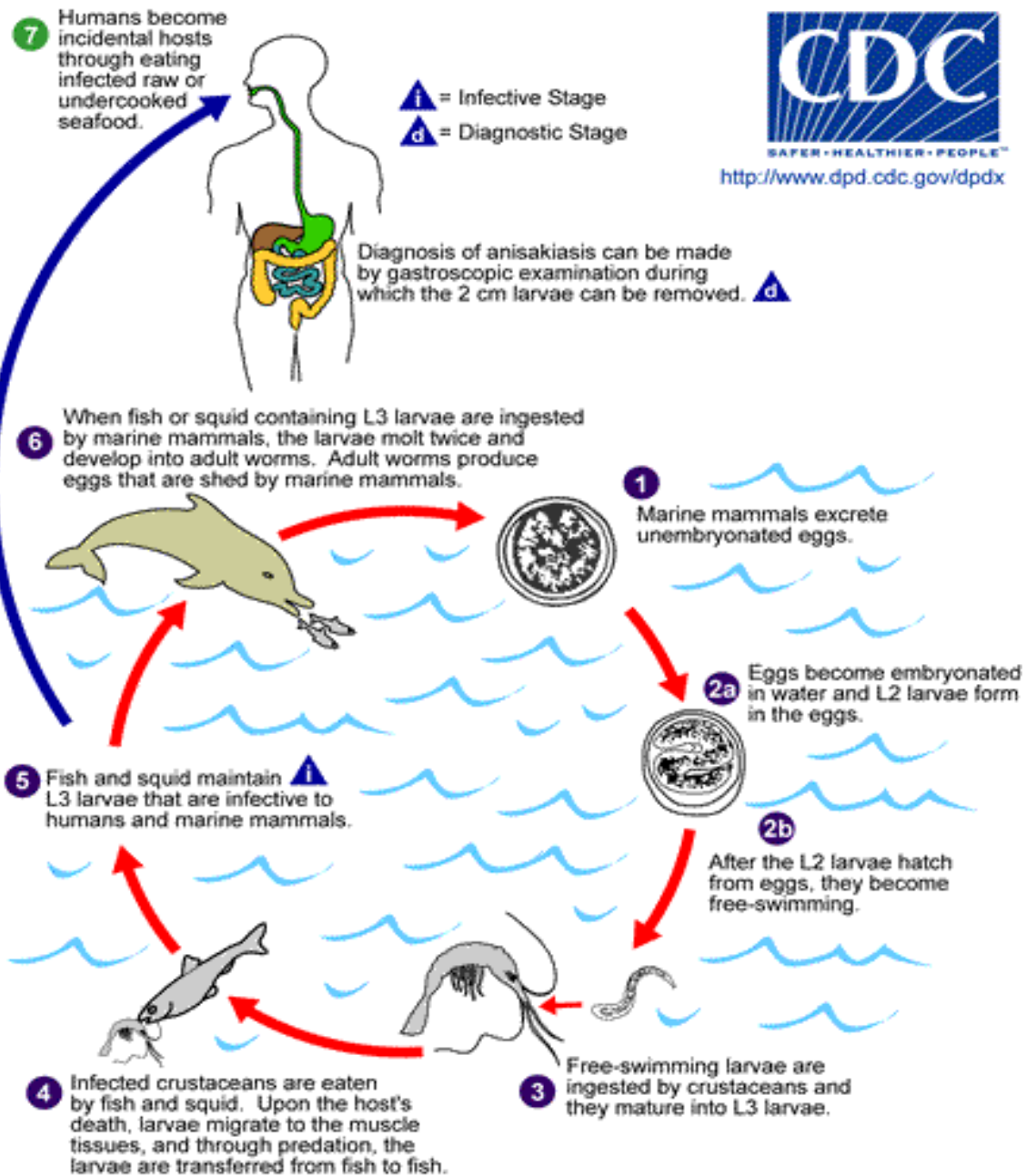


Illustration 7-2. Adult stages of *Anisakis simplex* or *Pseudoterranova decipiens* reside in the stomach of marine mammals, where they are embedded in the mucosa, in clusters. Unembryonated eggs produced by adult females are passed in the feces of marine mammals **1**. The eggs become embryonated in water, and first-stage larvae are formed in the eggs. The larvae molt, becoming second-stage larvae **2a**, and after the larvae hatch from the eggs, they become free-swimming **2b**. Larvae released from the eggs are ingested by crustaceans **3**. The ingested larvae develop into third-stage larvae that are infective to fish and squid **4**. The larvae migrate from the intestine to the tissues in the peritoneal cavity and grow up to 3 cm in length. Upon the host's death, larvae migrate to the muscle tissues, and through predation, the larvae are transferred from fish to fish. Fish and squid maintain third-stage larvae that are infective to humans and marine mammals **5**. When fish or squid containing third-stage larvae are ingested by marine mammals, the larvae molt twice and develop into adult worms. The adult females produce eggs that are shed by marine mammals **6**. Humans become infected by eating raw or undercooked infected marine fish **7**. After ingestion, the anisakid larvae penetrate the gastric and intestinal mucosa, causing the symptoms of anisakiasis. (SOURCE: CDC)

Morphology

The larvae reach a length of 50µm with a diameter of 1-2µm. Classification of the Anisakids is made by the structure of the digestive tract.

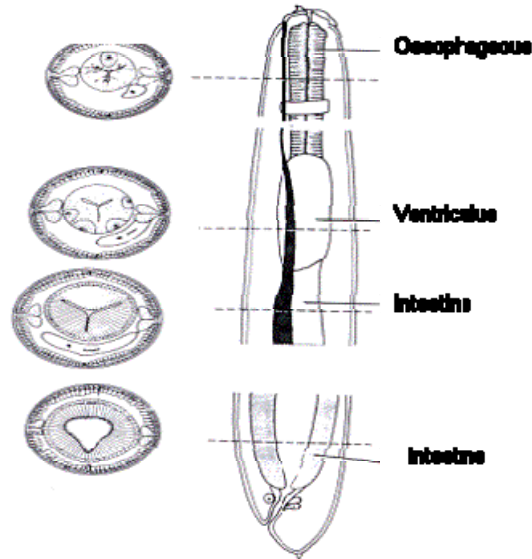


Illustration 7-3. Line diagram representing the morphology of the third stage larvae of *Anisakis simplex* (from fish), it is the causative organism of *anisakiasis* in man. (SOURCE: Smyth, J.D, 1994)

Clinical Disease

After ingestion of the raw fish by humans, the larvae penetrate the intestinal wall resulting in inhabitation of the stomach or duodenum, but can be found in any part of the alimentary canal or outside the gut in various viscera. The end result is abdominal pain, nausea, and sometimes vomiting and diarrhea, often occurring within 6 hours of eating an infected meal. Abdominal irritation may mimic gastric ulcer, carcinoma, appendicitis or other conditions requiring surgery. Eosinophilic granulosis may result.

Transient anisakiasis which has been reported in North America is characterized by some vomiting and distress within a few hours of ingesting the fish and then quickly subsides. The larvae can be coughed up a few days later. Low grade eosinophilia and occult blood in the stool are common.

Laboratory Diagnosis

Diagnosis can only be confirmed by endoscopy and the removal of the worms by biopsy forceps and microscopic identification.

Epidemiology and Prevention

Anisakis larvae are usually found in herring, mackerel, and North American salmon. *Pseudoterranova* are found in cod, halibut, rockfish, sardines, and squid.

Human infections result from eating raw fish, insufficiently cooked or smoked fish, marinated or salted fish. Freezing fish at -20°C (-4°F) for a minimum of five days kills the larvae and thus the fish is suitable for consumption in dishes like sushi. Smoking the fish at temperatures >65°C (149°F) renders it suitable for consumption. Marinating or salting the fish cannot be depended upon to kill the larvae, however adequately cleaning the fish can render it safe for consumption. Human anisakiasis has been virtually eliminated from the Netherlands due to the mandatory freezing of herring.

Gnathostoma spinigerum

Introduction

Several species of the genus *Gnathostoma* are responsible for zoonotic infections in man. *Gnathostoma spinigerum* is a nematode found in dogs, cats, and several other carnivores. Human infections of the disease have been reported from Japan, China, Thailand, the Far East, and the Philippines, with man acquiring the infection from eating various freshwater fish.

Life Cycle

The life cycle of this parasite involves two intermediate hosts, cyclops and birds, snakes, fish and frogs where they mature before developing into adults in the definitive hosts.

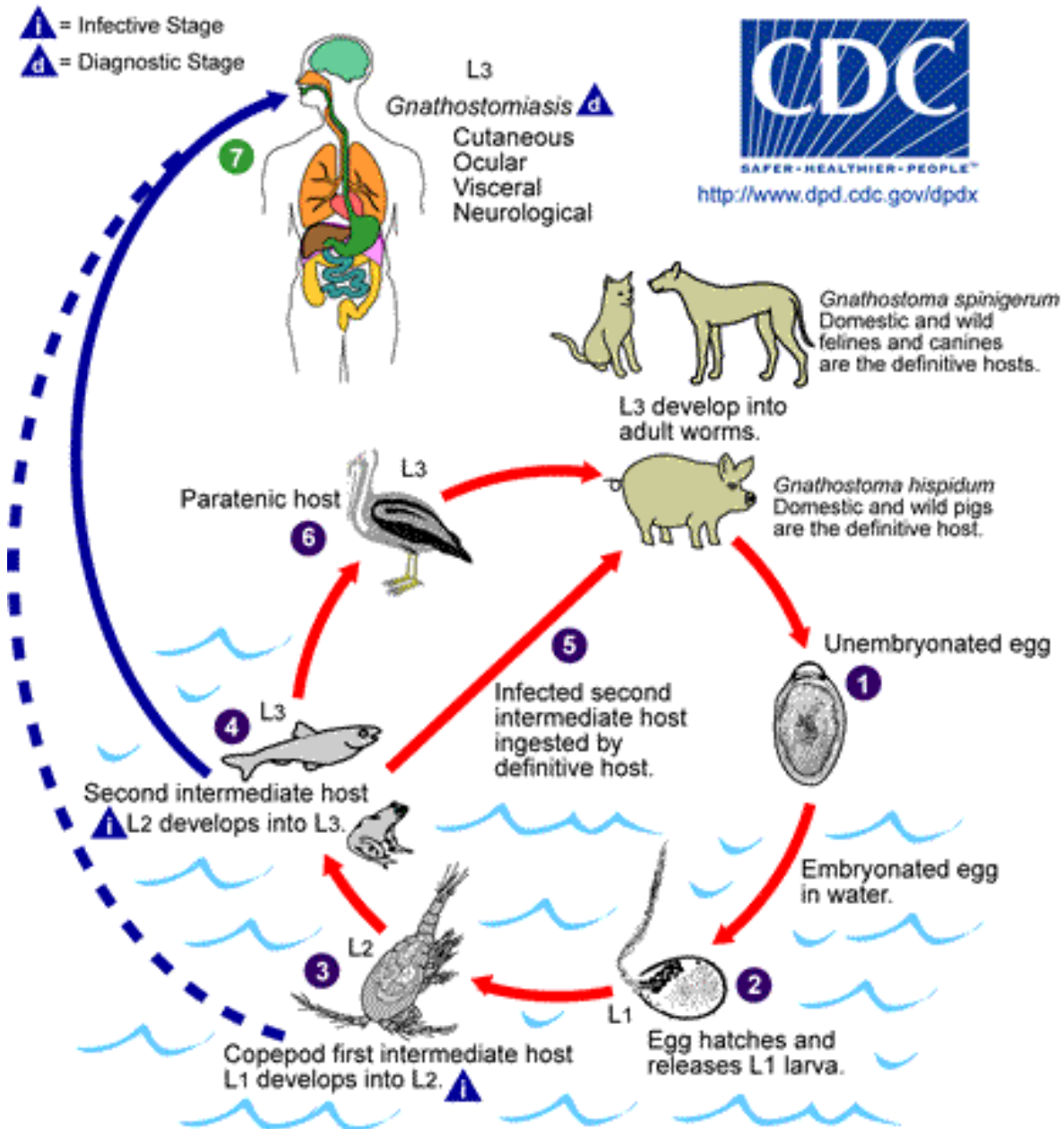


Illustration 7-4. Diagram illustrating the life cycle of *Gnathostoma spinigerum*. In the natural definitive host (pigs, cats, dogs, wild animals) the adult worms reside in a tumor which they induce in the gastric wall. They deposit eggs that are unembryonated when passed in the feces **1**. Eggs become embryonated in water, and eggs release first-stage larvae **2**. If ingested by a small crustacean (*Cyclops*, first intermediate host), the first-stage larvae develop into second-stage larvae **3**. Following ingestion of the *Cyclops* by a fish, frog, or snake (second intermediate host), the second-stage larvae migrate into the flesh and develop into third-stage larvae **4**. When the second intermediate host is ingested by a definitive host, the third-stage larvae develop into adult parasites in the stomach wall **5**. Alternatively, the second intermediate host may be ingested by the paratenic host (animals such as birds, snakes, and frogs) in which the third-stage larvae do not develop further but remain infective to the next predator **6**. Humans become infected by eating undercooked fish or poultry containing third-stage larvae, or reportedly by drinking water containing infective second-stage larvae in *Cyclops* **7**.

If the infected fish or frogs are eaten by other hosts, apart from the definitive hosts, (paratenic host), such as herons, pigs and man, they do not mature but migrate through the subcutaneous tissues causing visceral and cutaneous larva migrans.

Morphology

The adult female worms measure 25-54µm whereas the male measures 11-25µm. The anterior half of the worm is covered with leaf like spines. The male worms have a red tail while the larger females have a more curved tail. The larval worms are 4µm long.

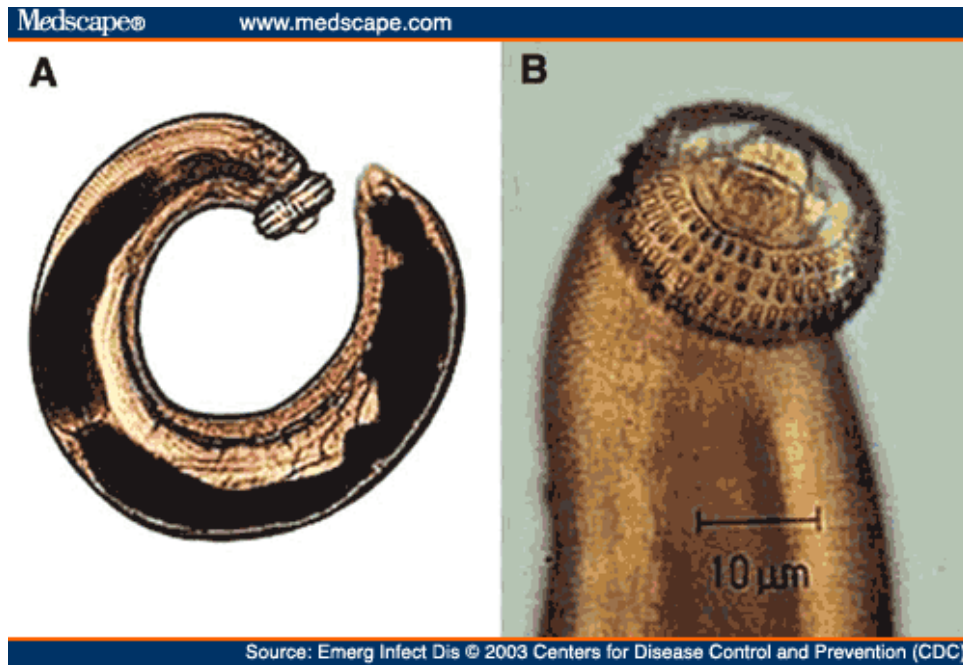


Image 7-4. Adult worms of *Gnathostoma spinigerum*. The males are smaller than the females and possess a red tail. (x 1.3) (SOURCE: CDC/Medscape)

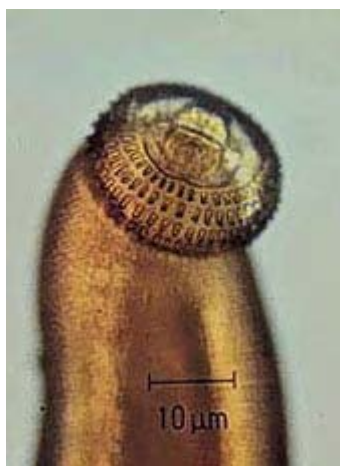

Image 7-5. Third stage larval Head of *Gnathostoma spinigerum*. (SOURCE: CDC/Medscape)

Clinical Disease

Humans are accidental hosts and after ingestion, the larvae do not mature but migrate throughout the body via the intestinal wall. Symptoms include epigastric pain, vomiting and anorexia. These symptoms subside as the larvae continue their migratory path through the cutaneous tissue. Evidence of migration appears as either lesions similar to cutaneous larvae migrans or migratory swellings accompanied by inflammation, redness or pain. The swelling is hard and non-pitted and lasts for several days. These migratory lesions may be accompanied by pruritis and pain. There is marked eosinophilia in patients with cutaneous involvement. Ocular involvement resulting in blindness may occur in serious disease. Eosinophilic myeloencephalitis may result from migration of the worms along the nerve tracks. Symptoms may include pain, paralyses, seizures, coma and death. The CSF may be xanthochromic (yellowish discoloration) or bloody.

Laboratory Diagnosis

Presumptive diagnosis may be made on the basis of clinical symptoms. Definitive diagnosis is the recovery and identification of the worm since the symptoms may be suggestive of Sparganosis, paragonimiasis and cutaneous larvae migrans and myiasis. A bloody spinal fluid or xanthochromia may resemble infection with *Angiostrongylus cantonensis*.

Trichinella spiralis

Introduction

Trichinella spiralis was first seen by James Paget, but was named and described by his Professor, Richard Owen. The family Trichinellidae contains only one single genus; *Trichinella*, and was originally thought only to contain the one species; *Trichinella spiralis*, which causes the serious and often fatal disease in man known as *trichinosis* (Trichinellosis). It is a parasite of carnivorous animals and is especially common in rats and in swine fed on uncooked garbage and slaughter house scraps. Humans become infected by eating raw pork, with sausages being the most common cause of infection. It is a cosmopolitan parasite and is common in China, though prevalent in many European countries as well.

It is now thought that there are four varieties of this species that exists worldwide;

- *Trichinella spiralis spiralis* - Temperate zone – high infectivity for pigs, rats and man.
- *Trichinella spiralis nelsoni* - Tropics - low infectivity for pigs and rats and high infectivity for lions, hyenas.
- *Trichinella spiralis nativa* - Arctic - low infectivity for pigs, found in polar bears, resistant to freezing.
- *Trichinella spiralis pseudospiralis*- New Zealand – low infectivity for pigs, rats and mice.

Trichinella spiralis is a 'domestic' parasitic nematode long recognized to cause a zoonosis transmitted to man by the ingestion of infected pork.

Life Cycle

Infection in the definitive hosts is acquired by the hosts eating raw or undercooked flesh (e.g. pork, containing encapsulated larvae). Rats are probably the most highly infected 'natural' hosts and pigs become infected by eating infected pork scraps or occasionally rats which inhabit their stalls. For man, sausages are a dangerous source of the parasite as a small fragment of infected pork, (after mincing), may become widely distributed among a number of sausages.

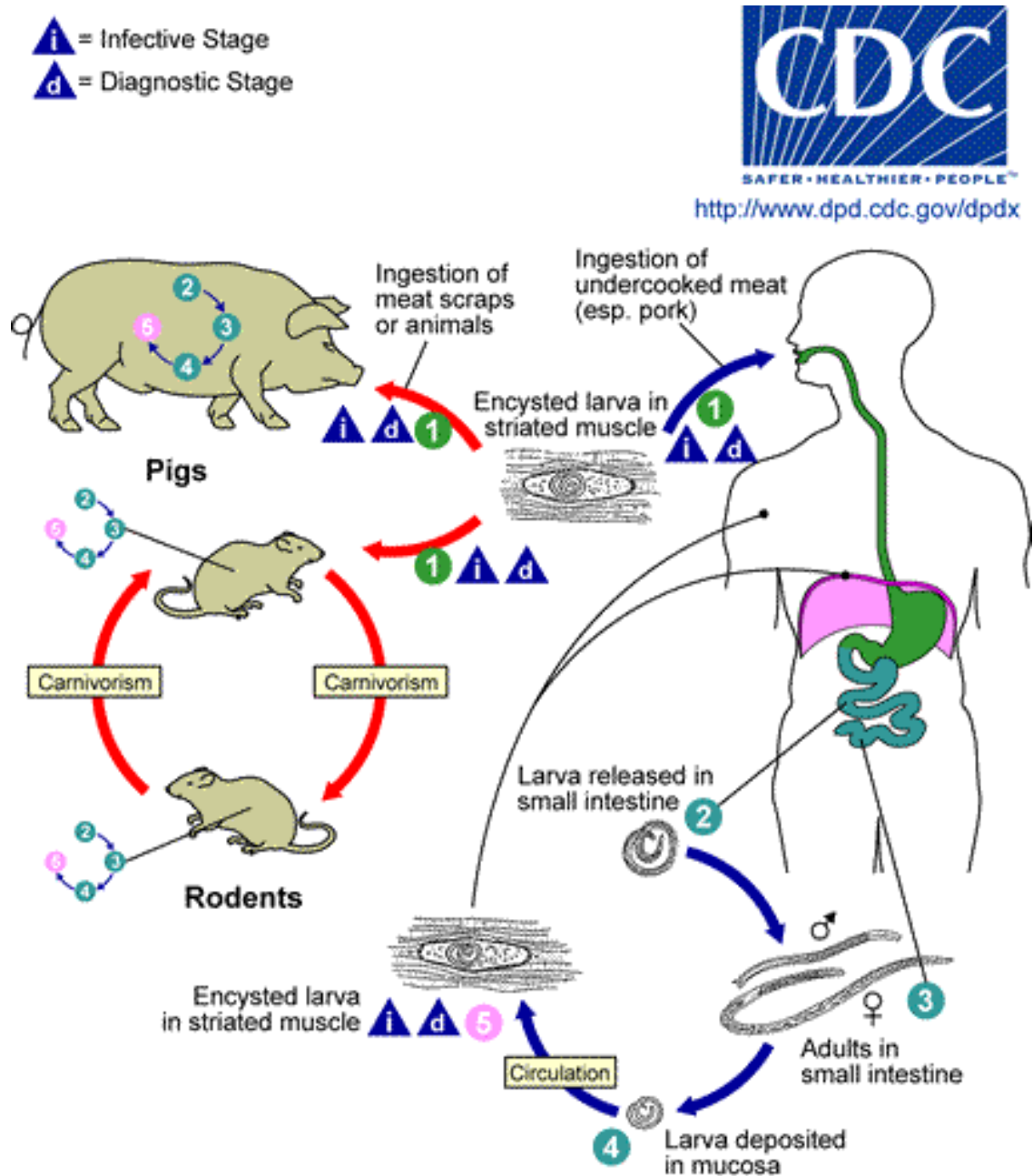


Illustration 7-5. The life cycle of *Trichinella spiralis*. Trichinellosis is acquired by ingesting meat containing cysts (encysted larvae) ① of *Trichinella*. After exposure to gastric acid and pepsin, the larvae are released ② from the cysts and invade the small bowel mucosa where

they develop into adult worms ³ (female 2.2 mm in length, males 1.2 mm; life span in the small bowel: four weeks). After one week, the females release larvae ⁴ that migrate to the striated muscles where they encyst ⁵. *Trichinella pseudospiralis*, however, does not encyst. Encystment is completed in 4 to 5 weeks and the encysted larvae may remain viable for several years. Ingestion of the encysted larvae perpetuates the cycle. Rats and rodents are primarily responsible for maintaining the endemicity of this infection. Carnivorous/omnivorous animals, such as pigs or bears, feed on infected rodents or meat from other animals. Different animal hosts are implicated in the life cycle of the different species of *Trichinella*. Humans are accidentally infected when eating improperly processed meat of these carnivorous animals (or eating food contaminated with such meat). (SOURCE: CDC/DPDx Trichinellosis)

Morphology

The adult female worm is about 2-3µm long and 90µm in diameter. The male is smaller measuring 1.2µm long by 60µm in diameter.

The female adult worms are ovoviparous (born alive from the mother but held as an unshelled egg internally until birth, after having no umbilical connection to the mother) and up to 1500 larvae may be released by a single worm.




Image 7-6. A, B: Larvae of *Trichinella*, freed from their cysts, typically coiled; length: 0.8 to 1.0 µm. Alaskan bear. (SOURCE: CDC)

Clinical Disease

Symptoms during the intestinal phase may go unnoticed or may be severe. Epidemics can result in outbreaks of gastro-enteritis, two to seven days after the ingestion of raw pork. Diarrhea with or without abdominal pain may last for several weeks. Eosinophilia and fever occur in most cases. Leukocytosis is common and hyperglobulinaemia (an autoimmune, chronic blood disease) is characteristic. Myocytosis and circum orbital edema are classic signs. There can also be central nervous system involvement

Pathogenicity

The primary pathogenic effect of *Trichinella* comes from the destruction of the striated muscle fibers in which it encysts. There can be neurological manifestations of trichinosis and death may be ascribed to myocarditis, encephalitis or pneumonitis.

Laboratory Diagnosis

Diagnosis of trichinosis depends on the clinical signs, such as myalgia, periorbital edema, fever and eosinophilia in a patient with a history of eating pork or sausages.

Serological tests are available but may be negative if carried out within three to four weeks post infection. Circulating antibodies to *T. spiralis* appear from two to four weeks after infection. Redefined diagnostic antigens for their detection are currently being developed. A simple IFAT employing fragments of larvae as antigen is a useful diagnostic tool. Latex tests with extracted larval antigens have also proved valuable in the acute stage, during which high antibody titers develop.

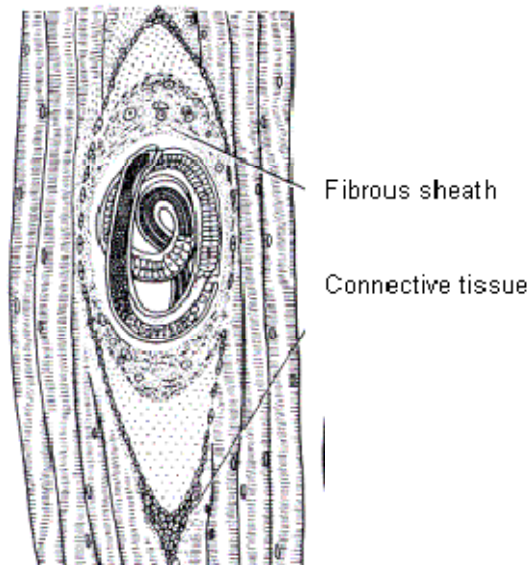


Illustration 7-6. Diagrammatic representation of the *Trichinella* larvae encapsulated in striated muscle. (SOURCE: Smyth, J.D, 1994)

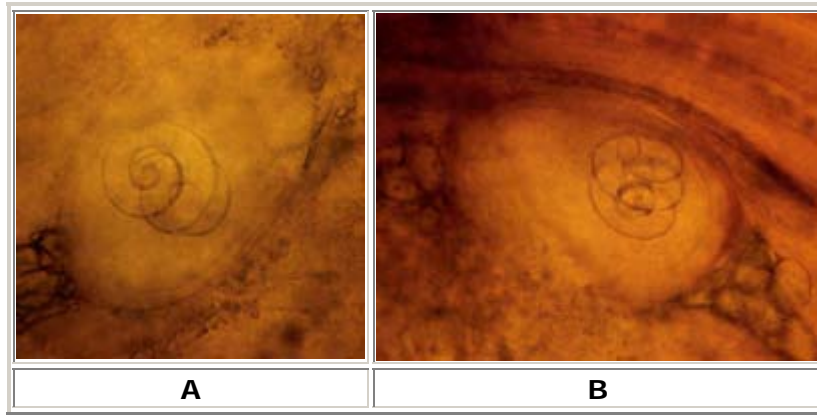


Image 7-7. A, B: Encysted larvae of *Trichinella* in pressed muscle tissue. The coiled larvae can be seen inside the cysts. (SOURCE: CDC)

Muscle biopsy is available with the muscle being digested in pepsin, which frees the encapsulated larvae or by a simple device whereby the muscle sample is compressed between two glass plates to make it semi-transparent, allowing you to see any encapsulated larvae using a 'trichinoscope' (a simple magnifying system).

Chapter 8.

Larval Cestodes and Nematodes which Infect Man

8.1 Larval Cestodes which Infect Man

Infections in man with *Echinococcus granulosus*, *Echinococcus multilocularis*, and *Multiceps multiceps* are caused by the accidental ingestion of eggs which are excreted by the definitive animal host. The disease that is produced due to the invasion of these parasites is caused by the larval stages or hydatid cyst, is known as hydatid disease or hydatidosis.

Echinococcus granulosus causes cystic echinococcosis, and is the form most frequently encountered; *E. multilocularis* causes alveolar echinococcosis; *E. vogeli* causes polycystic echinococcosis; and *E. oligarthrus* is an extremely rare cause of human echinococcosis.

Each cestode possesses an elongated tape-like body which lacks an alimentary canal. The adult tapeworms are strings of individuals having a complete set of reproductive organs (proglottids) in progressive degrees of sexual maturity and budding off from a body attached to the host tissue by a head or scolex.

The larval stage, show a wide variation being found in almost any organ of both vertebrate and invertebrate hosts.

Echinococcus granulosus

Introduction

Echinococcosis or Hydatid disease in man is caused by the larval stage of the dog tapeworm, *Echinococcus granulosus*. Hydatid disease is most extensively found in East Africa, North Africa, South Africa, the Middle East, and parts of South America, and Australia. The intermediate hosts are cattle, sheep, pigs, goats, or camels and the definitive host for this disease is the dog or other canids.

Life Cycle

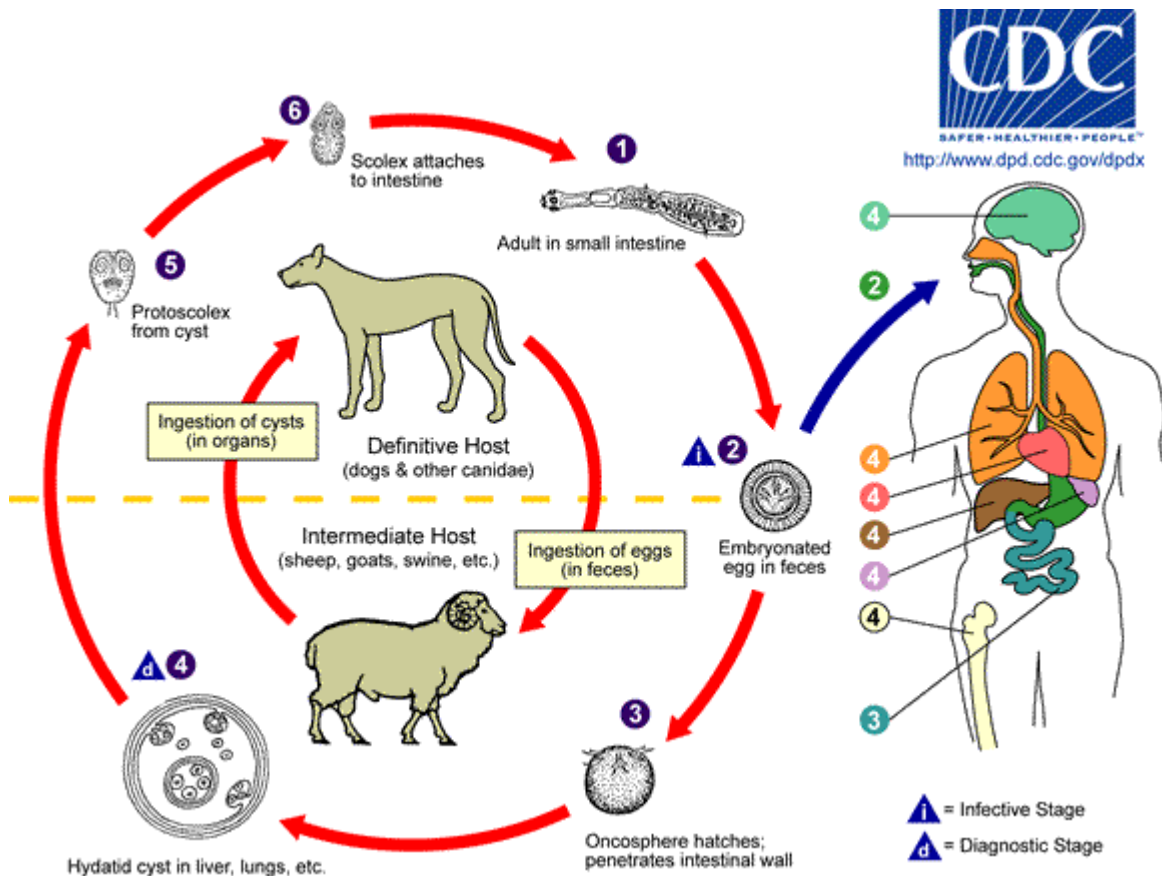


Illustration 8-1. Life Cycle of *Echinococcus granulosus*. The adult *Echinococcus granulosus* (3 to 6 mm long) **1** resides in the small bowel of the definitive hosts, dogs or other canids. Gravid proglottids release eggs **2** that are passed in the feces. After ingestion by a suitable intermediate host (under natural conditions: sheep, goat, swine, cattle, horses, camel), the egg hatches in the small bowel and releases an oncosphere **3** that penetrates the intestinal wall and migrates through the circulatory system into various organs, especially the liver and lungs. In these organs, the oncosphere develops into a cyst **4** that enlarges gradually, producing protoscolices and daughter cysts that fill the cyst interior. The definitive host becomes infected by ingesting the cyst-containing organs of the infected intermediate host. After ingestion, the protoscolices **5** evaginate, attach to the intestinal mucosa **6**, and develop into adult stages **1** in 32 to 80 days. The same life cycle occurs with *E. multilocularis* (1.2 to 3.7 mm), with the following differences: the definitive hosts are foxes, and to a lesser extent dogs, cats, coyotes and wolves; the intermediate host are small rodents; and larval growth (in the liver) remains indefinitely in the proliferative stage, resulting in invasion of the surrounding tissues. With *E. vogeli* (up to 5.6 mm long), the definitive hosts are bush dogs and dogs; the intermediate hosts are rodents; and the larval stage (in the liver, lungs and other organs) develops both externally and internally, resulting in multiple vesicles. *E. oligarthrus* (up to 2.9 mm long) has a life cycle that involves wild felids as definitive hosts and rodents as intermediate hosts. Humans become infected by ingesting eggs **2**, with resulting release of oncospheres **3** in the intestine and the development of cysts **4, 4, 4, 4, 4, 4** in various organs. (SOURCE: CDC/DPDx Echinococcus)

Morphology

The adult worm measures approximately 3–8.5µm long. The scolex has four suckers and a rostellum with hooks, the latter becoming tightly inserted into the crypts of Lieberkühn. The mature strobila has only 3–4 proglottids, one is immature, one is mature and the final one is gravid; when gravid the eggs are expelled in the feces.

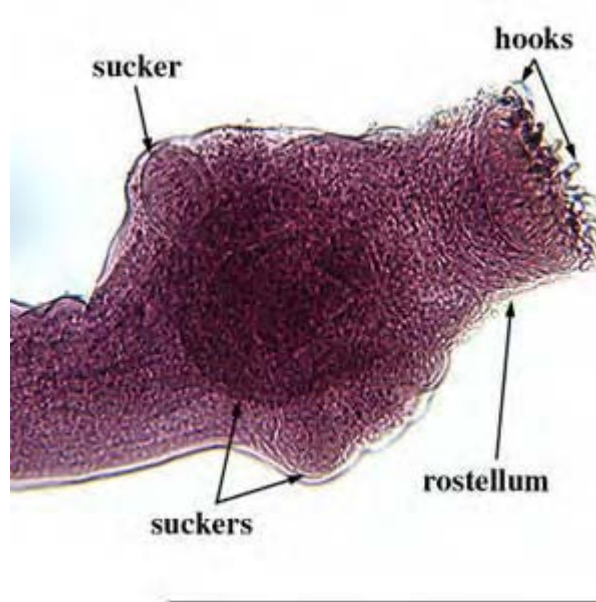


Image 8-1. *Echinococcus granulosus* scolex. (SOURCE: CDC)

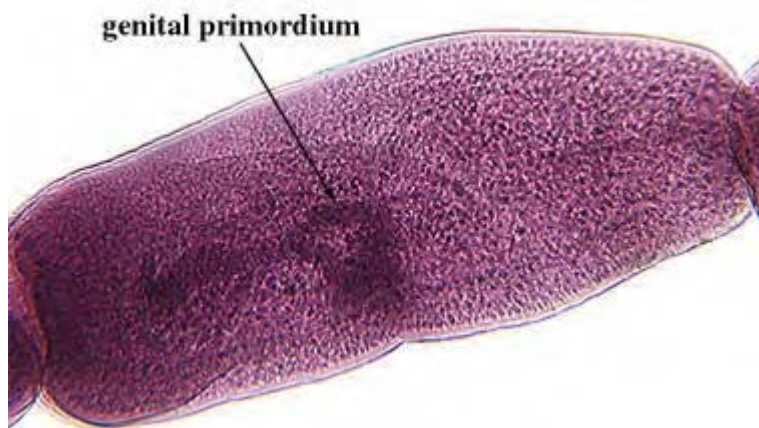


Image 8-2. *Echinococcus granulosus* immature proglottid. (SOURCE: CDC)

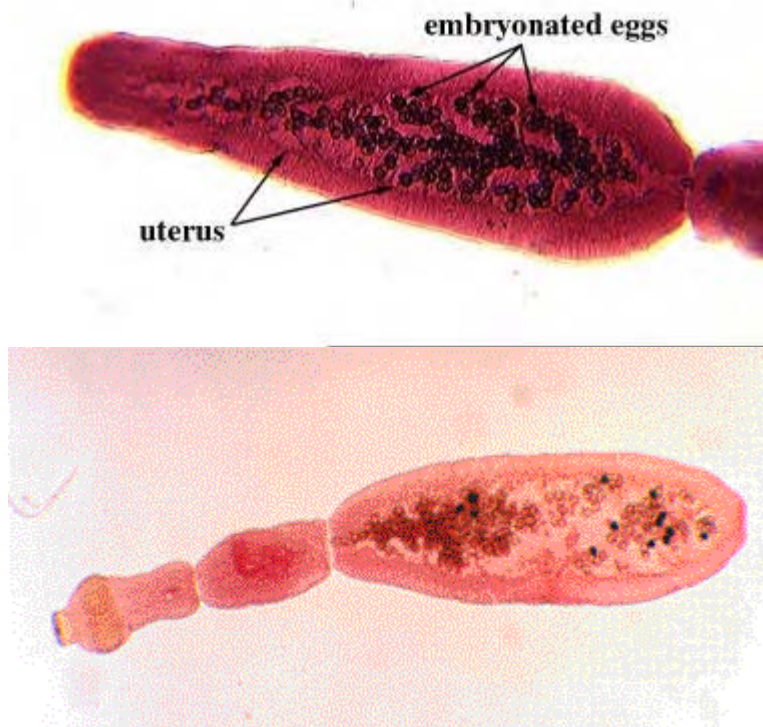


Image 8-3. Adult female worms of *Echinococcus granulosus* with gravid proglottids. (SOURCE: CDC)

Due to the close similarity of the eggs to other *Taenia* species found in dogs they were until recently thought to be morphologically indistinguishable.

The larvae in man develop into a unilocular cyst which gives rise to unilocular hydatid disease. This is characterized as having only one bladder or many completely isolated bladders, each enclosed in its own well-developed envelope. The latter consists of several layers, the most prominent being the laminated layer. Within this again is the germinal membrane from which the brood capsules arise inside which develop thousands of larvae or protoscoleces, the whole being suspended in a hydatid fluid.



Image 8-4. Unilocular cyst of *Echinococcus granulosus*. This is characterized as having only one bladder or many completely isolated bladders, each enclosed in its own well-developed envelope. Inside which develop thousands of larvae or protoscoleces, the whole being suspended in a hydatid fluid. These cysts in man give rise to unilocular hydatid disease.

Clinical Disease

Hydatid disease in humans is potentially dangerous depending on the location of the cyst. Some cysts may remain undetected for many years until they become large enough to affect other organs. Symptoms are then of a space occupying lesion. Lung cysts are usually asymptomatic until there is a cough, shortness of breath or chest pain. Hepatic cysts result in pressure on the major bile ducts or blood vessels. Expanding hydatid cysts cause necrosis of the surrounding tissue.

Slow leakage of the hydatid fluid results in eosinophilia and rupture of an abdominal hydatid cyst results in severe allergic symptoms.

Symptoms may not manifest themselves for five to 20 years after the infection.

Laboratory Diagnosis

1. Imaging and serodiagnosis are the mainstay of diagnosis. Serological tests include Enzyme linked immunosorbent assay (ELISA), an indirect hemagglutination test a complement fixation test and a Western Blot system.
2. Microscopic examination of the cyst fluid to look for the characteristic protoscoleces which can be either invaginated or evaginated. The cyst fluid will also reveal free hooklets and tissue debris. One percent eosin may be added to the fluid to determine the viability of the protoscoleces. Viable protoscoleces exclude eosin whereas nonviable protoscoleces take up the eosin.
3. Histological examination of the cyst wall after surgical removal.

Western Blots

One serological test which has proved to be of value to diagnosing Hydatid disease is the Western Blot. The test presents a definitive means for detection of human antibodies to the cestode *E. granulosus*.

Diagnosis can be achieved using the Western Blot assay for the detection of IgG antibodies in serum reactive with *E. granulosus* antigens present on a membrane. Field studies support a sensitivity of 80% and specificity of 100% in patients with hepatic cysts.

This assay is known as the Qualicode™ Hydatid Disease Kit; the principle behind the test is that it is a qualitative membrane-based immunoassay manufactured from *E. granulosus* proteins. The *E. granulosus* proteins are fractionated according to molecular weight by electrophoresis on a polyacrylamide slab gel (PAGE) in the presence of sodium dodecyl sulfate (SDS). The separated *E. granulosus* proteins are then transferred via electrophoretic blotting from the gel into strips for testing of individual samples.

During the procedure, the strips containing the *E. granulosus* proteins are incubated with serum specimens and washed to remove unbound antibodies.

Visualization of human immunoglobulins specifically bound to *E. granulosus* proteins is performed by sequential reaction with goat anti-human immunoglobulin-alkaline phosphatase conjugate and BCIP/NBT substrate. Bands corresponding to the positions of the resolved *E. granulosus* proteins will be visualized on the strip, indicating the presence in the serum sample of IgG antibodies directed against *E. granulosus* antigens. Band positions are compared to those on a reference strip developed using the Hydatid disease positive control.

Prevention

- Safe disposal of dog feces.
- Education to prevent feeding uncooked offal to dogs.

Echinococcus multilocularis

Introduction

The larvae of *Echinococcus multilocularis* is a particularly dangerous species causing multilocular (alveolar) hydatid disease in man and animals and is common in the highlands of Europe i.e. Switzerland and Germany, in Canada, Alaska and Northern Russia. The most common definitive hosts are foxes and wolves in addition to domestic cats and dogs when they have access to infected rodents.

Life Cycle

Foxes (1) are the primary definitive hosts although in domestic circumstances dogs (1a) and cats (1b) can act as the definitive host. Rodents (4) are the intermediate hosts. Man (4a) is an accidental host by the ingestion of eggs (2) where multilocular cysts are formed (3). In these cysts, the limiting membrane is thin and the germinal epithelium may bud off externally resulting in proliferation in any direction (5). Metastases may occur. Unlike *E. granulosus*, there is little fluid in the cysts of *E. multilocularis*.

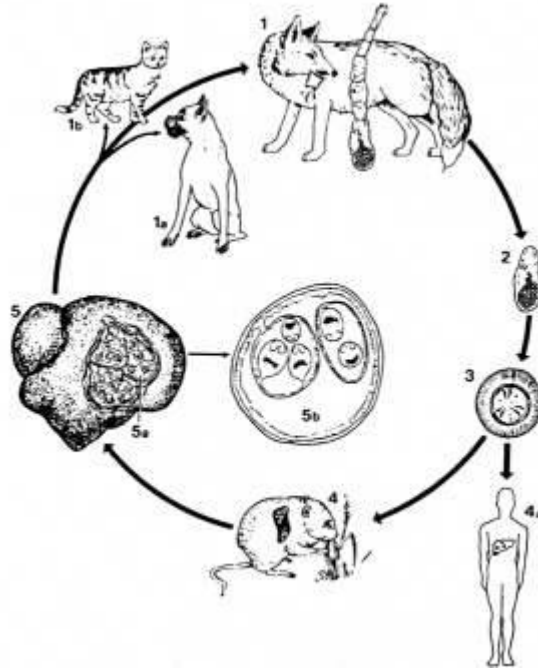


Illustration 8-3: Life cycle of *Echinococcus multilocularis*. (SOURCE: Unknown)

Morphology

Larvae - The larval *E. multilocularis* is very different from that of *E. granulosus*. In this case the 'cyst' grows invasively by external budding, forming a diffuse growth through the infected organ, replacing that organ's tissues. The growth itself, (it cannot truly be called a cyst as there is no real cyst wall), is composed of numerous cavities containing a gelatinous matrix within which protoscolices and numerous brood capsules are produced, and which in its behavior, most closely resembles a malignant neoplasm. In contrast to *E. granulosus* this growth is also very rapid. Infective protoscolices being present after only two to three months, as compared to the one to two years in the related metacestode.

Adults - The adult parasite is very similar to *E. granulosus*, being slightly smaller, with a maximum length of approximately 4µm, and consisting of four to five proglottids.

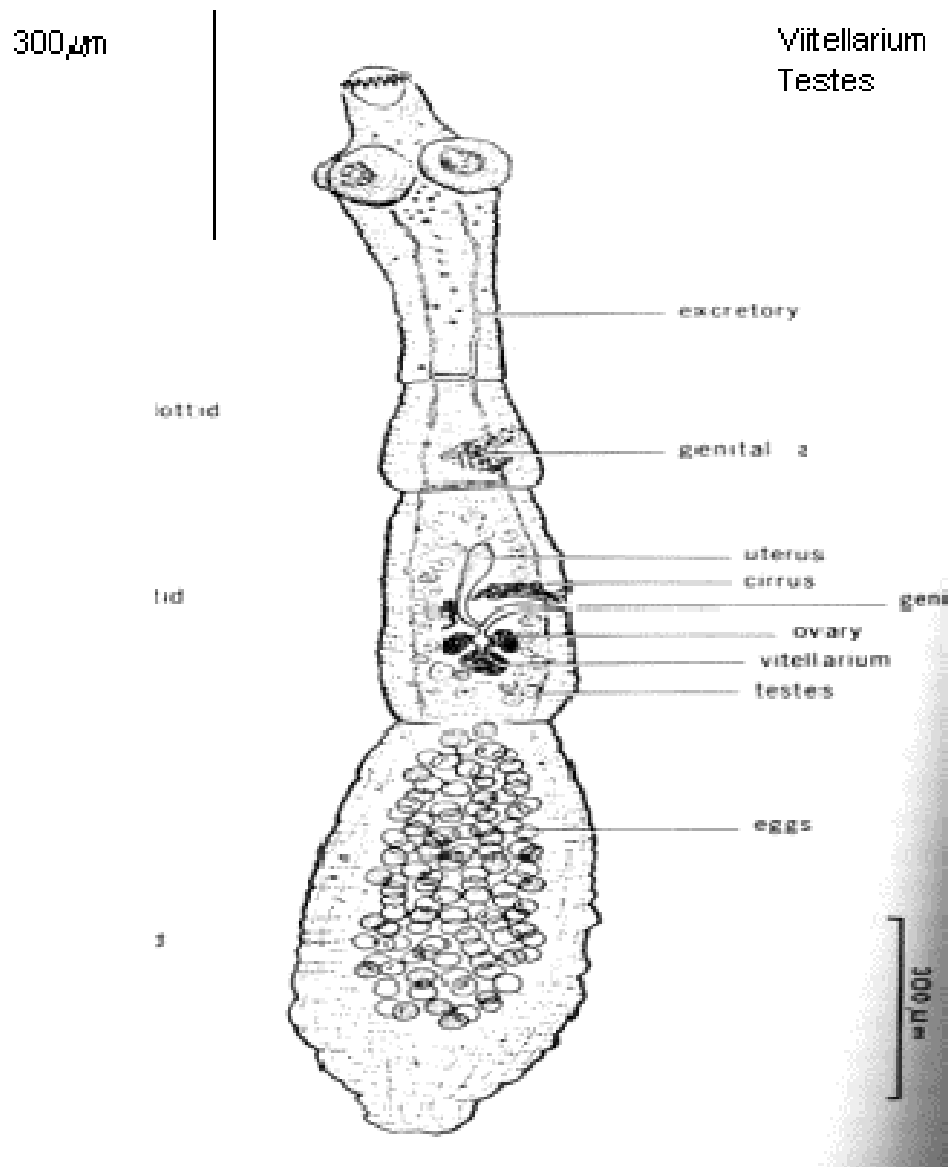


Illustration 8-4. Diagrammatic representation of the adult worm of *Echinococcus multilocularis*. (SOURCE: Unknown)

Clinical Disease

Cysts form primarily in the liver and growth in the vena cava or portal vein results in metastases in the lung or brain. Clinical disease is similar to that of *E. granulosus*.

Laboratory Diagnosis

1. Laboratory diagnosis is can be made by ELISA.
2. Clinical diagnosis is made by ultrasound.

<i>Echinococcus granulosus</i>	<i>Echinococcus multilocularis</i>
Slow development of cyst	Rapid development of cyst
Cysts have thick-walled chambers	Cyst has thin-walled chambers
Separated by connective tissue	Not separated by connective tissue
Cyst is fluid filled	Cyst is gelatinous filled
Cyst is free of host material	Cyst is contaminated by host material

Table 8-1. Differences between the hydatid cysts of *E. granulosus* and *E. multilocularis*. (SOURCE: White)

Multiceps multiceps

Introduction

Multiceps multiceps, is a cestode of cosmopolitan distribution and causes coenuriasis in man. The dog is the common definitive host in the USA and UK, with the intermediate stages developing in many ungulates, especially sheep.

Life Cycle

The adult worm is found in dogs and other canidae. The intermediate hosts comprise of a number of herbivorous animals, where the cysts develop in the brain and spinal cord causing a disease called 'staggers', which affects the balancing powers of the animals. Man becomes infected by the accidental ingestion of eggs. The oncosphere hatches and penetrates the intestinal wall and the embryo is carried by the blood stream to various parts of the body including the central nervous system where it lodges and the cyst or coenurus develops. Multiple scolices burst from the inner surface of the cyst wall. The cyst resembles that of a cysticercus (*Cysticercus cerebralis*). It is filled with fluid, semi-transparent and glistening white. The cysticercus possesses unusual asexual multiplication, forming a bladder (or coenurus) which gives rise to hundreds of daughter protoscoleces directly from its inner wall.

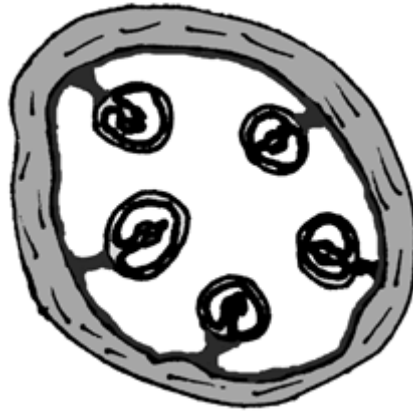


Illustration 8-5. Diagrammatic representation of a *Multiceps (Taenia) multiceps* coenurus cyst. (SOURCE: Unknown)

Clinical Disease

In humans, coenuri are most frequently found in the brain and spinal cord but also in the subcutaneous tissue. Symptoms include headache, vomiting, paraplegia seizures and eye problems. The coenurus may cause serious damage or even death, but only a few have ever been reported.

Laboratory Diagnosis

There are no serological tests available. Diagnosis is achieved by the finding of the coenurus cyst in the brain and spinal cord, or in the subcutaneous tissue.

8.2 Larval Nematodes which Infect Man

Intestinal capillariasis caused by *Capillaria Philippinensis* appeared first in the Philippines and subsequently in Thailand, Japan, Iran, Egypt, and Taiwan, but most infections occur in the Philippines and Thailand. As established experimentally, the life cycle involves freshwater fish as intermediate hosts and fish-eating birds as definitive hosts. Embryonated eggs from feces fed to fish hatch and grow as larvae in the fish intestines. Infective larvae fed to monkeys, Mongolian gerbils, and fish-eating birds develop into adults. Larvae become adults in 10 to 11 days, and the first-generation females produce larvae. These larvae develop into males and egg-producing female worms. Eggs pass with the feces, reach water, embryonate, and infect fish. Autoinfection is part of the life cycle and leads to hyperinfection. Humans acquire the infection by eating small freshwater fish raw. The parasite multiplies, and symptoms of diarrhea, borborygmus, abdominal pain, and edema develop. Chronic infections lead to malabsorption and hence to protein and electrolyte loss, and death results from irreversible effects of the infection. Treatment consists of electrolyte replacement and administration of an antidiarrheal agent and mebendazole or albendazole.

Capillariasis Philippinensis is considered a zoonotic disease of migratory fish-eating birds. The eggs are disseminated along flyways and infect the fish, and when fish are eaten raw, the disease develops.

Capillaria Philippinensis

Introduction

Intestinal capillariasis was first observed in the Philippines in 1962 and since then it has been noted, although less frequently in Thailand, with scattered reports from Taiwan, Japan, Egypt, and Iran. *Capillaria Philippinensis* is a small nematode which burrows into the intestinal mucosa of its human host.

Humans and birds become infected when they eat uncooked or poorly cooked fish. Therefore, infections are seen in endemic proportions where uncooked fish is considered a delicacy.

Life Cycle

The complete life cycle is not known however, human infection is initiated by the consumption of raw fish. The infective larvae are found in the intestine of the fish. When infective fish are eaten by humans, the larvae mature and the adult worms live in the intestinal mucosa, mainly in the jejunum, where they are usually present in large numbers. Larval stages, oviparous and larviparous females are also found in the host's intestine, which suggests that the nematode multiplies in the intestine resulting in auto-infection as in *Strongyloides* infection. The eggs are passed out in the feces and embryonate in the soil, a process which takes about 12 days. The eggs are ingested by fresh-water fish, they hatch and develop into the infective form in the intestine of the fish.

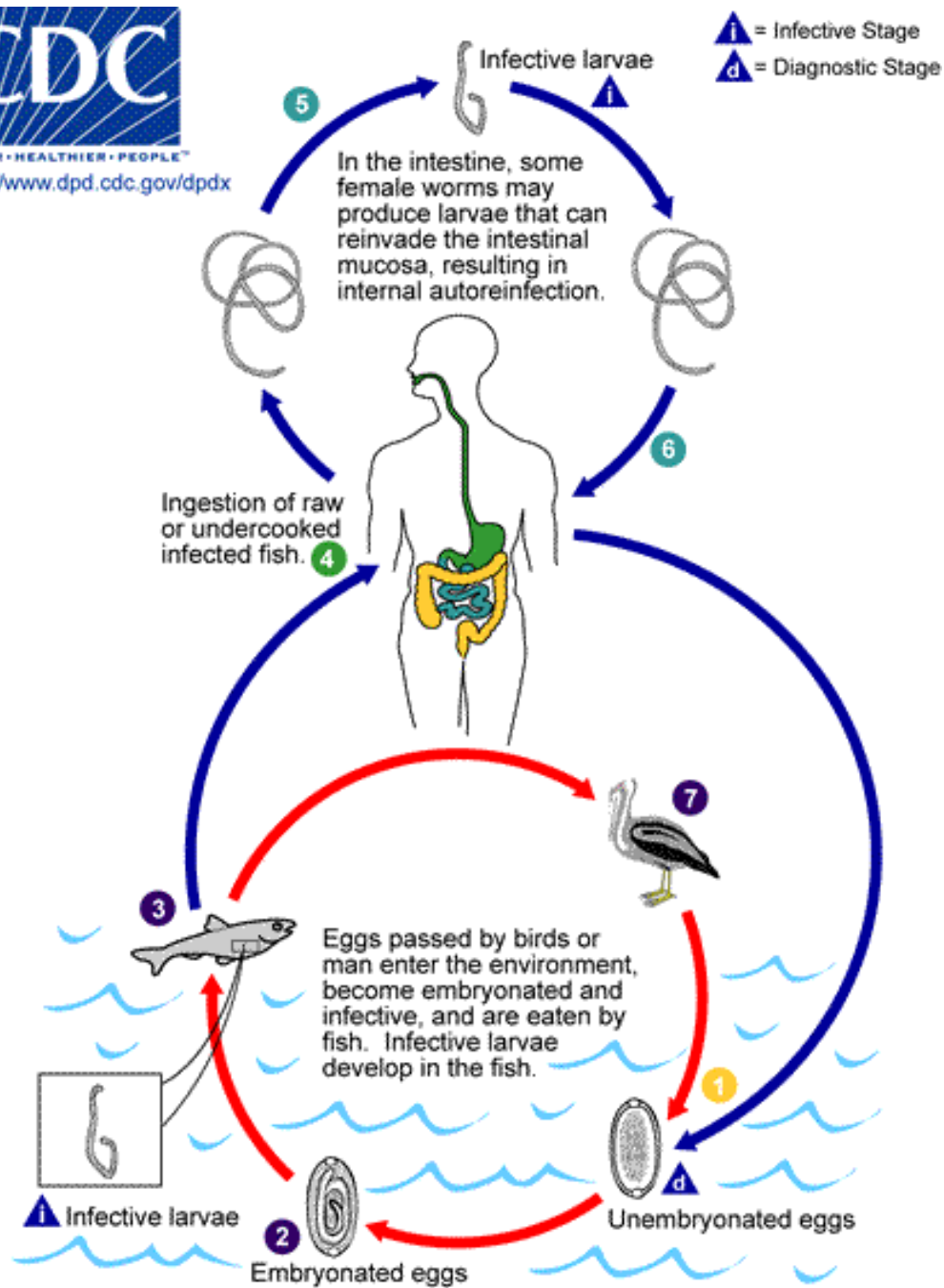


Illustration 8-6. Diagram of the life cycle of *Capillaria philippinensis*. Humans become infected from eating infected fish. The disease in man is known as Capillariasis. Typically, unembryonated eggs are passed in the human stool **1** and become embryonated in the external environment **2**; after ingestion by freshwater fish, larvae hatch, penetrate the intestine, and migrate to the tissues **3**. Ingestion of raw or undercooked fish results in infection of the human host **4**. The adults of *Capillaria philippinensis* (males: 2.3 to 3.2 mm; females: 2.5 to 4.3 mm) reside in the human small intestine, where they burrow in the mucosa **5**. The females deposit unembryonated eggs. Some of these become embryonated in the intestine, and release larvae that can cause autoinfection. This leads to hyperinfection (a massive number of adult worms) **6**. *Capillaria philippinensis* is currently considered a parasite of fish eating birds, which seem to be the natural definitive host **7**. (CDC 3382 - CDC/Alexander J. da Silva, PhD/Melanie Moser)

Morphology

The adult female worm measures 2.5-4.3 μ m, while the males are marginally smaller measuring 2.3-3.2 μ m. Adult females can produce immature and mature ova as well as free larvae that can auto-infect.

The eggs measure 45 μ m x 21 μ m, and resemble those of *Trichuris* but have less prominent polar plugs. They have a thick striated shell.

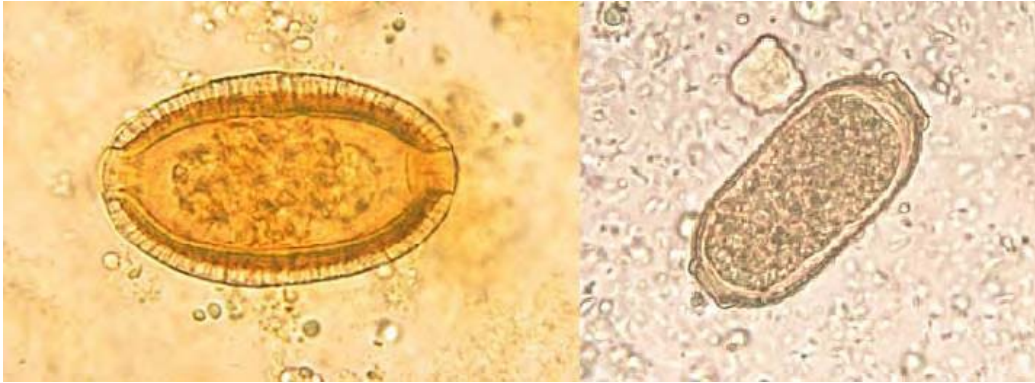


Figure 8-5. Eggs of *Capillaria Philippinensis*. They are oval in shape and closely resemble the eggs of *Trichuris* but have less prominent plugs. (SOURCE: PHIL 1376/653 - CDC/Dr. Mae Melvin)

Clinical Disease

Many cases may be asymptomatic, but any manifested symptoms will be related to the worm burden. The most common symptoms are watery stools with large fluid loss, anorexia, nausea, vomiting, and hypotension. Abdominal distension and edema may also develop. Death can ensue from pneumonia, cerebral edema, hypokalemia and heart failure. The large worm burden can cause electrolyte imbalance, plasma protein imbalance, and fluid loss, proving fatal within 4–6 months if untreated. Villi blunting leads to malabsorption but eosinophilia is not a feature of this disease.

Laboratory Diagnosis

Diagnosis depends on finding the characteristic eggs or larvae in the feces. Pulmonary capillariasis diagnosis relies on finding adult worms or eggs in lung biopsies.

Chapter 9.

Malaria

9.1 Blood Parasites

Red Blood cells offer parasites an excellent environment for invasion and survival. Haemosporina are the only protozoan parasites which can invade the red blood corpuscles of vertebrates. Most, if not all, have multiplicative phases in the reticulo-endothelial system.

The red blood cells are thin-walled and constantly moving, so absorption of food materials and elimination of waste products of metabolism are relatively easy to achieve. They also contain rich supplies of protein and oxygen.

Malarial parasites do not actually penetrate the red blood cell, but enter the cell membrane by endocytosis and enclose in a parasitophorous membrane.

Introduction

Malaria is the most important tropical disease known to man. It remains a significant problem in many tropical areas, especially in sub-Saharan Africa. Malaria is spreading as a result of environmental changes, including global warming, civil disturbances, increasing travel and drug resistance (Greenwood, B.M, 1997). There are approximately 100 million cases of malaria worldwide with about 1 million of these proving fatal.

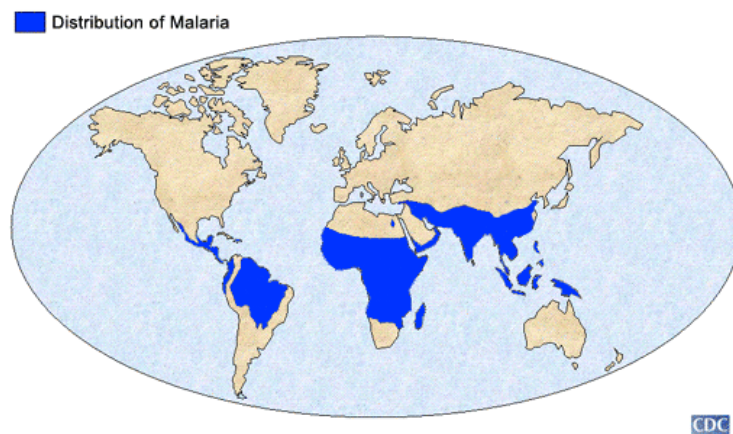


Illustration 9-1. Map illustrating the enormous distribution of malaria throughout the world. (SOURCE: CDC)

Malaria is caused by protozoa of the *Plasmodium* species. There are four species which infect both humans and animals; *Plasmodium malariae* (quartian malaria), *Plasmodium vivax* (benign tertian malaria), *Plasmodium falciparum* (malignant tertian malaria, subtertian malaria) and *Plasmodium ovale* (ovale tertian malaria).

The transmission of the protozoa, *Plasmodium* requires two hosts, an intermediate invertebrate host (vector), and a definitive vertebrate host (mammals, birds and lizards).

All *Plasmodium* species undergo the general haemosporina developmental cycle which can be summarized as:

- initial or continual schizogony (*reproduction by multiple asexual fission*) in the vertebrate host with initiation of gametogony (*the formation or production of gametes*);
- formation of gametes in the arthropod host and subsequent fertilization and formation of a zygote;
- formation of sporozoites from the zygote by repeated nuclear division followed by cytoplasmic divisions. (Smyth, J.D, 1994)

There is no requirement for resistant stages since the transfer of the parasites between the vertebrate and invertebrate hosts is made by withdrawal or injection during the bloodsucking act, there is little or no exposure to the hazards of the outside world; thus by blood transfusion or inoculation, via the blood stages of the parasite.

Life Cycle

Malaria is transmitted by the female anopheline mosquito. The life cycle of all species of human malaria parasites is essentially the same. It comprises an exogenous sexual phase (sporogony) with multiplication in certain Anopheles mosquitoes and an endogenous asexual phase (schizogony) with multiplication in the vertebrate host. The latter phase includes the development cycle in the red cells (erythrocytic schizogony) and the phase taking place in the parenchyma cells in the liver (pre-erythrocytic schizogony).

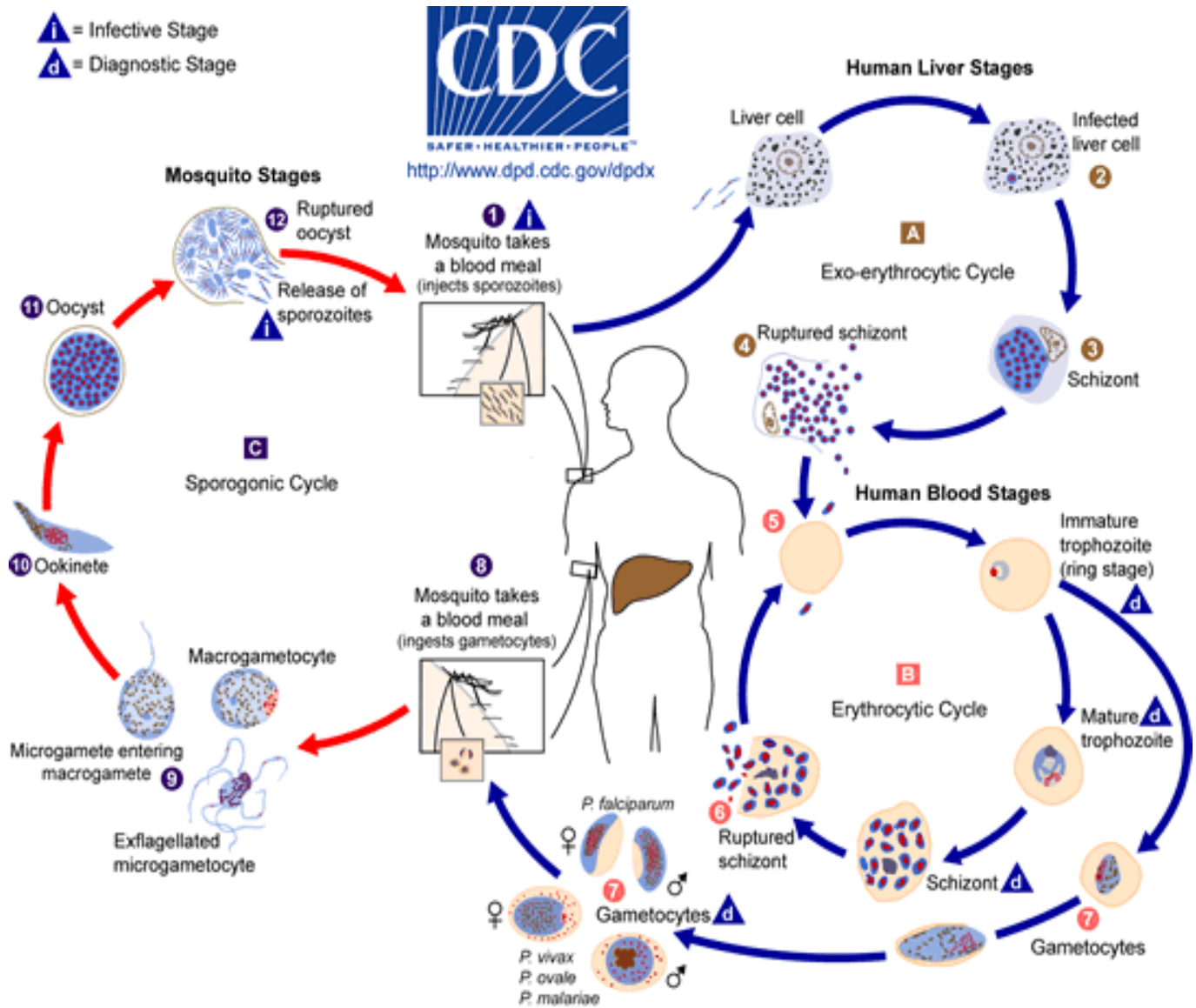


Illustration 9-3. The malaria parasite life cycle. The malaria parasite life cycle involves two hosts. During a blood meal, a malaria-infected female *Anopheles* mosquito inoculates sporozoites into the human host (1). Sporozoites infect liver cells (2) and mature into schizonts (3), which rupture and release merozoites (4). (Of note, in *P. vivax* and *P. ovale* a dormant stage [hypnozoites] can persist in the liver and cause relapses by invading the bloodstream weeks, or even years later.) After this initial replication in the liver (exo-erythrocytic schizogony A), the parasites undergo asexual multiplication in the erythrocytes (erythrocytic schizogony B). Merozoites infect red blood cells (5). The ring stage trophozoites mature into schizonts, which rupture releasing merozoites (6). Some parasites differentiate into sexual erythrocytic stages (gametocytes) (7). Blood stage parasites are responsible for the clinical manifestations of the disease.

The gametocytes, male (microgametocytes) and female (macrogametocytes), are ingested by an *Anopheles* mosquito during a blood meal (8). The parasites' multiplication in the mosquito is known as the sporogonic cycle C. While in the mosquito's stomach, the microgametes penetrate the macrogametes generating zygotes (9). The zygotes in turn become motile and elongated (ookinetes) (10) which invade the midgut wall of the mosquito where they develop into oocysts (11). The oocysts grow, rupture, and release sporozoites (12), which make their way to the mosquito's salivary glands. Inoculation of the sporozoites into a new human host perpetuates the malaria life cycle (1). (SOURCE: PHIL 3405- CDC/Alexander J. da Silva, PhD/Melanie Moser)

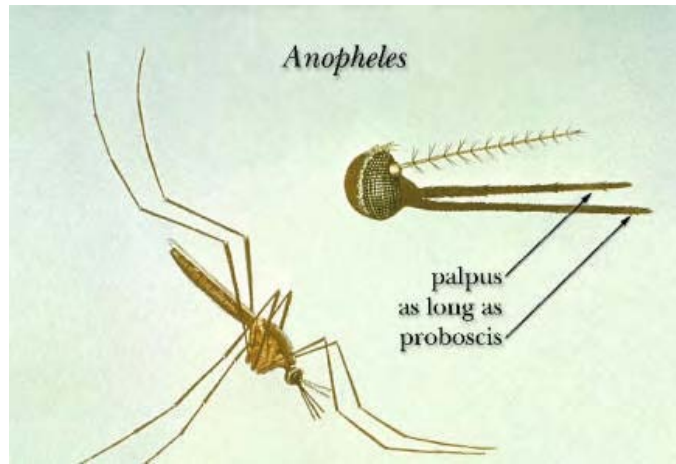


Illustration 9-2. Distinguishing characteristics of the *Anopheles* mosquito.

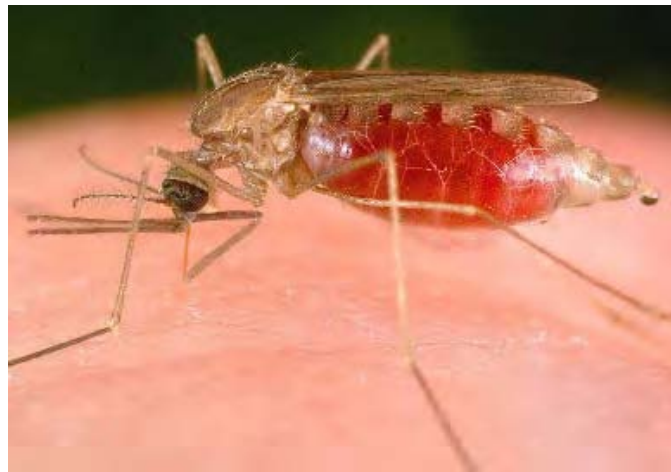

Image 9-1. An Anopheline mosquito, the vector of the protozoa group *Plasmodia*, the parasite known to cause malaria in both man and non-human primates. Malaria is transmitted by female *Anopheles* mosquitoes to the definitive host while the mosquito blood-feeds on its victims. (SOURCE: PHIL 2070/6765 - CDC/ James Gathany)

When a female *Anopheles* mosquito bites an infected person, it ingests blood which may contain the mature sexual cells (male and female gametocytes) which undergo a series of developmental stages in the stomach of the mosquito. Exflagellation (*the extrusion of rapidly waving flagellum-like microgametes from microgametocytes*) occurs resulting in the production in a number of male and female gametes. Fertilization occurs producing a zygote which matures to an ookinete. This penetrates the stomach wall of the mosquito where it grows into an oocyst and it further matures to become a motile sporozoite.

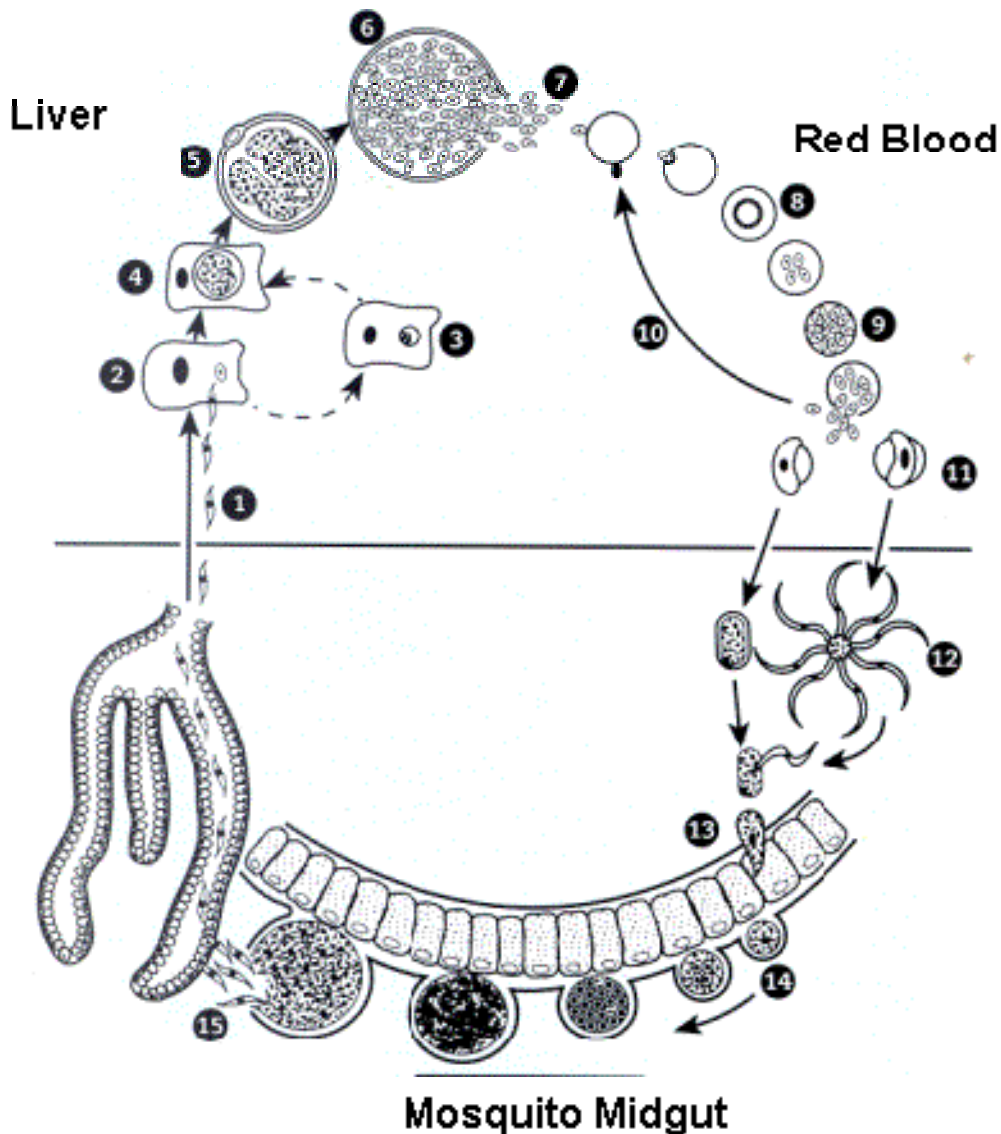


Illustration 9-4. Diagram of the malaria life cycle. **1)** Sporozoites, injected through the skin by female anopheline mosquito; **2)** sporozoites infect hepatocytes; **3)** some sporozoites develop into hypnozoites (*P. vivax* and *P. ovale*); **4)** liver stage parasite develops; **5 – 6)** tissue schizogony; **7)** merozoites are released into the circulation; **8)** ring stage trophozoites in red cells; **9)** erythrocytic schizogony; **10)** merozoites invade other red cells; **11)** some parasites develop into female (macro-) or male (micro-) gametocytes, taken up by the mosquito; **12)** mature macrogamete and exflagellating microgametes; **13)** ookinete penetrates gut wall; **14)** development of oocyst; **15)** sporozoites penetrate salivary glands. (SOURCE: Unknown)

The length of the developmental stage in the mosquito not only depends on the *Plasmodium* species but also the mosquito host and the ambient temperature. This may range from eight days in *Plasmodium vivax* to as long as 30 days in *Plasmodium malariae*.

The sporozoites migrate from the body cavity of the mosquito to the salivary glands and the mosquito now becomes infective. Sporozoites enter into the blood stream of a host when the mosquito feeds on blood. Following the inoculation, the sporozoites leave the blood within 40 minutes and enter the parenchymal cells of the liver (hepatocytes). In all four species, asexual

development occurs in the liver cells, a process known as pre-erythrocytic schizogony, to produce thousands of tiny merozoites which are released into the circulation after about 16 days. However in *P. vivax* and *P. ovale* some sporozoites differentiate into hypnozoites which remain dormant in hepatocytes for considerable periods of time. When they are “reactivated” they undergo asexual division and produce a clinical relapse.

In *P. falciparum* and *P. malariae* hypnozoites are not formed and the parasite develops directly into pre-erythrocytic schizonts.

Once in the circulation, the merozoites invade the red cells and develop into trophozoites. In the course of their development they absorb the hemoglobin of the red cells and leave as the product of digestion a pigment called hemozoin, a combination of hematin and protein. This iron-containing pigment is seen in the body of the parasite in the form of dark granules, which are more obvious in the later stages of development.

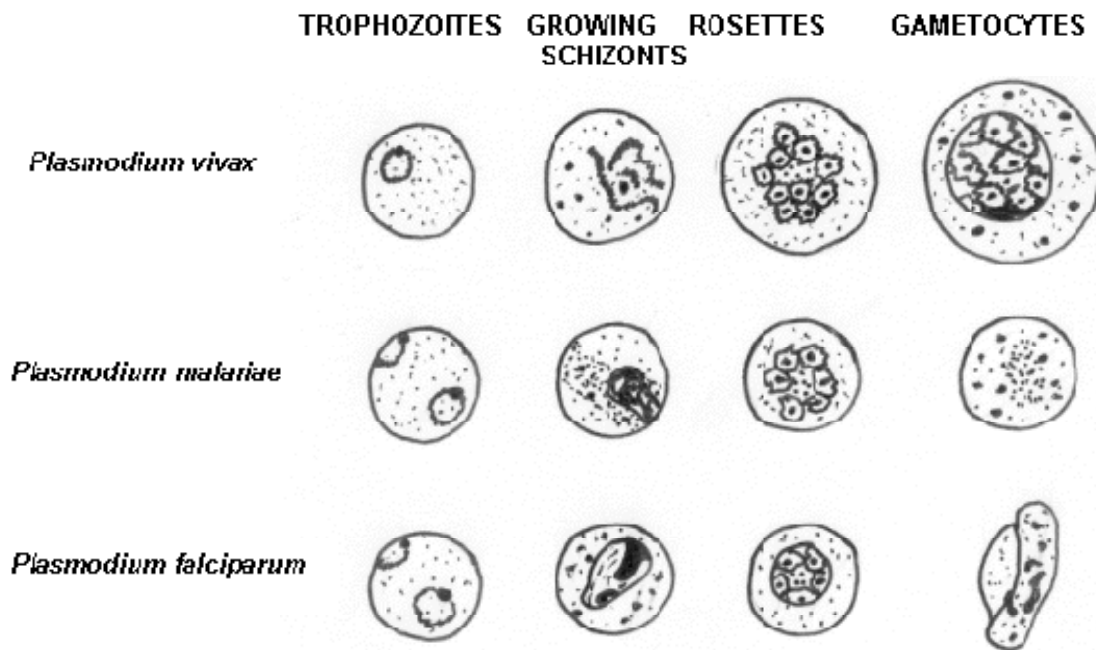


Illustration 9-5. Diagram illustrating the various stages of the three common species of malaria which infect man. (SOURCE: Unknown)

After a period of growth the trophozoite undergoes an asexual division, erythrocytic schizogony. When the mature trophozoite starts to divide in the red blood cell, separate merozoites are formed resulting in a schizont. When fully developed, the schizont ruptures the red blood cell containing it, liberating the merozoites into the circulation. These merozoites will then infect new red cells and the process of asexual reproduction in the blood tends to proceed. Some of the merozoites entering red blood cells do not form trophozoites then schizonts but develop into gametocytes and this process takes place in deep tissue capillaries. This erythrocytic cycle of schizogony is repeated over and over again in the course of infection, leading to a progressive increase of parasitemia.

Infections with all four strains of malaria have many clinical features in common. These are related to the liberation of fever-producing substances, especially during schizogony. The common features are:

Fever: Often irregular. The regular pattern of fever does not occur until the illness has continued for a week or more; where it depends on synchronized schizogony.

Anemia: The anemia is hemolytic in type. It is more severe in infections with *P. falciparum* because in this infection cells of all ages can be invaded. Also, the parasitemia in this infection can be much higher than in other malarial infections.

Splenomegaly: The spleen enlarges early in the acute attack of malaria. When a patient has been subjected to many attacks, the spleen may be of an enormous size and lead to secondary hypersplenism.

Jaundice: A mild jaundice due to hemolysis may occur in malaria. Severe jaundice only occurs in *P. falciparum* infection, and is due to liver involvement.

9.2. Species Specific Characteristics

Plasmodium falciparum

Introduction

Plasmodium falciparum exists in the tropics and sub-tropics, and is responsible for approximately 50% of all malaria cases. The incubation period of *P. falciparum* malaria is the shortest, between eight and 11 days and has a periodicity of 36–48 hours. It can be differentiated from the other species by the morphology of the different stages found in the peripheral blood. In infections with *Plasmodium falciparum* usually only young trophozoites and gametocytes are seen in peripheral blood smears, the schizonts are usually found in capillaries sinuses of internal organs and in the bone marrow. The disease it produces runs an acute course and often terminating fatally. It is a significant cause of abortions and stillborns and even death of non-immune pregnant women.

Life Cycle

The aspects of the life cycle which are specific to *P. falciparum* are as follows:

- It attacks all ages of erythrocytes so that a high density of parasites can be reached quickly. In extreme cases up to 48% of the red blood cells can be parasitized.
- Multiple infections resulting in several ring forms in a corpuscle are not uncommon.
- The latter stages in the asexual cycle do not occur in the peripheral blood as in other forms of malaria, so that only rings and crescents are found in blood films. After 24 hours the ring forms and older trophozoites show a tendency to clump together and adhere to the visceral capillary walls and become caught up in the vessels of the

heart, intestine, brain or bone marrow in which the later sexual stages are completed.

- Sporulation is not as well synchronized as in other malaria forms so that the fever may last longer.
- Exo-erythrocytic forms do not persist in the tissues and hence relapses do not occur.

Morphology of Trophozoites

Red blood cells in *Plasmodium falciparum* infections are not enlarged and they may have a spiky outline which is common in cells which have dried slowly. The typical arrangement cytoplasm in young trophozoites is the well-known ring formation which thickens and invariably contains several vacuoles as the trophozoite develops. Chromatin is characteristically found as a single bead, but double beads and small curved rod forms frequently occur.

Maurer's dots are slow to appear and are first seen as minute purplish dots, 6 or less in number. The points become spots, still few in number and are now characteristic enough to be recognized. Maurer describes them as fine ringlets, loops or streaks. They are seldom absent from the red blood cells containing large rings but the staining of the spots is very sensitive to pH and are seldom seen if the pH falls below 6.8.

Trophozoites of *P. falciparum* can be found on the edge of the red blood cells. These are known as accolé forms and are found as three distinct types:

1. **Common:** The single chromatin bead lies on the edge of the cell with most of the cytoplasm extended along the edge on both sides of the bead.
2. **Rim:** The complete parasite lies in a thickened line along the edge of the cell with no evidence of ring formation.
3. **Displaced:** The parasites are displaced beyond the edge of the host cell. All degrees of displacement may occur, from partial to marked displacement with most of the parasite lying beyond the cell margin.

Pigment is not a characteristic finding in the early stages of *P. falciparum* infections.

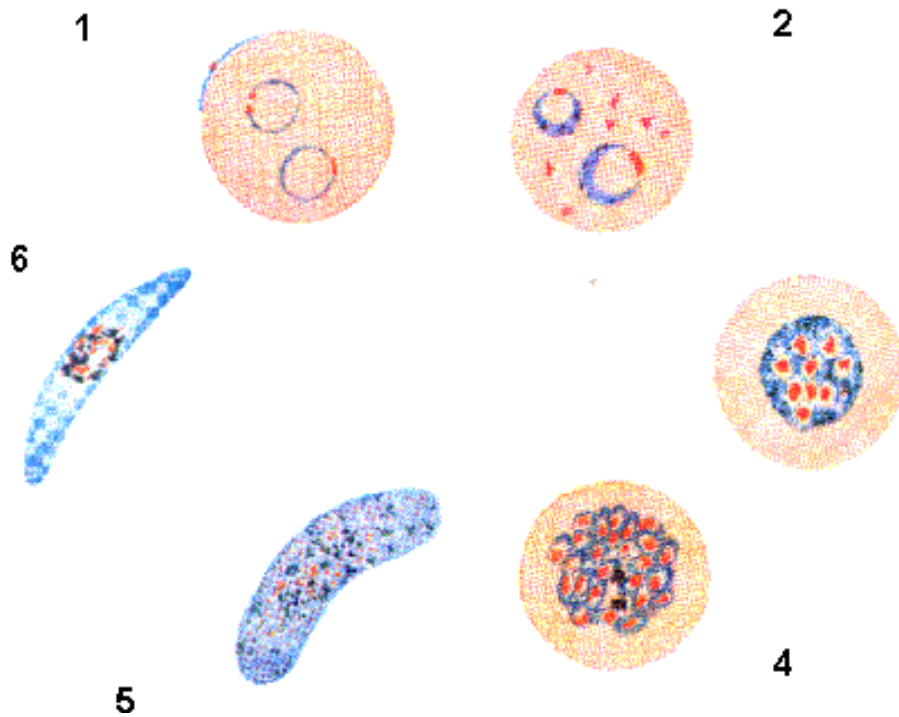


Illustration 9-6. Diagrammatic illustration of the morphology of the different stages of the *Plasmodium falciparum* life cycle in thin blood films. **1)** *P. falciparum* early trophozoites / ring forms. **2)** Developing trophozoites (rarely seen in peripheral blood). **3)** Immature schizonts (rarely seen in peripheral blood). **4)** Mature schizonts, almost fill the red blood cell. **5)** Microgametocytes, large numbers appear after 7–12 days. **6)** Macrogametocytes, large numbers appear after 7-12 days.

Morphology of Gametocytes

Gametocytes are the sexual stage of the malaria parasite. *Plasmodium falciparum* gametocytes appear in the peripheral circulation after 7-12 days of patent parasitemia and by then, they have assumed their typical crescent shapes. They soon reach their peak density, and then decline in numbers, disappearing in about three months as a rule.

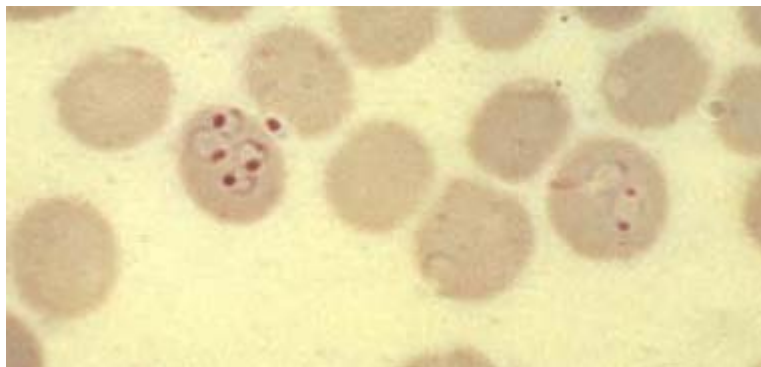


Image 9-2. Young trophozoite / ring stage of *Plasmodium falciparum*. The ring thickens and invariably contains several vacuoles as the trophozoite develops. Maurer's dots are slow to appear and are first seen as minute purplish dots. (Giemsa stain). (SOURCE: PHIL 5946 - CDC/ Steven Glenn, Laboratory & Consultation Division)

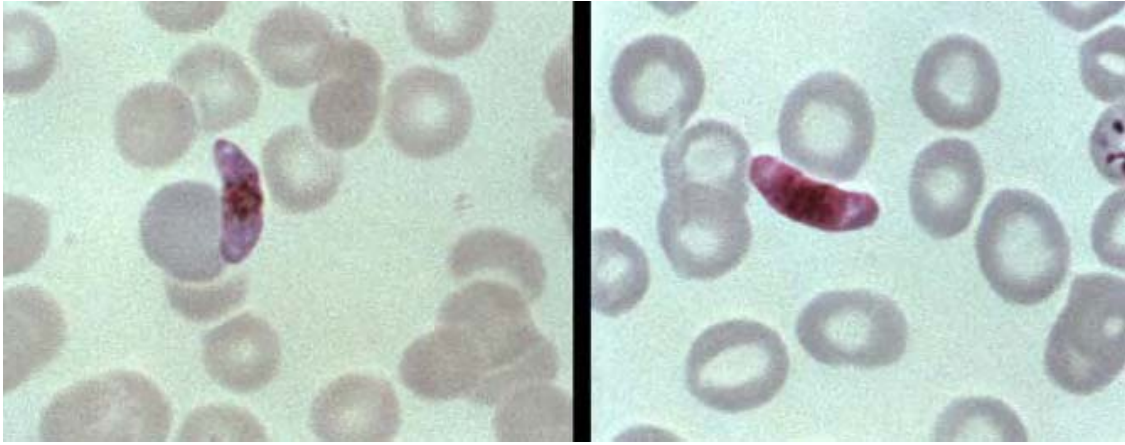


Image 9-3. *Plasmodium falciparum* gametocytes appear in the peripheral circulation after 7-12 days of patent parasitemia and by then, they have assumed their typical crescent shapes. (Giemsa stain) (SOURCE: PHIL 5941 - CDC/ Steven Glenn, Laboratory & Consultation Division)

The female form, or macrogametocyte, is usually more slender and somewhat longer than the male, and the cytoplasm takes up a deeper blue color with Giemsa stain. The nucleus is small and compact, staining dark red, while the pigment granules are closely aggregated around it. The male form, or microgametocyte, is broader than the female and is more inclined to be sausage shaped. The cytoplasm is either pale blue or tinted with pink and the nucleus, which stains dark pink, is large and less compact than in the female, while the pigment granules are scattered in the cytoplasm around it.

In humans, gametocytes do not multiply, nor cause symptoms but they are the forms which are infective to the mosquito. When a female Anopheline mosquito takes a blood meal, the male and female gametocytes continue their sexual development.

Morphology of Schizonts

Schizonts are rarely seen in the peripheral blood and their presence may indicate a potentially serious parasitemia. Schizonts have 8-36 merozoites and a large mass of golden brown pigment (hemozoin) is seen in the pre-schizont and schizont stage.

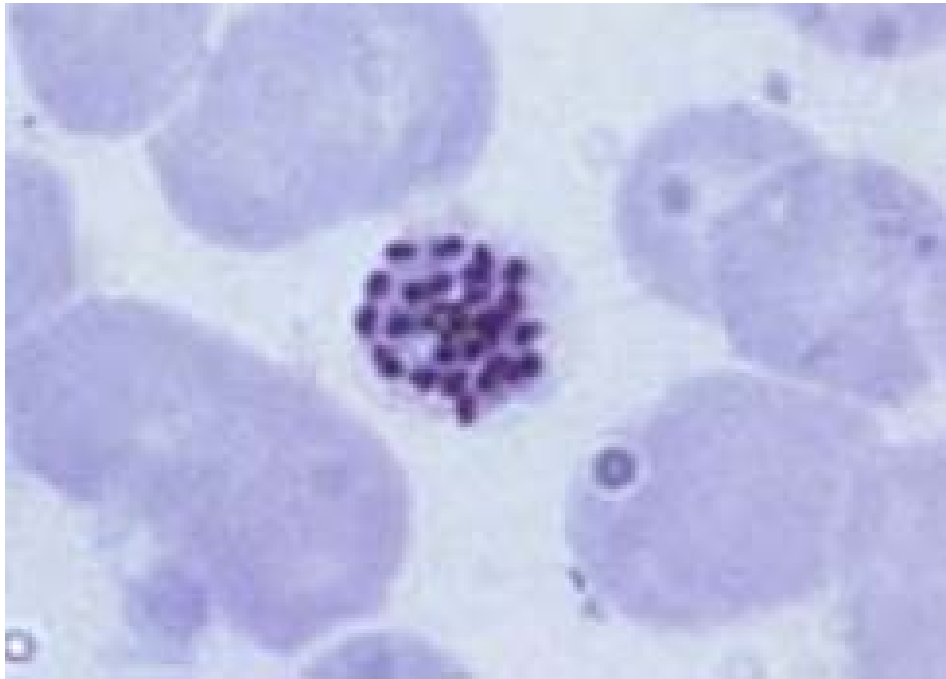


Image 9-4. *Plasmodium falciparum* schizont. Rarely seen in the peripheral blood, a good indicator of a potentially serious parasitemia. They have 8 – 36 merozoites and a large golden brown pigment. (Giemsa stain) (SOURCE: PHIL 5854 - CDC/Steven Glenn, Laboratory & Consultation Division)

Clinical Disease

Symptoms include headache, photophobia, muscle aches and pains, anorexia, nausea and vomiting. Complications include severe anemia cerebral malaria, renal disease, black water fever, dysentery, pulmonary edema and tropical splenomegaly syndrome.

Plasmodium vivax

Introduction

Plasmodium vivax is found almost everywhere malaria is endemic and is the most predominant of the malaria parasites. Causing 43% of all cases of malaria in the world, it also has the widest geographical distribution. Although the disease itself is not usually life threatening, it can cause severe acute illness.

Plasmodium vivax does not infect West Africans due to the fact that West Africans do not possess the Duffy Antigen on the red blood cells which the parasite requires to enter the red blood cell. It has an incubation period of between 10 and 17 days which is sometimes prolonged to months or years due to the formation of hypnozoites. It has a periodicity of 48 hours. *Plasmodium vivax* infections are usually characterized by the presence of more than one developmental stage in the peripheral blood film. The parasites parasitize young enlarged erythrocytes and Schüffner's dots develop on the erythrocyte membrane.

Life Cycle

The aspects of the life cycle which are specific to *P. vivax* are as follows:

- The degree of infectivity is low, only the young immature corpuscles are infected; about 2% of erythrocytes are parasitized.
- The periodicity of the asexual cycle is closely synchronized.
- Hypnozoites develop in the liver, so that relapses may occur.

Morphology of Trophozoites

Most trophozoites of *P. vivax* are already several hours old when they appear in peripheral blood and by that time the Schüffner's dots are already visible. The trophozoites are actively amoeboid and contain single or sometimes double chromatin dots that are either circular or ovoid. As the trophozoites mature, the Schüffner's dots increase in number and size and the parasite changes from large irregular rings to rounded or ovoid forms in mature trophozoites.

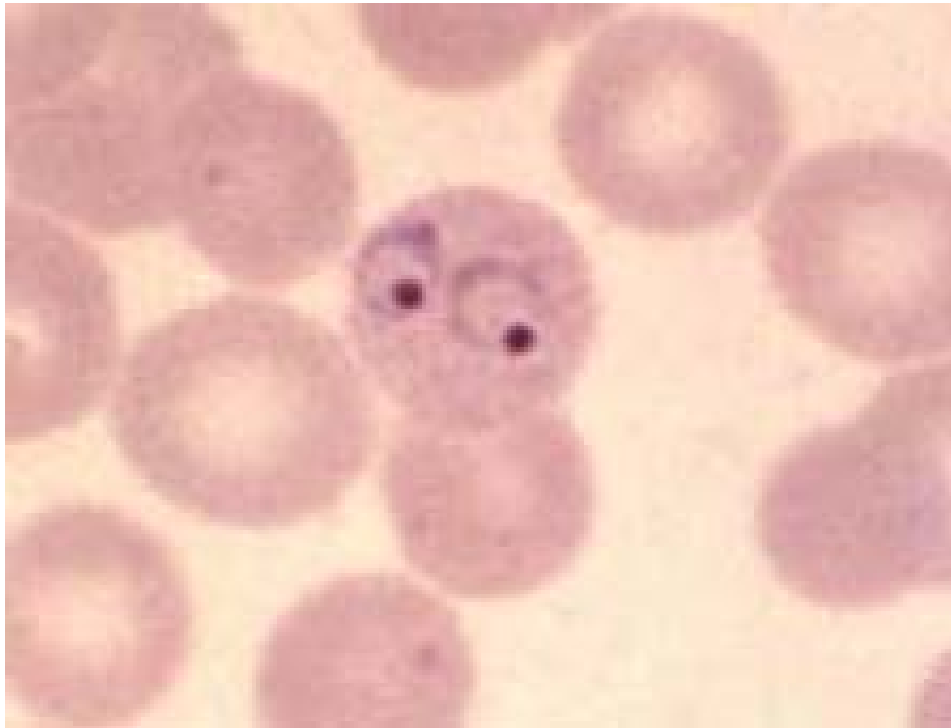

Image 9-5. Trophozoites of *Plasmodium vivax* are already several hours old when they appear in the peripheral blood and therefore, you can already see the Schüffner's dots. They contain single or sometimes double chromatin dots. (Giemsa stain) (SOURCE: PHIL 5928 - CDC/ Steven Glenn, Laboratory & Consultation Division)

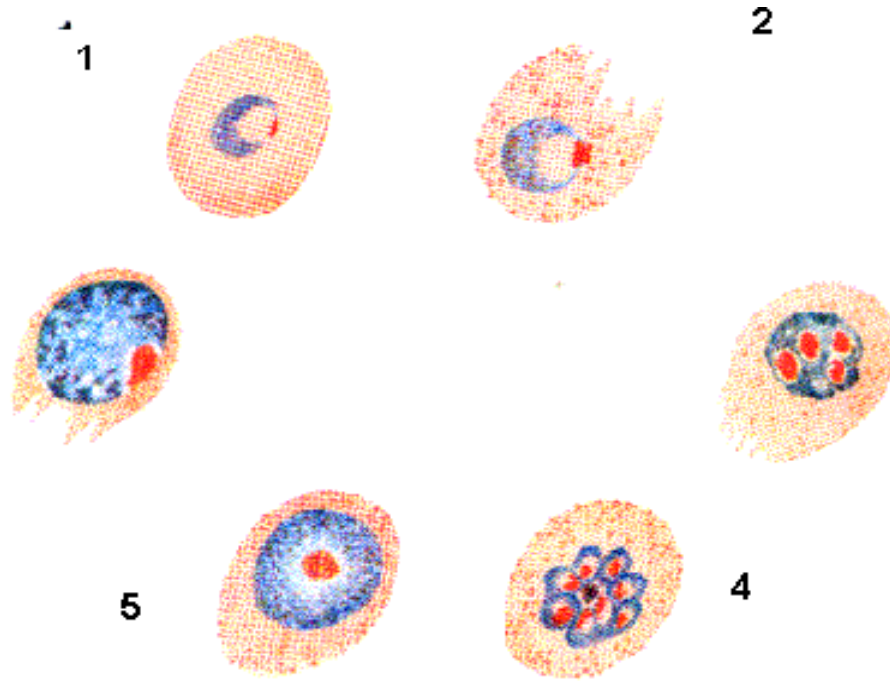


Illustration 9-7. Diagrammatic illustration of the morphology of the different stages of the *Plasmodium vivax* life cycle in thin blood films. **1)** Early trophozoites / ring forms (accolé forms, not shown here, are occasionally seen). **2)** Developing trophozoites are large and irregular with a prominent vacuole. **3)** Immature schizonts, are amoeboid and almost fill the red blood cell. **4)** Mature schizonts, almost fill the red blood cell. **5)** Microgametocyte, large numbers appear after 3–5 days. **6)** Macrogametocyte, large numbers appear after 3–5 days. (SOURCE: Unknown)

Morphology of Gametocytes

Mature female gametocytes are large rounded parasites which fill or nearly fill the host cell. The cytoplasm is blue and fairly homogenous. The nuclear chromatin is a single, well-defined purplish mass, varied in form and usually peripheral in distribution. Mature male gametocytes can be distinguished from females by the large, loose and ill-defined mass of chromatin and by their paler color and smaller mass.

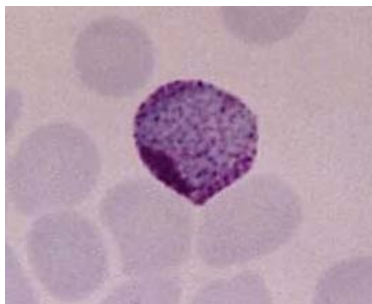


Image 9-6. Mature female *Plasmodium vivax* gametocytes are large rounded parasites which fill or nearly fill the host cell. The cytoplasm is blue and fairly homogenous. The nuclear chromatin is a single, well-defined purplish mass, varied in form and usually peripheral in distribution. (Giemsa stain) (SOURCE: PHIL 5138 - CDC/ Dr. Mae Melvin)

Morphology of Schizonts

The parasitized red cells are much enlarged containing Schüffner's dots. The parasites are large, filling the enlarged red cell. There are between 12-24 merozoites in the schizonts (usually 16). The pigment is a golden brown central loose mass.

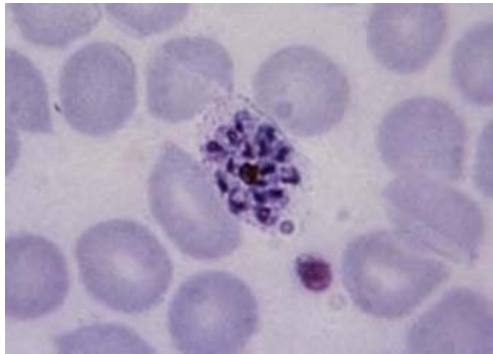


Image 9-7. A schizont of *Plasmodium vivax*. The parasites are large, filling the enlarged red cell. There are between 12 - 24 merozoites in the schizonts (usually 16). The pigment is a golden brown central loose mass. (Giemsa stain) (SOURCE: PHIL 5925 - CDC/ Steven Glenn, Laboratory Training & Consultation Division)

Clinical Disease

Symptoms include headache, photophobia, muscle aches and pains, anorexia, nausea and vomiting. Complications due to *P. vivax* are relatively rare and arise from a previous debility or pre-existing disease.

Plasmodium ovale

Introduction

Plasmodium ovale is widely distributed in tropical Africa especially the west coast, but it is not often encountered. It has also been reported in South America and Asia. It has an incubation period of 10–17 days which is sometimes prolonged to months or years due to the formation of hypnozoites. It has a periodicity of 48 hours; the fever it produces is milder than that caused by the benign tertian *P. falciparum*.

Life Cycle

The features of the life cycle which are specific to *P. ovale* are as follows:

- It morphologically resembles *P. malariae* in most of its stages.

- The changes produced in the erythrocytes in general are similar to those produced by *P. vivax*, but Schüffner's dots appear considerably earlier (in the ring stage) and are coarser and more numerous.
- In the oocyst the pigment granules are (usually) characteristically arranged in two rows crossing each other at right angles.
- Hypnozoites develop in the liver so that relapses may occur.

Morphology of Trophozoites

Parasites of *P. ovale* are usually found in enlarged and stippled red blood cells (James's dots), similar to those found in *P. vivax* infections. Host cells show an oval shape, particularly those containing younger stages of the parasites and the host cell may also show "spiking" or fimbriation.

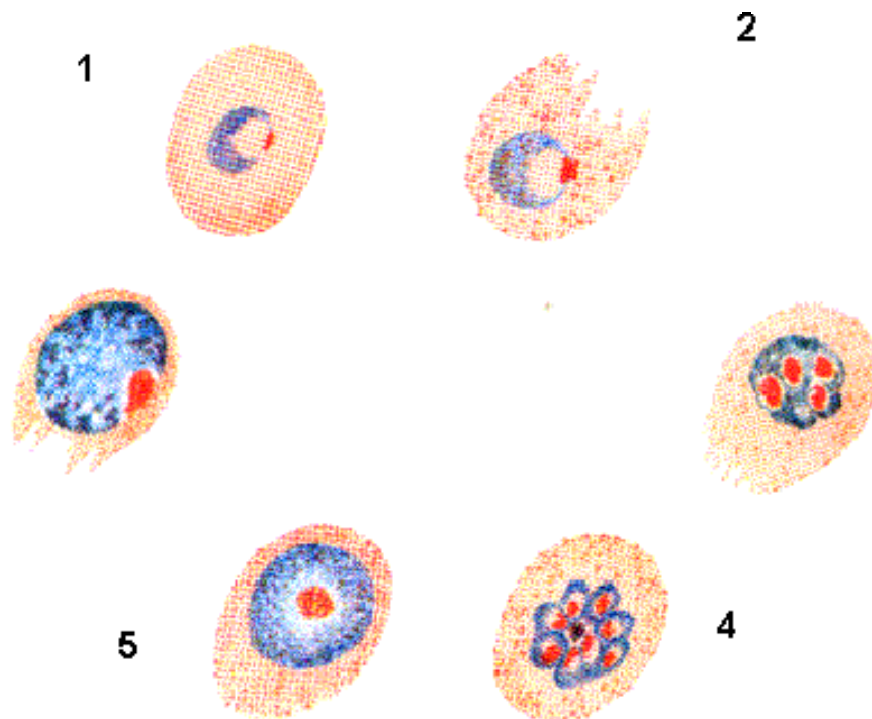


Illustration 9-8. Diagrammatic illustration of the morphology of the different stages of the *Plasmodium ovale* life cycle in thin blood films. **1)** Early trophozoites / ring forms, are dense rings with well- defined masses of chromatin. **2)** Developing trophozoites, small and compact with an inconspicuous vacuole. **3)** Immature schizonts, compact and almost fill the red blood cell. **4)** Mature schizonts, fill $\frac{3}{4}$ of the red blood cell. **5)** Microgametocytes, low numbers appear after 12-14 days. **6)** Macrogametocytes, low numbers appear after 12–14 days.

Young trophozoites are found as compact rings in cells containing Schüffner's dots. The trophozoite rings remain compact as they develop and show little of the amoeboid features common in *P. vivax*. Small, scattered pigment granules can be seen in developing trophozoites which disperse as the trophozoite matures. Late trophozoites are round and consolidated with an increase in cytoplasm, they are very similar to *P. vivax* at this stage.

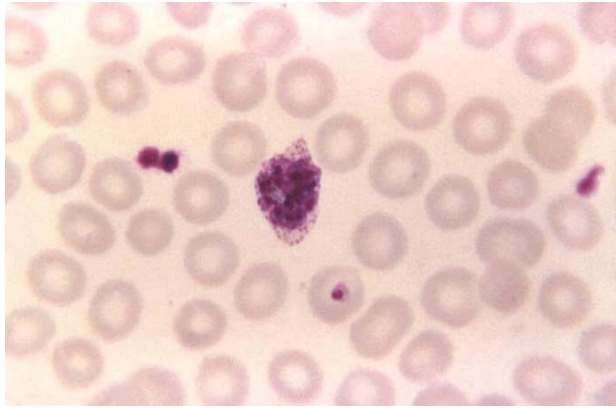


Image 9-8. Trophozoite of *Plasmodium ovale*. Young trophozoites are found as compact rings in cells containing Schüffner's dots. The trophozoite rings remain compact as they develop. Late trophozoites are round and consolidated with an increase in cytoplasm, they are very similar to *P. vivax* at this stage. (SOURCE: PHIL 5935 - CDC/ Steven Glenn, Laboratory & Consultation Division)

Morphology of Gametocytes

The mature gametocytes are round, filling two thirds of the red cell. The red blood cell is slightly enlarged and stippled and contains pigment which has a distinct arrangement of concentric rods, mostly at the periphery.

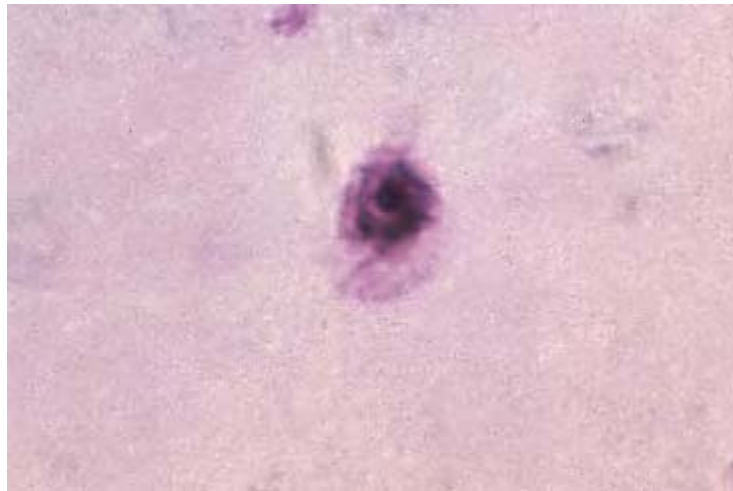


Image 9-9. Gametocyte of *Plasmodium ovale*. The mature gametocytes are round, filling two thirds of the red cell. (Giemsa stain) (SOURCE: PHIL 3474 – CDC/Dr. Mae Melvin)

Morphology of Schizonts

The parasite is smaller than red blood cells and contains 6-12 merozoites, usually 8 in a single ring. The pigment is a brown / greenish central clump. The red cell slightly enlarged, stippled, frequently oval and fimbriated.

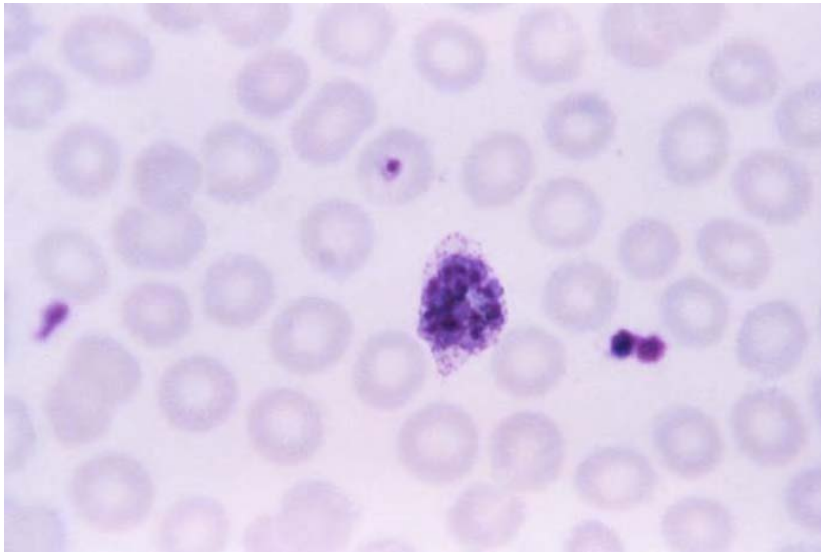


Image 9-10. Schizont of *Plasmodium ovale*. The parasite is smaller than the red blood cell and contains 6 – 12 merozoites. The red cell is slightly enlarged, stippled, frequently oval and fimbriated. (Giemsa stain) (SOURCE: PHIL 5846 - CDC/ Steven Glenn, Laboratory & Consultation Division)

Clinical Disease

Symptoms, like those of *P. vivax*, include headache, photophobia, muscle aches and pains, anorexia, nausea and vomiting. Complications due to *P. ovale* are relatively rare and arise due do a previous debility or pre-existing disease.

Plasmodium malariae

Introduction

Plasmodium malariae occurs mainly in the subtropical and temperate areas where *P. falciparum* and *P. vivax* occur. It is responsible for approximately 7% of all malaria in the world. It has an incubation period of 18–40 days and a periodicity of 72 hours.

Life Cycle

The features of the life cycle specific to *P. malariae* are as follows:

- Infected erythrocytes are not larger than uninfected ones and sometimes even smaller.
- Mature erythrocytes are attacked, but reticulocytes generally are not
- The density of parasites is very low; about 0.2% of erythrocytes are parasitized.
- It is often difficult to distinguish between a large trophozoite and an immature gametocyte.

Morphology of Trophozoites

Parasites of *P. malariae* are typically compact heavily pigmented parasites which are usually smaller and more deeply stained than normal. They tend to parasitize small, old red blood cells, they do not contain any inclusion dots and the parasitaemia is usually low.

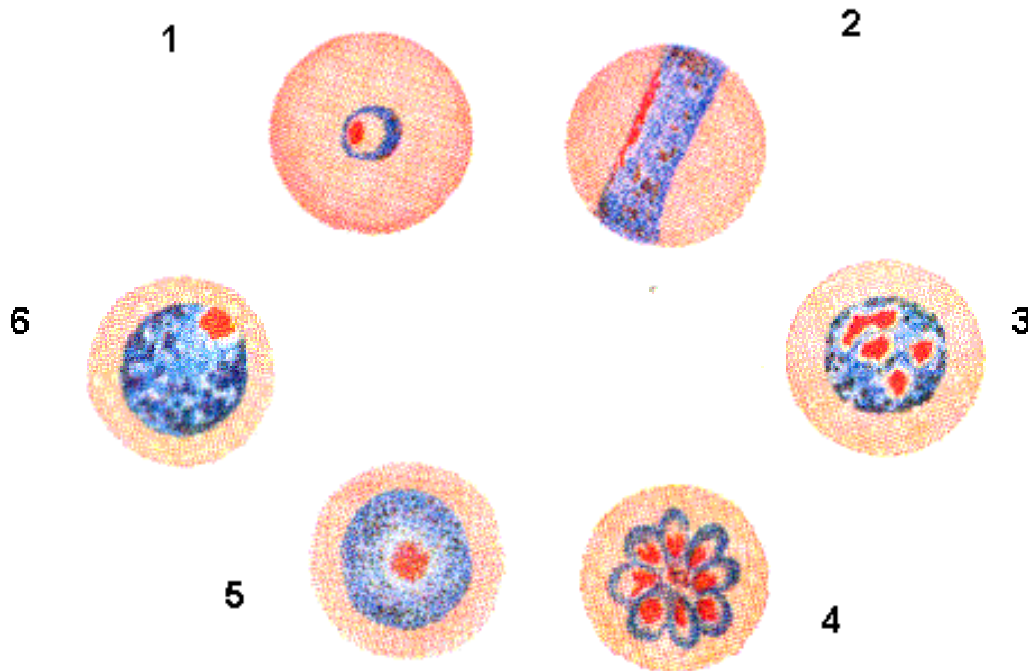


Illustration 9-9. Diagrammatic illustration of the morphology of the different stages of the *Plasmodium malariae* life cycle in thin blood films. **1)** Early trophozoites / ring forms, compact rings containing one mass of chromatin. **2)** Developing trophozoites, small and compact (often band forms) with an inconspicuous vacuole. **3)** Immature schizonts, compact and almost fill the red blood cell which contains scattered pigment. **4)** Mature schizonts, almost fill the red blood cell. **5)** Microgametocytes, low numbers appear after 7–14 days. **6)** Macrogametocytes, low numbers appear after 7-14 days.

Trophozoites are found as fairly large fleshy rings with a single chromatin dot. These can be very distorted and can often take the form of bands across the cell. All trophozoites have a single chromatin dot and contain pigment.

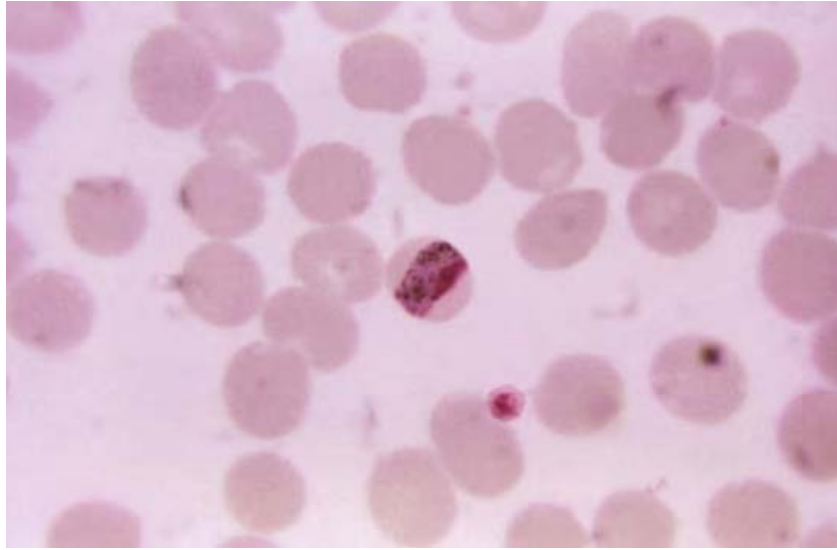


Image 9-11. Trophozoite of *Plasmodium malariae*. These can be very distinct and distorted by taking the form of a band across the cell. (Giemsa stain) (SOURCE: PHIL 639 - CDC/ Dr. Mae Melvin, Steve Glenn)

Morphology of Gametocytes

Gametocytes contain large amounts of black pigment, with chromatin present as a compact mass in females and diffuse in males. They occupy less than two thirds of the red blood cell.

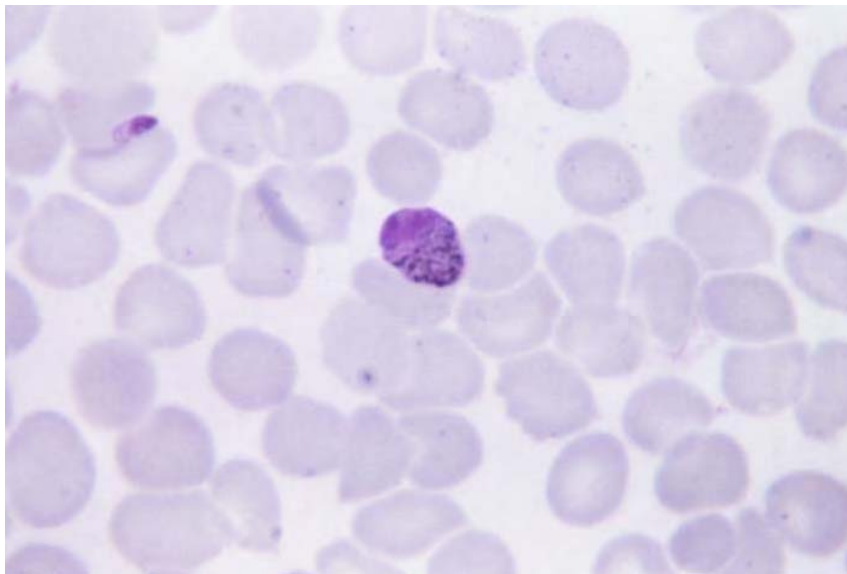


Image 9-12. *Plasmodium malariae* gametocyte. They contain large amounts of black pigment, with chromatin present as a compact mass in females (macrogametocyte) and diffuse in males (microgametocyte). (Giemsa stain) (SOURCE: PHIL 5837 - CDC/ Steven Glenn, Laboratory & Consultation Division)

Morphology of Schizonts

Schizonts are usually few in numbers with 6-12 large merozoites in a single ring. Pigment is usually present as a central black mass. The parasites present are generally only found at one stage of schizogony development.

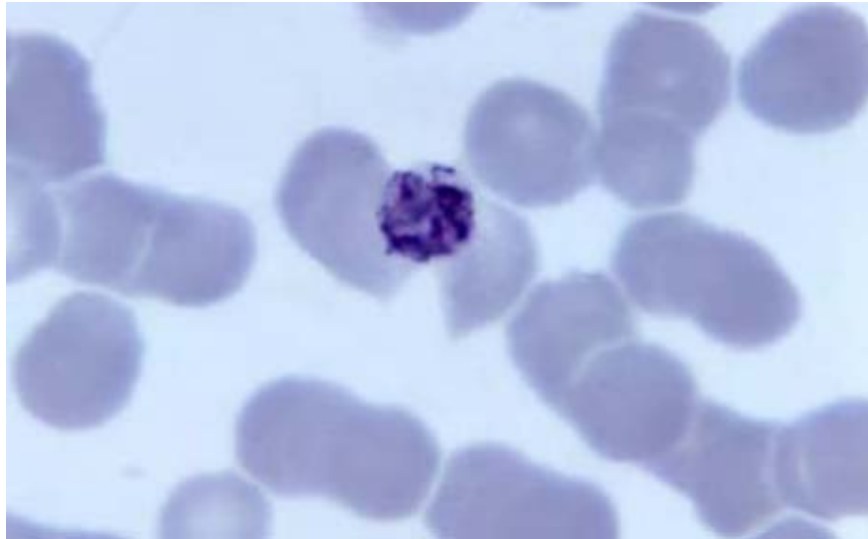


Image 9-13. Schizont of *Plasmodium malariae*. They are usually few in numbers with 6–12 large merozoites in a single ring. Pigment is usually present as a central black mass. (Giemsa stain) (SOURCE: PHIL 4826 - CDC/Dr. Mae Melvin)

Clinical Disease

Symptoms include headache, photophobia, muscle aches and pains, anorexia, nausea and vomiting. *Plasmodium malariae*, like *P. vivax* and *P. ovale* are relatively benign. However, chronic infections in children may lead to nephrotic syndrome due to immune complexes depositing on the glomerular wall.

9.3. Laboratory Diagnosis of Malaria Parasites

Introduction

The definitive diagnosis of malaria infection is still based on finding malaria parasites in blood films. In thin films the red blood cells are fixed so the morphology of the parasitized cells can be seen. Species identification can be made, based upon the size and shape of the various stages of the parasite and the presence of stippling (i.e. bright red dots) and fimbriation (i.e. ragged ends). However, malaria parasites may be missed on a thin blood film when there is a low parasitemia. Therefore, examination of a thick blood film is recommended. With a thick blood film, the red cells are approximately 6-20 layers thick which results in a larger volume of blood being examined.

Thick Blood Films

In examining stained thick blood films, the red blood cells are lysed (destroyed), so diagnosis is based on the appearance of the parasite. In thick films, organisms tend to be more compact and denser than in thin films.

Field's Stain Method for Thick blood Films

The method recommended for staining thick blood is Field's Stain which is made from two components. Field's A is a buffered solution of azure dye and Field's B is a buffered solution of eosin. Both Field's A and B are supplied ready for use by the manufacturer.

Method

1. Place a drop of blood on a microscope slide and spread to make an area of approximately 1 cm². It should just be possible to read small print through a thick film.
2. The film is air dried and NOT fixed in methanol.
3. The slide is dipped into Field's stain A for three seconds.
4. The slide is then dipped into tap water for three seconds and gently agitated.
5. The slide is dipped into Field's stain B for three seconds and washed gently in tap water for a few seconds until the excess stain is removed.
6. The slide is drained vertically and left to dry.

Microscopic Features of the Field's Stained Thick Blood Film

- The end of the film at the top of the slide when it was draining should be looked at. The edges of the film will also be better than the centre, where the film may be too thick or cracked.
- In a well-stained film the malaria parasites show deep red chromatin and pale blue cytoplasm.
- White cells, platelets and malaria pigment can also be seen on a thick film. The leukocyte nuclei stain purple and the background is pale blue. The red cells are lysed and only background stroma remains. The occasional red cell may fail to lyse.
- Schizonts and gametocytes, if present, are also easily recognizable.

- A thick film should be examined for at least 10 minutes, which corresponds to approximately 200 oil immersion fields, before declaring the slide negative.
- As a result of hemolysis of the red blood cells due to staining of an unfixed film, the only elements seen are leukocytes and parasites, the appearance of the latter being altered. Consequently:
 1. The young trophozoites appear as incomplete rings or spots of blue cytoplasm with detached chromatin dots.
 2. The stippling of *P. vivax* and *P. ovale* may be less obvious although occasionally ghost stippling may be seen.
 3. The cytoplasm of late trophozoites of *P. vivax* and *P. ovale* may be fragmented.
- Caution should be exercised when examining thick blood films as artifacts and blood platelets may be confused with malaria parasites.

Thin Blood Films

When examining thin blood films for malaria you must look at the infected red blood cells and the parasites inside the cells.

1. Rapid Field's Stain for Thin Films

This is a modification of the original Field's stain to enable rapid staining of fixed thin films. This method is suitable for malaria parasites, *Babesia* sp., *Borrelia* sp. and *Leishmania* sp.

Method

1. Air dry the film
2. Fix in methanol for one minute.
3. Flood the slide with 1 ml of Field's stain B, diluted 1 in 4 with distilled water.
4. Immediately, add an equal volume of undiluted Field's stain A, mix well and allow to stain for 1 minute.
5. Rinse well in tap water and drain dry.

Uses

This is a useful method for rapid presumptive species identification of malarial parasites. It shows adequate staining of all stages including stippling (mainly Maurer's dots). However, staining with Giemsa is always the method of choice for definitive species differentiation.

2. Giemsa Stain for Thin Films.

Method

1. Air dry thin films
2. Fix in methanol for one minute
3. Wash in tap water and flood the slide with Giemsa diluted 1 in 10 with buffered distilled water pH 7.2. The diluted stain must be freshly prepared each time.
4. Stain for 25-30 minutes.
5. Run tap water on to the slide to float off the stain and to prevent deposition of precipitate on to the film. Dry vertically.
6. Examine the film using the x100 objective.

Microscopic Features of the Thin Blood Film

1. Examine the tail end of the slide where the red cells are separated into a one-cell-layer thick.
2. An alkaline buffer pH 7.2 is vital for clear differentiation of nuclear and cytoplasmic material and to visualize inclusions such as Schüffner's / James's dots in the red cells. Acidic buffer is unsuitable.
3. The red cells are fixed in the thin film so the morphology of the parasitized cells and the parasites can be seen.
4. On a well stained film the chromatin stains red/purple and the cytoplasm blue. Leukocytes have purple nuclei. The red stippling, if present, should be clearly visible.

Infected Red Blood Cells

1. Look at the size of the infected red blood cells.
2. Are there any Schüffner's dots present or not?

Species	Stages found in circulating Blood	Appearance of Red Blood Cells	
		Size	Stippling
<i>Plasmodium falciparum</i>	Trophozoites Gametocytes	Normal	Maurer's dots or clefts infrequently seen
<i>Plasmodium vivax</i>	All: Schizonts Trophozoites Gametocytes	Enlarged, Maximum size may be 1.5-2 times normal	Schüffner's dots may be present
<i>Plasmodium ovale</i>	All: Schizonts Trophozoites Gametocytes	Enlarged, Maximum size may be 1.25-1.5 times normal	Schüffner's dots may be present
<i>Plasmodium malariae</i>	All: Schizonts Trophozoites Gametocytes	Normal	Ziemann's dots rarely seen

Table 9-1. Stages and appearance of *Plasmodium* species in blood. (SOURCE: CDC)

Species	<i>P. falciparum</i>	<i>P. vivax</i>	<i>P. malariae</i>	<i>P. ovale</i>
Host CELL				
Size	Not enlarged	Enlarged	Not enlarged	Enlarged
Shape	Round and sometimes crenated	Round or oval (frequently bizarre form)	Round	Round or oval, often fimbriated
Color	Normal but may become darkened	Normal but inclined to be pale	Normal	Normal
Stippling	Maurer's dots (large red spots)	Schüffner's dots (small red dots)	Ziemann's dots (few tiny dots not important for diagnosis)	James's dots (numerous small red dots)
Pigment	Usually black or very dark brown	Fine golden brown granules seen in cytoplasm	Black or brown coarse granules	Resemble more closely <i>P. malariae</i>
PARASITE				
General features	Small, compact dark, staining parasite. Multiple infections of single RBC	Large light staining parasite. Many trophozoites, may be amoeboid	Regular shape and moderate size. Strong tendency to form a band across the infected RBC	Regular shape. Size in between <i>P. vivax</i> and <i>P. malariae</i>
Common. Stages found in smear	Only rings and gametocytes	Trophozoites, Schizonts, Gametocytes	As in <i>P. vivax</i>	As in <i>P. vivax</i>
Ring stage	Delicate, small, 1.5 µm Double chromatin and multiple rings common. Accole, wing and marginal forms	Large 2.5 µm, usually single. Prominent thicker chromatin	Similar to <i>P. vivax</i> but thicker	Similar to <i>P. vivax</i> , more compact
Trophozoite	Compact, small, vacuole inconspicuous, seldom seen in smear	Large, irregular actively amoeboid prominent vacuole Chromatin as dots or threads	Characteristic band form, vacuole inconspicuous	Compact coarse pigment, chromatin as large irregular clumps
Schizont	Small, compact seldom seen in blood smear	Large, filling the RBC, segmented, yellow brown pigment	Nearly fills RBC, like segmented, daisy head, pigment is dark brown	Fills three fourth of RBC, segmented Dark yellow brown pigment
Micro-gametocyte	Larger than RBC, kidney shaped with blunt round ends, cytoplasm reddish blue, fine granules scattered, many in number in smear	Fills enlarged RBC, round or oval, compact cytoplasm, pale blue, Abundant brown granules	Smaller than RBC, very few in PBF, round compact, cytoplasm pale blue. Pigment and chromatin as in <i>P. vivax</i>	Of the size of RBC round, compact very few in PBF, cytoplasm pale blue, chromatin and pigment as in <i>P. vivax</i>

Table 9-2. Characteristics of Plasmodium parasites (SOURCE: CDC)

Rings of the four main species of malaria may look alike. If you see rings, look for older stages. Patients with a *P. falciparum* infection only, rings are usually seen; older stages are present only in severe infections.

In poorly stained slides, Schüffner's dots may not be visible, so it is essential that correct staining methods are used. Also Schüffner's dots may not be seen in the earlier rings of *P. vivax* or *P. ovale*.

Estimation of Percentage Parasitemia of *Plasmodium falciparum*

Counting of red blood cells infected with parasites of *P. falciparum* is essential and the percentage parasitemia should always be reported as this has implications for prognosis and the pattern of treatment employed.

The recommended procedure for estimating the percentage parasitemia in a thin blood film is by expressing the number of infected cells as a percentage of the red blood cells e.g. three parasitized red cells / 100 red blood cells or 3% parasitemia.

A red blood cell infected with multiple parasites counts as one parasitized red cell. The percentage parasitemia should be calculated by counting the number of parasitized red blood cells in 1000 cells in a thin blood film.

Method 2

Alternatively, the World Health Organisation recommends a method which compares the number of parasites in a thick blood film with the white blood cell count.

The parasitemia is estimated by first counting the number of parasites per 200 white blood cells in a thick blood film and then calculating the parasite count / μl from the total white blood cell count / μl .

Knowledge of either % parasitemia or total parasite count is essential for the correct clinical management of *P. falciparum* malaria.

Effects of Anticoagulant on the Microscopic Diagnosis of Malarial Parasites

Thin blood films for malaria diagnosis are best prepared from venous or capillary blood taken directly from the patient, without the addition of anticoagulant. However, this is not usually possible in a clinical laboratory, as many samples are received from general practices and other hospitals. All anticoagulants have some effect on the morphology of malaria parasites and the red blood cell they inhabit. This effect depends on the stage of the parasite, the time taken for the blood to reach the laboratory and the type of anticoagulant used. If it is necessary to use an

anticoagulant, the films should be prepared as soon as possible after the blood has been taken. If the films cannot be made immediately, potassium EDTA is the anticoagulant of choice. However if the blood is left for several hours in EDTA, the following effects may be seen.

1. Sexual stages may continue to develop and male gametocytes can exflagellate, liberating gametes into the plasma. These can be mistaken for organisms such as *Borrelia*. Gametocytes of *P. falciparum* which have a characteristic crescent shape, may round up and then resemble those of *P. malariae*.
2. Accole forms, which are characteristic of *P. falciparum*, may be seen in *P. vivax* because of attempted re - invasion of the red blood cell by merozoites.
3. Mature trophozoites of *P. vivax* may condense when exposure becomes prolonged and in cases of extreme exposure, red blood cells containing gametocytes and mature schizonts may be totally destroyed along with the contained parasites. The malaria pigment, hemozoin, always remains and can provide a clue to the presence and, to an expert eye, identity of the parasite.
4. The morphology of the red blood cell may be altered by shrinkage or crenation.

Malaria species	<i>P. falciparum</i>	<i>P. vivax</i>	<i>P. ovale</i>	<i>P. malariae</i>
Red Cell Changes	Maurer's dots	Schüffner's dots	James' Dots / Fimbriation	Ziemann's dots
Trophozoite – Ring form	Cytoplasm very fine in young rings; thick and irregular in old rings. Accole forms, multiple infections common.	Cytoplasm fine in young rings. Red cell unaltered in size.	Cytoplasm thicker than that found in <i>P. vivax</i> . Red cell unaltered in size.	Cytoplasm noticeably thicker. Red cell unaltered in size.
Trophozoite – Growing form	Red cell unaltered in size, sometimes stippled with Maurer's dots. Parasite is compact; pigment is dense brown or black mass.	Red cell enlarged, stippled. Parasite - ameboid, vacuolated; pigment fine and scattered, golden brown.	Red cell unaltered in size, or slightly enlarged. Stippled; may be oval and fimbriated. Parasite – compact, rounded; pigment fine brown grains.	Red cell unaltered in size. Parasite – compact, ugly, rounded or band-shaped; dark brown / black pigment often concentrates in a line along one edge of the band.
Mature schizonts	Red cell unaltered in size. Parasite – merozoites 8 – 36; pigment clumped, black. Rare in peripheral blood	Red cell much enlarged, stippled. Parasite – large, filling enlarged red cell. Merozoites 12 - 24, usually 16; pigment golden brown central loose mass.	Red cell slightly enlarged, stippled, frequently oval and fimbriated. Parasite – smaller than red cell. Merozoites 6 – 12, usually 8 in a single ring; pigment, brown / greenish central clump.	Red cell unaltered in size. Parasite – fills red cell. Merozoites 6 - 12, usually 8, sometimes forming a rosette; pigment, brown / black central clump.
Gametocytes	Red cell distorted. Parasite – crescent. Rare in early cases < 10 days.	Red cell enlarged, stippled. Parasite - large, fills red cell.	Red cell slightly enlarged, stippled. Parasite – round, filling 2/3 of the red cell.	Red cell unaltered in size. Parasite – small, round, fills the red cell.

Table 9-3. Differential diagnostic features of human *Plasmodia* species - Giemsa stained thin film of peripheral blood.

Chapter 10.

The Blood Nematodes

10.1 The Blood Nematodes

These nematodes are known as filariae and consist of a group of nematodes which have successfully invaded the blood stream, connective tissue or serous cavities of vertebrates. They are long thread –like nematodes.

Many of them are of medical and veterinary importance attacking man and various domestic animals being transported by various vectors, including mosquitoes. The nematodes from this order require intermediate hosts for the completion of their life cycle.

The morphology of these nematodes consist of a cylindroid pharynx with an anterior muscular portion and a posterior glandular portion; the males have well-developed alae (a flat, wing-like anatomic process or part) and spirally coiled tails.

Sexually mature female worms release microfilaria, which are pre-larval stages. These are released into the bloodstream. Most species are known to be ovoviviparous and some have 'sheathed' microfilaria.

The filarial nematodes which parasitize man consist of *Wuchereria bancrofti*, *Brugia malayi*, *Brugia timori* and *Loa loa*, *Onchocerca volvulus*, *Mansonella perstans*, *Mansonella streptocerca* and *Dipetalonema streptocerca*.

They inhabit a range of locations within the body; lymph glands, deep connective tissue, subcutaneous tissues or mesenteries. Invasions of these tissues usually result in inflammatory reactions which is a typical symptom of a human filarial infection. In some cases these result in fleshy deformities known as elephantiasis.

It has been estimated that approximately one billion people in tropical and subtropical countries are exposed to the risk of filarial infections and at least 200 million are infected with filariasis. The species which are primarily responsible for these human filarial infections are *Wuchereria bancrofti*, *Brugia malayi* and *Onchocerca volvulus*.

Wuchereria bancrofti

Introduction

Wuchereria bancrofti is a nematode causing lymphatic filariasis throughout the tropics and subtropics and is transmitted by the mosquito. There are two strains of *W. bancrofti*;

1. The nocturnal periodic strain which is widely distributed in endemic regions (i.e. Africa, India and the Far East and also parts of China, Korea and Japan) with the microfilariae being in their highest concentrations between the hours of 10pm and 2am.
2. The sub-periodic strain which is found in the Pacific region, and has a microfilaremia all the time with the highest numbers being detected between noon and 8pm.

Humans are the only known reservoir host of *W. bancrofti*. Infection rates in some communities in East Africa exceed 30% of adults causing revolting swellings of the legs or genital system, known as elephantiasis in man. The adult worm occurs in tightly coiled nodular masses in the major lymphatic ducts.

The main vector is *Culex quinquefasciatus*, a mosquito that is particularly common in towns and cities, breeding in organically polluted water, resting in houses and feeding by night on their human occupants. Typical breeding sites include: storm drains blocked with domestic refuse, accumulations of domestic waste water, inadequately covered septic tanks and pit latrines.

In rural areas throughout Africa, *Anopheles gambiae* and *Anopheles funestus* are involved in transmission. Elsewhere other anopheline mosquito species may transmit bancroftian filariasis in rural areas. In Papua New Guinea, *Mansonia* species may act as a vector.

Life Cycle

Microfilariae enter the host during a blood meal when the vector, a mosquito, punctures the skin. The infective larvae enter through the wound and migrate to the peripheral lymphatics where they grow to mature male and female worms. They can live there for several years. After mating, the gravid females release sheathed microfilariae into the peripheral blood where they can be detected 8-12 months after the initial infected bite.

The mosquito acquires the infection by ingestion of the microfilaria in the blood meal. The microfilariae lose their sheath on arrival in the stomach of the mosquito due to gastric juices. The larvae migrate to the thoracic muscles and develop into infective larvae over a period of 6-14 days. The larvae then migrate to the mouthparts of the mosquito which infects the host during a blood meal.

The blood stages of filariae, microfilariae, vary in the times when they are present in the peripheral blood, corresponding with the peak biting time of the vector. Thus, in nocturnally periodic forms the microfilaria are present in the peripheral blood circulation at night; during the day they reside in the deep tissues, particularly the lungs.

Filariasis

(*Wuchereria bancrofti*)

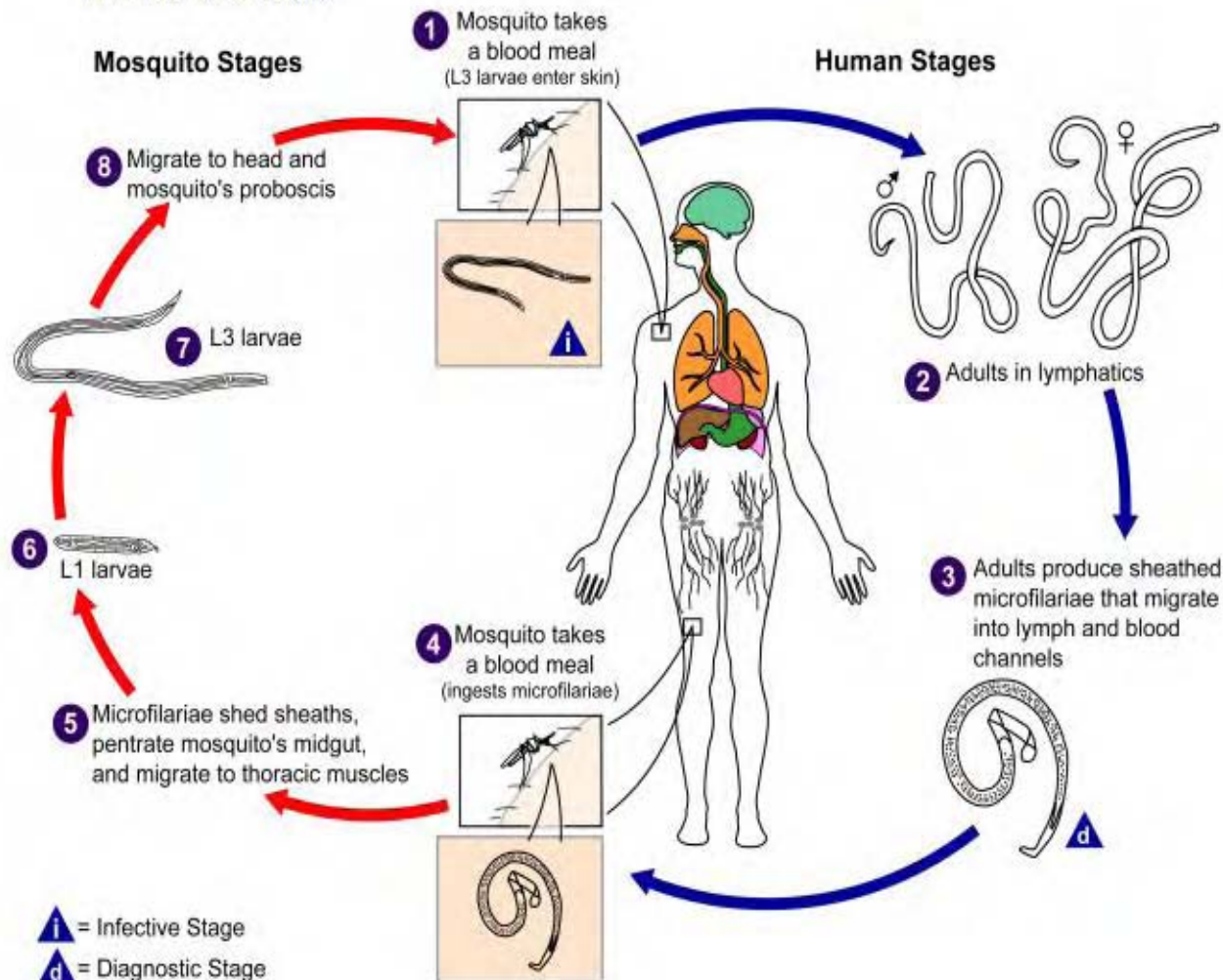


Illustration 10-1. Diagram showing the life cycle of *Wuchereria bancrofti*, the filarial nematode known to cause the disfiguring disease, elephantiasis, in man. (SOURCE: PHIL 3425 - CDC/Alexander J. da Silva, PhD/Melanie Moser)

Morphology

The adult worms are white and threadlike. The male measures between 2.5–4cm whereas the female is larger, measuring between 8-10cm.

The microfilariae are 230-275µm in length. The tail of the microfilariae of *W. bancrofti* tapers to a delicate point and exhibits no terminal nuclei. The sheath the microfilariae of *W. bancrofti* stains with hematoxylin stain.

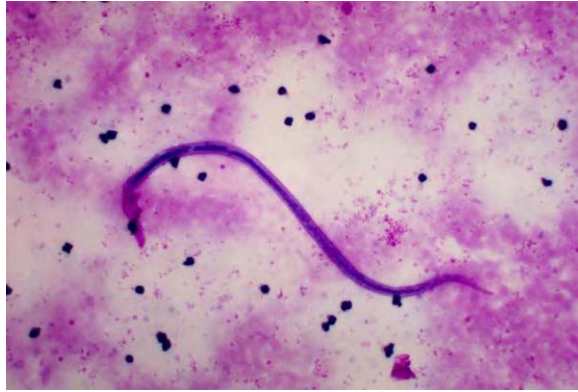

Image 10-1. Microfilaria of *Wuchereria bancrofti*. The microfilaria is sheathed, its body is gently curved, and the tail is tapered to a point. The nuclear column (the cells that constitute the body of the microfilaria) is loosely packed, the nuclei can be visualized individually and do not extend to the tip of the tail. (Micrograph) (SOURCE: PHIL 3008 - CDC/Dr. Mae Melvin)

Clinical Disease

Many patients are asymptomatic. Patients may present with fever, lymphangitis and lymphadenitis. Lymphangitis commonly affects the lower extremities and there may also be genital and breast involvement. An inflammatory reaction occurs in the lymphatic vessels that harbor the adult worms. Edema develops which may resolve after the first few attacks. A late complication resulting in thickening and verrucous changes in the skin known as elephantiasis may occur after recurring lymphangitis. Secondary bacterial and fungal infections may occur in patients with long-standing elephantiasis.

Obstruction of the genital organs may result in hydrocoele formation and scrotal lymphoedema. Obstruction of the retroperitoneal lymphatics may cause the renal lymphatics to rupture into the urinary tract producing chyluria.

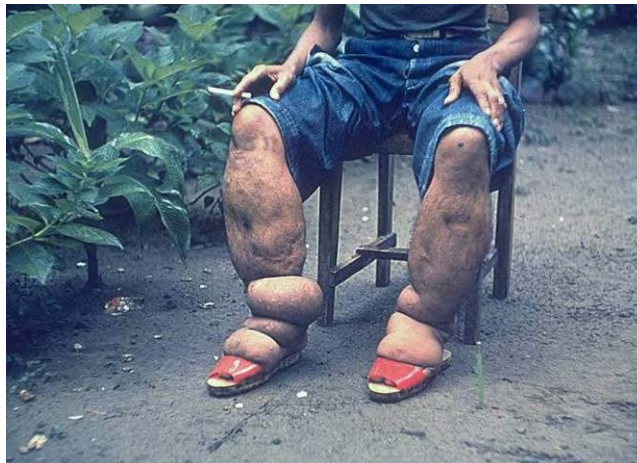

Image 10-2. Lymphatic filariasis: Elephantiasis is the last consequence of the swelling of limbs and scrotum. (SOURCE: PHIL 373 – CDC)

Some patients with filariasis do not exhibit microfilaremia but develop tropical pulmonary eosinophilia which is characterized by peripheral eosinophilia, wheeze and cough. High eosinophilia, high IgE level and high anti-filarial antibody titers are features of this syndrome.

Laboratory Diagnosis

See section 10.2 below

Sheath may or may not stain with Giemsa; does stain with hematoxylin stains. Discrete nuclei. Empty space between the nuclei and the body wall. No nuclei in tip of tail. Innerbody is rarely visible in Giemsa. Does not stain with hematoxylin. Cephalic space as long as it is broad. Tip of tail may be bent underneath the body. Found in blood.

Brugia malayi

Introduction

Brugia malayi is a nematode causing lymphatic filariasis in South East Asia. There are two strains of *B. malayi*;

1. The nocturnal periodic strain which is widely distributed in Asia, the microfilariae being in their highest concentrations between the hours of 10pm and 2am.
2. The sub-periodic strain which is found in Malaysia, Indonesia and the Philippines where humans exhibit a microfilaremia all the time with the highest numbers being detected between noon and 8pm.

Nocturnally periodic Brugian filariasis is primarily a rural disease, being transmitted by various *Anopheles* species of mosquitoes and also by *Mansonia* species, a mosquito that usually bites during the night.

Nocturnally sub-periodic *B. malayi* is transmitted almost exclusively by *Mansonia* species, often different species than those involved in transmitting the periodic form. *Mansonia bonnea* are important vectors in Malaysia, breeding in swamp forests and biting by night, although sometimes by day as well.

This species like *W. bancrofti* also parasitizes the lymph nodes and lymphatics; the adults of the two species are indistinguishable, causing Malayan filariasis.

Life Cycle

The adult worm inhabits the lymphatics and the female produces sheathed microfilariae which circulate in the peripheral blood. The mosquito acquires the infection by ingestion of the microfilaria in the blood meal. The microfilaria loses their sheath on arrival in the stomach of the mosquito. The larvae migrate to the thoracic muscles and develop into infective larvae over a

period of 6-14 days. The larvae then migrate to the mouth parts of the mosquito and enter the skin of the definitive host through the puncture wound when a blood meal is taken. The infective larvae enter the peripheral lymphatics where they grow to mature male and female worms.

Filariasis

(*Brugia malayi*)

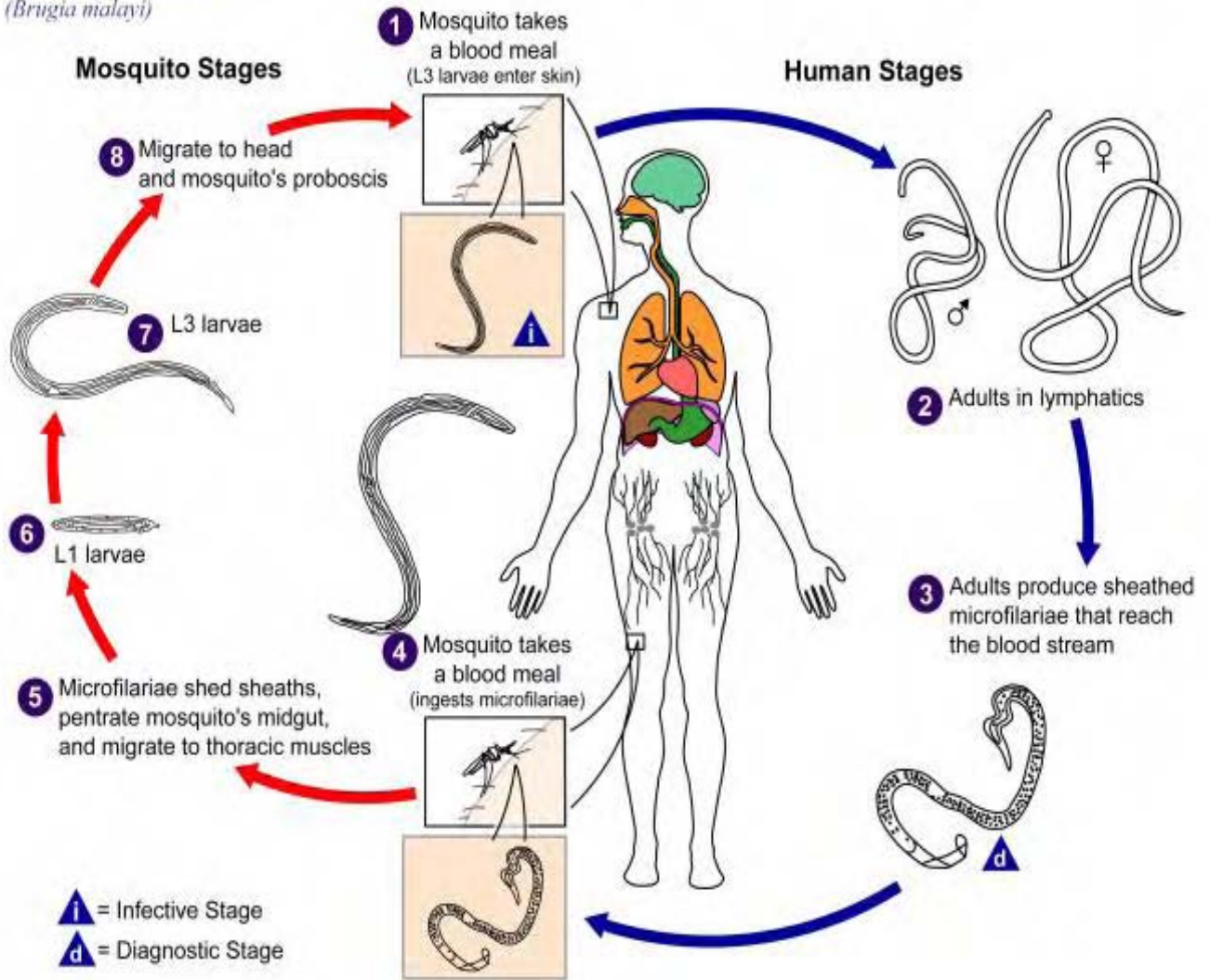


Illustration 10-2. Diagram showing the life cycle of *Brugia malayi*, a nematode which causes lymphatic filariasis. (SOURCE: PHIL 3379 - CDC/Alexander J. da Silva, PhD/Melanie Moser)

Morphology

The adult worms of *B. malayi* are smaller than those of *W. bancrofti*. The microfilariae of *Brugia malayi* are 170–230µm in length and have two terminal nuclei that are distinctly separated from the other nuclei in the tail. The last terminal nucleus is quite small and is at the tip of the tail. The sheath stains deep purple with hematoxylin stain.

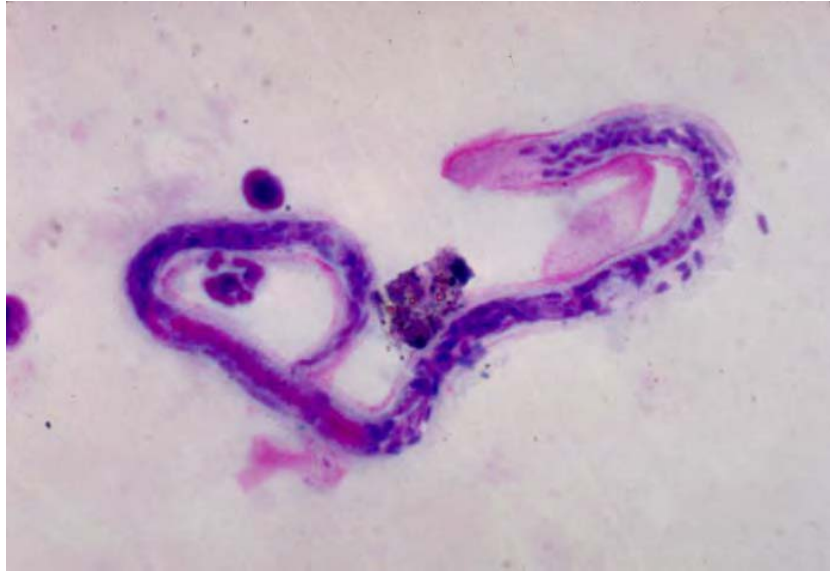

Image 10-3. Microfilaria of *Brugia malayi*. These microfilariae are sheathed measuring approximately 170–230 μ m in length and have 2 terminal nuclei that are distinctly separated from the other nuclei in the tail. The microfilariae in this species are tightly coiled, and the nuclear column is more tightly packed, preventing the visualization of individual cells. (Blood Smear) (SOURCE: PHIL 3003 - CDC/Dr. Mae Melvin)

Clinical Disease

Clinical features of *B. malayi* are similar to those of *W. bancrofti*, however in *B. malayi*, unlike *Wuchereria bancrofti*, genital involvement, hydrocoele and chyluria are rare.

Many patients are asymptomatic. Patients may present fever. Lymphaginitis and lymphadenitis develop in the lower extremities. An inflammatory reaction occurs in the lymphatic vessels that harbor the adult worms. Edema develops which may resolve after the first few attacks. However, in long standing disease after several episodes of lymphaginitis, thickening and verrucous changes in the skin known as elephantiasis occurs.

Some patients with lymphatic filariasis do not exhibit microfilaremia. However, they do have high eosinophilia, high IgE level and high anti-filarial antibody titers.

Laboratory Diagnosis

See section 10.2 below

Kinked microfilaria. Sheath stains deep pink with Giemsa stain. Does stain with hematoxylin stains. Nuclei crowded and fill the whole body. Empty space between nuclei and body wall. Cephalic space twice as long as it is broad. Innerbody may or may not stain; when it does, it is prominent. Found in blood.

Brugia Timori

Brugia timori is found in the islands of Indonesia and exhibits a strictly nocturnal periodicity. The lifecycle and disease closely resembles that of *Brugia malayi*. However, the microfilariae can be distinguished from those of *B. malayi* in that they are about 310µm in length. The sheath stains pink with Giemsa and the nuclei at the tip of the tail are similar to those of *B. malayi*

Loa loa

Introduction

Loa loa, also known as the African eye worm, is a filarial nematode endemic in the rain forests of West and Central Africa. It is transmitted by *Chrysops* species, also known as mango flies or horse flies and humans are the only known reservoir. It is estimated that 2-13 million humans are infected with the larvae.

Adults migrate in the subcutaneous tissues of man and monkeys, with them eventually migrating across the eyeball under the conjunctiva.

Life Cycle

Filariasis

(*Loa loa*)

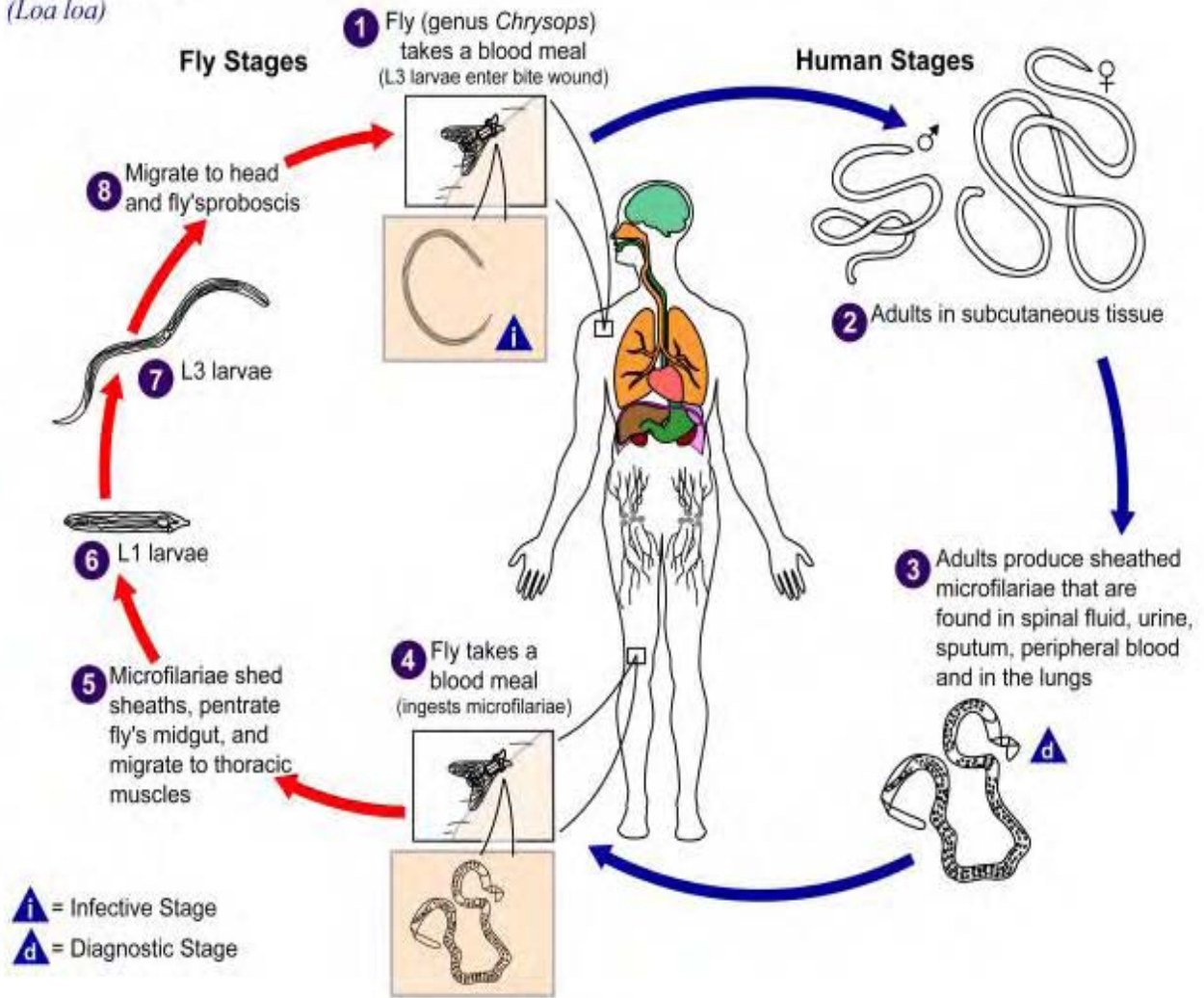


Figure 10-3. Diagram showing the life cycle of *Loa loa*, the African eye worm. (SOURCE: PHIL 3399 - CDC/Alexander J. da Silva, PhD/Melanie Moser)

The adult worms live in the subcutaneous and deep connective tissues and the microfilariae are found in the peripheral blood, where they can be ingested by the *Chrysops* fly (day biting fly). The adults can live in the tissues for up to 17 years.

Once the microfilariae have been taken up by the *Chrysops* during a blood meal they develop within the fat body. They develop through to L₃ within 10–12 days. The microfilariae, L₃ re-enter the host's blood stream when the fly takes another blood meal. They reach adult worms within 4–6 months living in the subcutaneous and deep connective tissues.

The microfilariae exhibit diurnal periodicity, the highest numbers being detected in blood between 10am and 2pm.

Morphology

Adult males of *Loa loa* are 2–3.5cm long and the females from 5-7cm. The microfilariae of *Loa loa* are 250-300µm. They possess a sheath which stains blue-grey with Delafield's hematoxylin. The sheath does not stain with Giemsa. The tail gradually tapers to a rounded end, the densely packed nuclei extending to the tip.

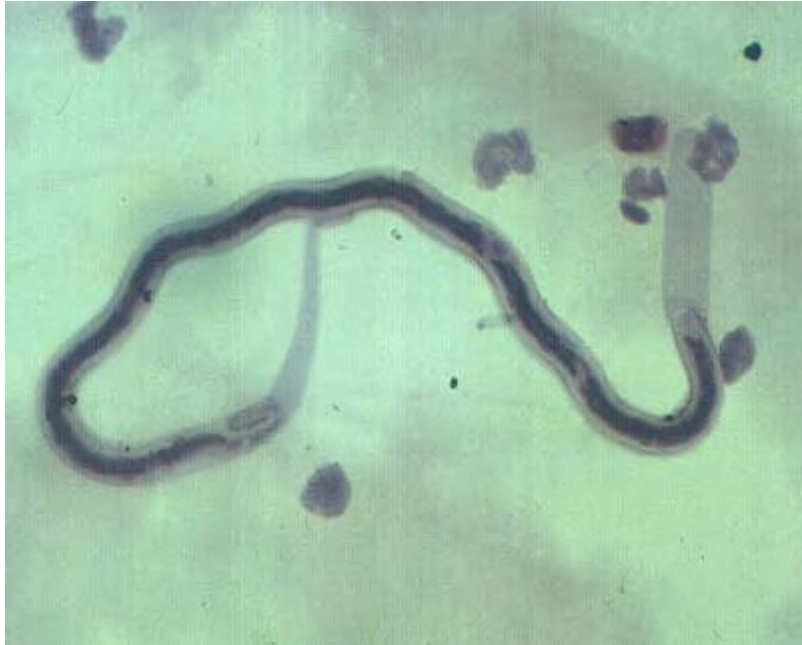

Image 10-4. Microfilaria of *Loa loa*, the African eye worm. The adult worms live in the subcutaneous and deep connective tissues and the microfilariae are found in the peripheral blood, The microfilariae are kinked and sheathed. Nuclei crowded extending to tip of tail; tip of tail tapers. (hematoxylin stain, x400) (SOURCE: Unknown)

Clinical Disease

Many patients infected with *Loa loa* appear to be asymptomatic and the migration of the adult worm through the subcutaneous tissues often goes unnoticed, unless passing beneath the conjunctiva of the eye. They can be seen crossing the eye, but it is a rapid process taking approximately 15–20 minutes. Hyperesinophilia and increased antibody levels, especially IgE are also noted. Eye-worm episodes are as equally common in man as well as women with common reoccurrences. There is an increased incidence with age.

The most common pathology associated with *Loa loa* infections are Calabar swellings, which are inflammatory swellings resulting in a localized subcutaneous edema. These swellings are due the host's response to the worm or its metabolic products and can be found anywhere in the body but most commonly in the extremities. These swellings last from 1–3 days. They develop rapidly and last one to three days, usually accompanied by localized pain, urticaria

and pruritis. There is a higher frequency of Calabar swellings in women with common reoccurrences.

Serious complications such as cardiomyopathy, encephalopathy, nephropathy and pleural effusion have been recorded.

Laboratory Diagnosis

See section 10.2 below

Kinked and sheathed microfilaria. Sheath does not stain with Giemsa stain; does stain with hematoxylin stains. Nuclei crowded extending to tip of tail; tip of tail tapers. Cephalic space as long as it is broad. Inner body does not usually stain. Found in blood.

***Mansonella* species**

Introduction

Members of the genus *Mansonella* are filarial nematodes which rarely cause serious disease. However, they can be found in geographical areas where *Wuchereria bancrofti*, *Loa loa* and *Onchocerca volvulus* also occur and therefore must be differentiated from these pathogenic microfilariae. Unlike the pathogenic blood filariae, they do not exhibit periodicity.

Life Cycle

Filariasis

(*Mansonella streptocerca*)

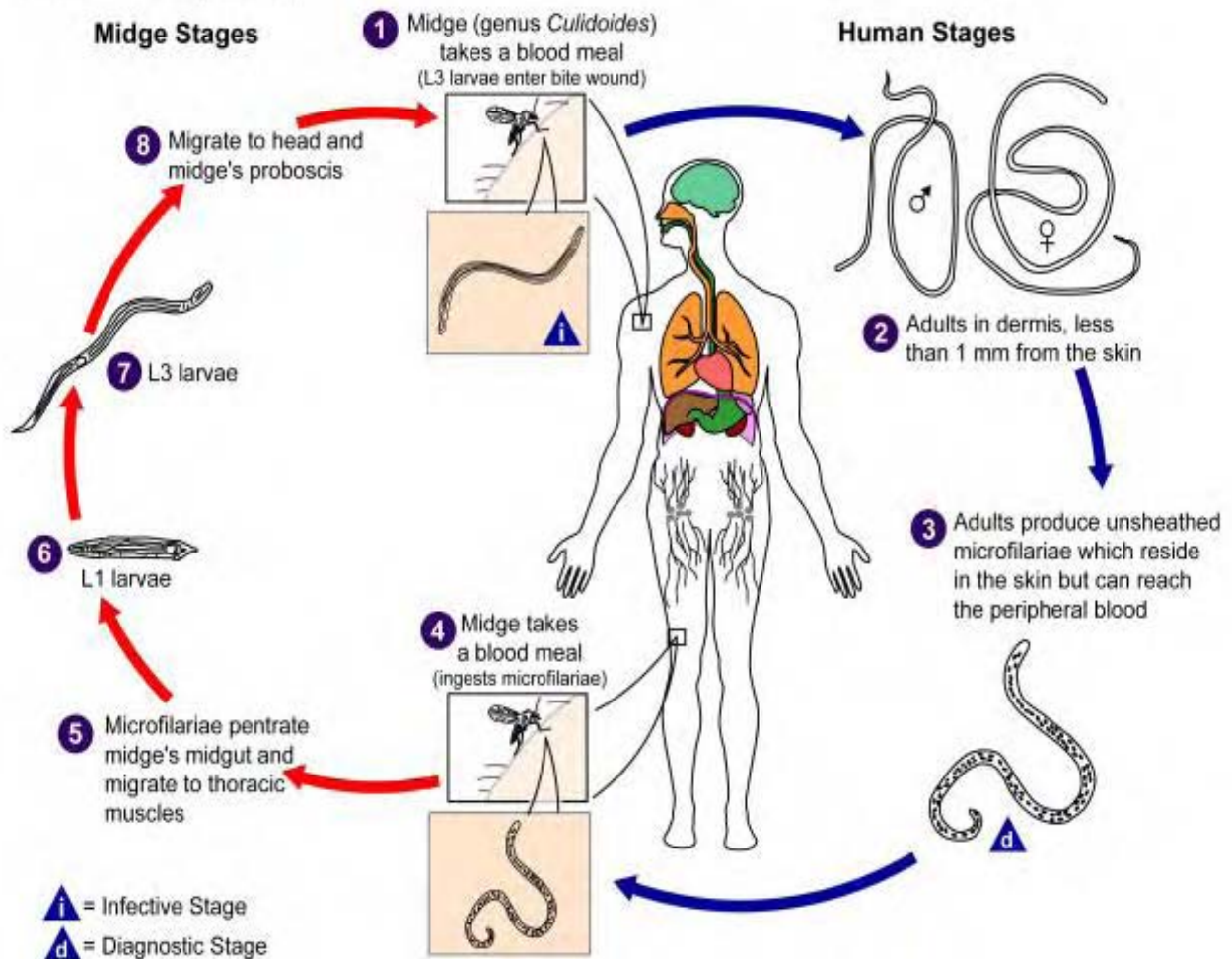


Image 10-4. General life cycle of *Mansonella* species of filarial nematodes. (SOURCE: PHIL 3404 - CDC/Alexander J. da Silva, PhD/Melanie Moser)

There is a general life cycle for the *Mansonella* species of filarial nematodes. The microfilaria is picked up by the vector *Culicoides* sp. (biting midges) during a blood meal. The larvae develop within the body of the *Culicoides* sp. and are re-introduced into the human host when the vector takes another blood meal. They are found in various sites around the human host body.

Mansonella perstans

The microfilariae of *M. perstans* have been found in Africa and South America. This is a mildly pathogenic species in man and apes. They are found in the deep connective tissue and serous cavities.

Morphology

The adult worms live in the peritoneal, pleural and pericardial cavities and their size is comparable to the pathogenic species already discussed. The microfilariae are unsheathed and are about 200µm in length and the nuclei extend to the tip of the tail which is rounded.

Clinical Disease

It is difficult to assess the disease associated with *M. perstans*, however pruritis, fever and subcutaneous swellings have been associated with infection of *M. perstans*. The adult worm appears to cause little or no host reaction. Eosinophilia is common.

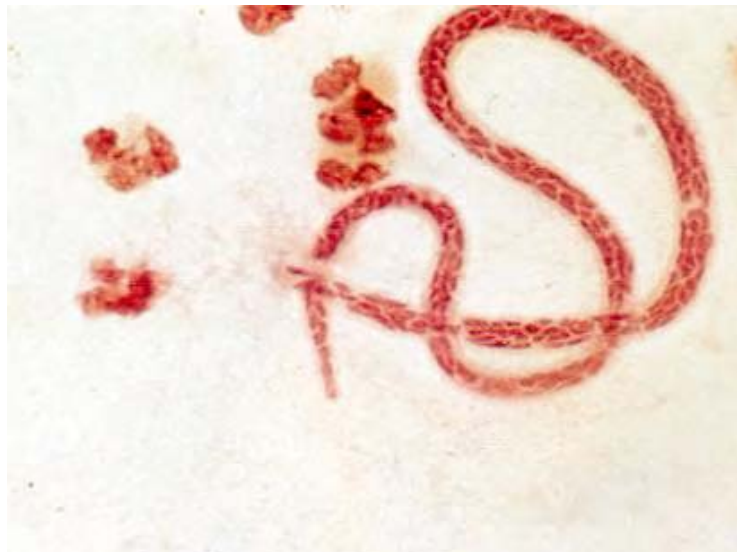

Figure 10-5. Microfilariae of *Mansonella perstans*, a mildly pathogenic nematode to man. The microfilariae are unsheathed and are about 200µm in length and the nuclei extend to the tip of the tail which is rounded. (Giemsa stained x920) (SOURCE: Unknown)

Laboratory Diagnosis

See section 10.2 below

Small, thin microfilaria. Does not have a sheath. Nuclei extend to end of tail; last nucleus bigger; tip of tail is blunt. Nuclei stain deeply and “run together”. Found in blood.

Mansonella ozzardi

Mansonella ozzardi nematodes are confined to the western hemisphere. These are non-pathogenic filarial nematodes. The parasites cause nodules in the skin of the vertebrate hosts.

Morphology

The adult worms are located in the mesenteric tissues and their size is comparable to the pathogenic species already discussed (0.6m long). The microfilariae are found in the peripheral blood and range between 173-240µm in length. The nuclei do not extend to the tip of the tail which has a pointed end. The male adult worm is almost unknown.

Clinical Disease

Infections caused by *M. ozzardi* are generally symptomless, however lymphadenopathy, arthralgia, fever and eosinophilia have been reported.

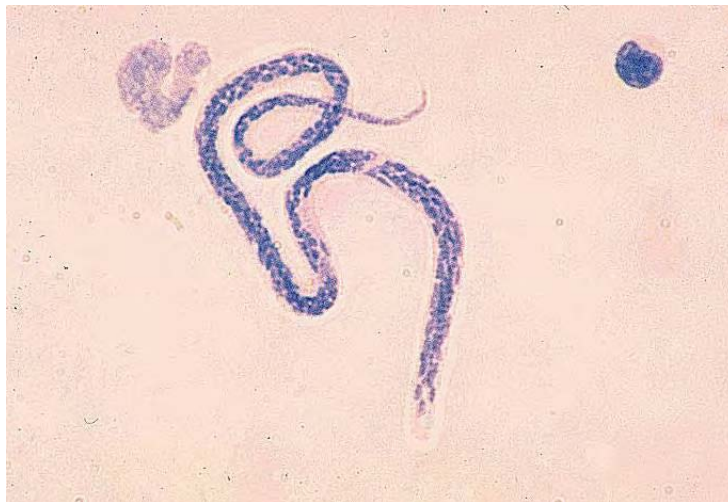


Image 10-6. Microfilariae of *Mansonella ozzardi*, Non-pathogenic filarial nematode to man. The microfilariae are found in the peripheral blood and range between 173 - 240µm in length. The nuclei do not extend to the tip of the tail which has a pointed end. (SOURCE: PHIL 382 - CDC/Dr. Mae Melvin)

Laboratory Diagnosis

See section 10.2 below

Small thin microfilaria. Does not have a sheath. Nuclei do not extend to end of tail; tip of tail tapers. Stains very lightly; tip of tail difficult to see. Found in blood and skin.

Species	Size of Microfilariae	Morphology of microfilariae
<i>Wuchereria bancrofti</i>	210 – 320µm by 8 - 10µm	Sheathed. Tail pointed and clear
<i>Brugia malayi</i>	170 – 260µm by 5 - 6µm	Sheathed. Tail pointed with 2 nuclei
<i>Loa loa</i>	230 – 300µm by 6 - 8µm	Sheathed. Tail blunt with nuclei
<i>Mansonella perstans</i>	200µm by 6µm	Unsheathed. Tail blunt with nuclei
<i>Mansonella ozzardi</i>	250µm by 6 - 7µm	Unsheathed. Tail pointed and clear

Table 10-1. Morphology of the blood microfilariae known to infect man. (SOURCE: CDC)

Species	Geographic distribution	Pathogenicity	Adults (site of infection)	Microfilariae (characteristics)	Vector
<i>Wuchereria bancrofti</i>	Asia, Pacific, Tropical Africa, Americas	Lymphangitis, fever, elephantiasis hydrocoele, chyluria	Lymphatics	Found in blood, sheathed, periodicity variable	Culicidae (mosquitoes)
<i>Brugia malayi</i>	South and East Asia	Lymphagitis, fever. Elephantiasis	Lymphatics	Found in blood, sheathed, nocturnally periodic or subperiodic	Culicidae (mosquitoes)
<i>Dipetalonema perstans</i>	Africa and South America	No definite pathogenicity	Peritoneal & pleural cavity	Found in blood, unsheathed, nocturnally subperiodic	<i>Culicoides</i> (biting midges)
<i>Dipetalonema streptocerca</i>	Africa (Ghana and Congo)	Cutaneous edema, elephantiasis	Subcutaneous tissues	Found in skin, unsheathed, nonperiodic	<i>Culicoides</i> (biting midges)
<i>Mansonella ozzardi</i>	Central and South America	No definite pathogenitis	Peritoneal cavity	Found in blood, unsheathed, nonperiodic	<i>Culicoides</i> (biting midges)
<i>Loa loa</i>	Tropical Africa	Skin swellings, allergic reactions	Subcutaneous tissues	Found in blood, sheathed, diurnally periodic	<i>Chrysops</i> (Tabanidae or Horse fly)
<i>Onchocerca volvulus</i>	Africa, Central and South America	Skin nodules, ocular complications (blindness)	Subcutaneous tissues	Found in skin, unsheathed, nonperiodic	<i>Simulium</i> (Black fly)

Table 10-2. Comparison of the main human filarial nematodes. (SOURCE: CDC)

10.2. Laboratory Diagnosis

Detection of Microfilariae in Blood

Collection of specimens

The specimen collection times should be selected in accordance with the patient's clinical symptoms and travel history.

Species	Geographic location	Periodicity	Collection time
<i>Wuchereria bancrofti</i>	Tropics / Subtropics	Nocturnal	2400 hours
<i>Wuchereria bancrofti</i>	Pacific	Diurnal subperiodic	1600 hours
<i>Brugia malayi</i>	SE Asia and SW India	Nocturnal	2400 hours
<i>Brugia malayi</i>	Indonesia	Nocturnal subperiodic	2100 hours
<i>Brugia timori</i>	Indonesia	Nocturnal	2400 hours
<i>Loa loa</i>	West / Central Africa	Diurnal	1300 hours
<i>Mansonella perstans</i>	Africa / South America	Non periodic	Any time
<i>Mansonella ozzardi</i>	Central & South America	Non periodic	Any time

Table 10-3. Periodicity and the advised collection times of the human filarial nematodes. (SOURCE: CDC)

Detection Methods

(i) Polycarbonate membrane filtration.

This technique is very sensitive, enabling very low parasitemias to be detected. It is now the most widely used technique for separating microfilariae from blood.

Nucleopore polycarbonate membranes, 25µm diameter, 5µm pore size, are held in a Millipore Swinnex filter holder, using a rubber gasket to secure the membrane.

Method

- a) Place the membrane on the holder with a drop of water.
- b) Draw up 10-20 ml of 1:1 saline diluted blood into a 20ml syringe
- c) Connect the syringe to the filter and *gently* push the blood through the filter membrane.

- d) Repeat until all of the blood has been filtered.
- e) Draw up 20 ml of saline into the syringe, flush through the filter, repeat using air.
- f) Unscrew the top of the filter and discard the gasket into chlorox; use forceps to transfer the membrane to a slide.
- g) Add a drop of saline to the membrane and cover with a coverslip.
- h) Examine the membrane under the microscope, using a x10 objective. Examine any microfilariae found using a x40 objective to note the presence of a sheath.

(ii) Saline/saponin method.

Reagent

One percent saponin in normal saline.

Method

- a) Deliver 2ml of blood (fresh or anticoagulated) into a centrifuge tube and add 8ml of 1% saponin in saline.
- b) Mix the blood by inversion, then allow it to stand at room temperature for 15 minutes to allow the blood to hemolyze.
- c) Centrifuge at 2,000rpm for 15 minutes to deposit the microfilariae.
- d) Discard the supernatant and use the deposit to make a wet preparation.
- e) Examine the slide using the x10 objective. Active microfilariae can be seen and produce a snake-like movement as they disturb the cell suspension.

If it is not easy to inspect the microfilariae due to excess “wriggling” a little 10% formalin can be run under the coverslip to immobilize them.

Confirmation of species can be made by using appropriate staining methods to demonstrate nuclear morphology.

Staining Methods for Microfilariae

When filariasis is suspected, a geographical and clinical history helps to determine the most appropriate collection time. Thick and thin blood films can be examined. However this is an insensitive method due to the low microfilaremia, and larger volumes of blood need to be examined.

There are 4 characteristics that are generally used in diagnosing microfilaria:

1. The presence or absence of a sheath.
2. The presence or absence of nuclei in the tip of the tail.
3. The innerbody – can or cannot be demonstrated.
4. The size of the microfilaria.

The two methods commonly used are:

(i) Supravital Staining

Reagent

0.75% cresyl blue in saline or 1.0% methylene blue in saline.

These reagents can be used to stain live microfilariae by allowing the stain to flow under the coverslip on to a polycarbonate membrane preparation or a centrifuged preparation. The dye will stain the nuclei of the microfilariae and also provide a contrasting background to look for a sheath. It may take several minutes for the dye to penetrate the organisms and the slide should be kept in a moist chamber to prevent the preparation from drying out.

(ii) Permanent Staining

Permanent stains should show up the nuclei, including the pattern of nuclei in the tail region and stain the sheath if necessary.

The stains of choice are;

1. Hematoxylin
2. Giemsa
3. Rapid Field's

1. Hematoxylin

Delafield's hematoxylin will stain the nuclei and the sheath well and unlike Ehrlich's hematoxylin does not require heating

Reagents

- Delafield's hematoxylin (BDH)
- 1% acid alcohol
- Methanol

Method

- a) Make thin films, allow to air dry then fix in methanol for five minutes
- b) Stain with Delafield's hematoxylin for 20 minutes
- c) "Blue" the nuclei by placing the slide in a coplin jar and allow a stream of running water to flow into the jar for 20 minutes.
- d) Decolorize with 1% acid alcohol for 5-10 seconds before "blueing" in tap water again. Control this process by examination under the microscope until the nuclei are clear and distinct.
- e) Allow the slide to dry before mounting in DPX.
- f) The nuclei should stain blue and the sheath grey.

2. Giemsa

Reagents

- Methanol
- Giemsa stain
- Immersion Oil

Method

- a) Make a thin film and allow to air dry.
- b) Fix in methanol for one minute.
- c) Tip off the methanol and flood the slide with Giemsa stain diluted 1:6 with buffered distilled water pH 6.8. The diluted stain must be freshly prepared each time.
- d) Stain for 20 – 25 minutes.
- e) Run buffered water on to the slide to float off stain and to prevent deposition of precipitate on to the film. Allow the slide to drain dry.
- f) Examine the film using the oil immersion objective. Nuclei should stain red

3. Rapid Field's

Reagents

- Methanol
- Field's Stain A solution

- Field's Stain B solution
- Immersion Oil

Method

- a) Make thin film and allow to air dry for five minutes.
- b) Fix the smear in methanol for one minute.
- c) Flood the slide with 1ml of Field's stain B (diluted 1:4 with distilled water)
- d) Immediately add an equal volume of Field's stain A, mix well on slide and allow to stand for one minute.
- e) Rinse well in tap water and drain dry.
- f) Examine the film using the oil immersion objective and immersion oil.
- g) The nuclei should stain red.

10.3 Microfilaria Worms Found in Tissue and Skin

The main species of microfilariae found in the skin and tissue are *Onchocerca volvulus* and *Mansonella streptocerca*. Microfilariae of *Onchocerca volvulus* and less often, *Mansonella streptocerca* migrate through the dermis causing itching and skin texture changes and occasionally arrive in the eye where they cause blindness. Detection of these microfilariae is from skin snips or nodule biopsies. When high numbers of microfilariae are present, they can occasionally be found in the blood and urine.

Onchocerca volvulus

Introduction

Onchocerca volvulus is mainly found in West Africa and Central and South America. Onchocerciasis, also known as river blindness, is a major public health problem, especially in West Africa despite the fact that an eradication program has been established. It is one of the world's most distressing diseases of helminth origin, often resulting in blindness. *Onchocerca volvulus* is transmitted by the species *Simulium* or black fly whose breeding habitat is by fast flowing rivers or streams, therefore there is a patchy distribution of the disease as it is specified to where water courses are. The adult worms are found in nodules or onchodermata in superficial sites, but may invade other tissues. It is estimated that there are 18 million cases worldwide with 17.5 million being found in Africa. Nigeria is the most infected region. The rate of morbidity is high in relation to those with an infection.

Life Cycle

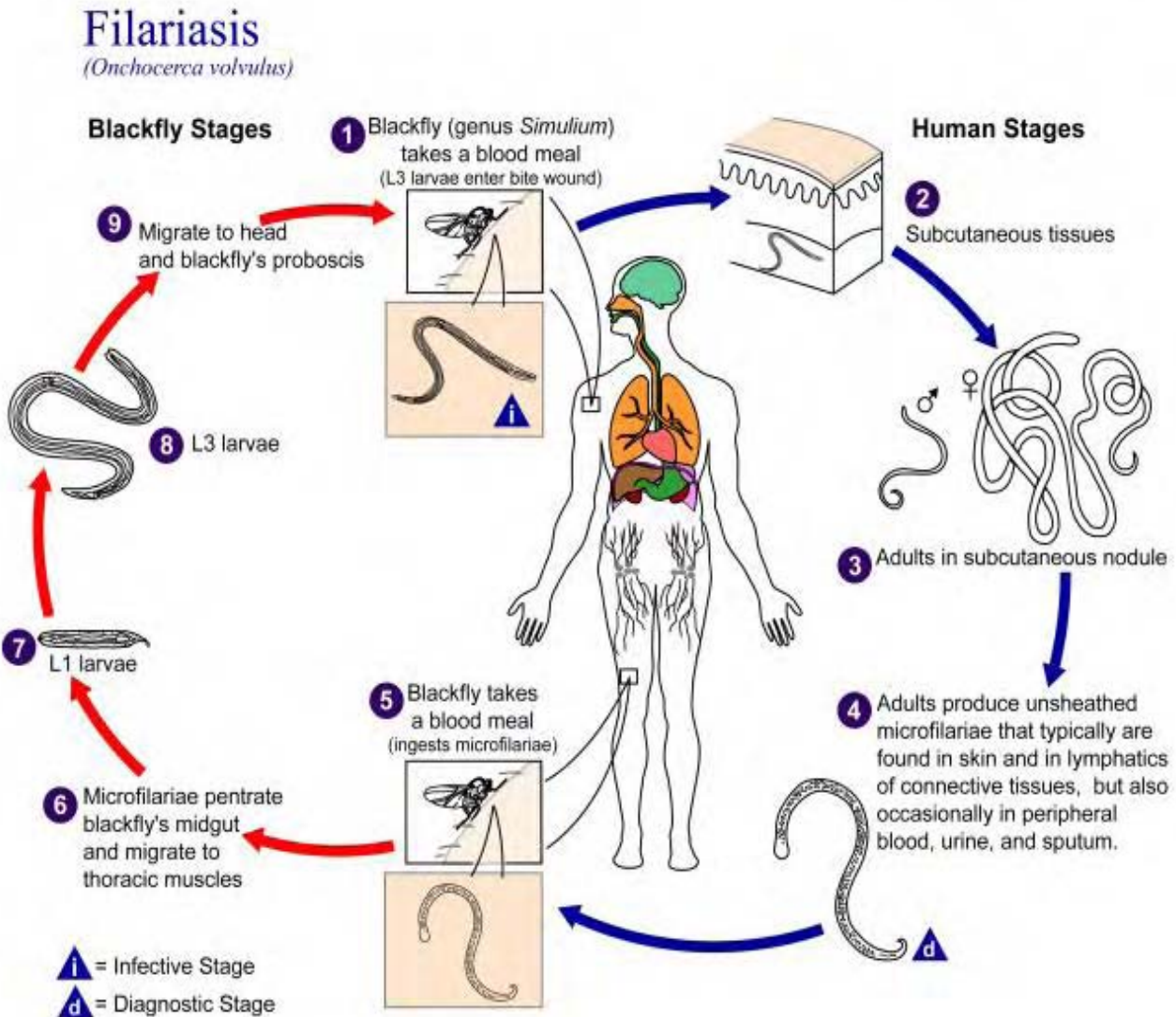


Illustration 10-5. Diagram showing the life cycle of *Onchocerca volvulus*, a filarial nematode which causes onchocerciasis, or River blindness. It is known as river blindness due to the vector, *Simulium damnosum*, breeding in fast flowing rivers. (SOURCE: PHIL 3413 - CDC/Alexander J. da Silva, PhD/Melanie Moser)

The life cycle is similar to *W. bancrofti*, except that the intermediate hosts are various species from the genus *Simulium* (Black flies), the most important species is *Simulium damnosum*.

The microfilariae are ingested by a Black fly during a blood meal, from where they are carried to the midgut where they penetrate the epithelium and migrate, via the hemocoel, to the indirect flight muscles. Here they undergo two molts, L₁–L₃ and develop into infective L₃ larvae which move to the mouth parts. Development is completed in 6–9 days.

When the infected fly takes another blood meal the infective larvae are once again transmitted into another host (definitive host). The microfilariae are released from the mouth parts and

transmitted directly into the hosts bloodstream. Molting takes place from L₃ - L₄ within 2-5 days and the larvae then migrate widely through the body under the skin and between muscles, ligaments and tendons. The final molt to L₅ occurs at 1.5–2.5 months after transmission. Male worms are known to mature in about four months later. Female worms initiate the formation of the nodules and the males may join later. The sexually mature female worms release microfilariae which migrate out from the nodules into the skin and other tissues, most significantly into the eye.

Morphology

The whitish adult worm lies coiled within capsules in the fibrous tissue. The female can measure up to 50cm while the males are shorter measuring up to 5 cm. The microfilariae of *O. volvulus* are unsheathed and are usually found in the dermis. They measure between 221-287µm long.



Image 10-7. *Onchocerca volvulus* microfilariae after being released by the adult female worm. They escape to the subcutaneous tissues and the eye and can be recovered with blood-free skin snips. (SOURCE: CDC)

Clinical Disease

Clinical manifestations are due to microfilariae in the epidermis.

Light infections may be asymptomatic or cause pruritis. This leads to scratching which can result in infection. Lymphadenopathy may also be a feature of early infection. After months or years, onchodermatitis results in secondary stage of thickening due to intradermal edema and pachydermis. There is a loss of elastic fibers resulting in hanging groin, hernias and elephantiasis of the scrotum. There is finally atrophy of the skin resulting in loss of elasticity. There is mottled depigmentation of the skin.

Ocular lesions are related to the intensity of the microfilariae in the skin. Ocular lesions include sclerosing keratitis, secondary glaucoma and cataract, coroidoretinitis and fluffy corneal opacities. The major complication of onchocerciasis is the development of lesions in the eye which may result in blindness or other distressing ocular diseases.

Laboratory Diagnosis

1. Analysis of Skin Snips

Small amounts of skin are collected by using a needle to raise the skin and then to slice about 1 mg of skin to a depth of 0.5µm. Snips are collected from several sites, usually the shoulders or the buttocks and sometimes the chest and calves. The snips are placed immediately in 0.5ml normal saline in a microtiter plate and left for 4 hours to allow the microfilariae to migrate out of the tissues. After four hours, the wells are examined using an inversion microscope. The microfilariae should still be moving and can be identified from the table below. The microfilariae can also be collected by filtration or centrifugation and the deposit containing microfilariae can be stained with Giemsa at pH 6.8.

2. Analysis of Biopsies

Biopsies of tissue nodules can be dabbed on to a slide to produce impression smears and then stained with Giemsa stain at pH 6.8 for the presence of microfilariae.

Recent advances in diagnostic methods includes and ELISA-based antibody detection assay which utilizes a cocktail of recombinant antigens. The advantages of using this test is that it is highly sensitive (almost 100% in onchocerciasis foci). It is also highly specific (100%), it also uses finger prick blood. Therefore, reducing the painful procedure of gaining a skin snip.

The disadvantages is that it requires advanced ELISA apparatus and reagents and cannot distinguish between past and present infections due to it detecting antibodies which stay present in the body for a long time after the infection. Another modern detection method is for Parasite DNA detection, which is based on the amplification of specific DNA sequences from microfilariae using molecular biology technology. The advantages of this technique is its exquisite sensitivity and detects active infections only. The disadvantages are that it requires specialized equipment and expensive reagents. Also it still requires a skin snip but a urine assay is a possibility for the future.

Thick microfilaria. Does not have a sheath. Head often spatulate. Nuclei do not extend to tip of tail. Found only in skin.

Mansonella streptocerca

Introduction

Microfilaria of *M. streptocerca* were first reported in the skin of a West African patient in 1922. These microfilaria are primarily found in the skin but have been also reported in the blood. This

species occurs in Ghana, Cameroon and Zaire. The adults are poorly known, and occur in the cutaneous tissue of man and chimpanzee.

The microfilariae do not exhibit periodicity with the intermediate hosts being *Culicoides grahamii* and possibly other *Culicoides* species.

Life Cycle

The life cycle is the same as that of the blood *Mansonella* species.

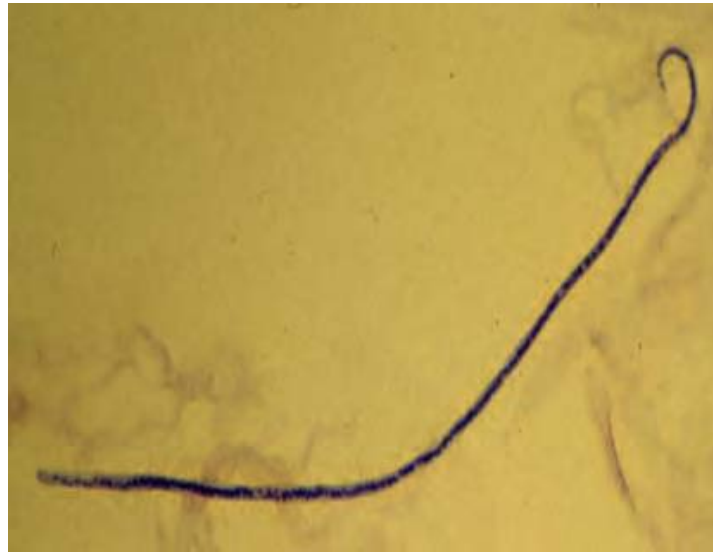


Image 10-8. Microfilaria of *Mansonella streptocerca*. From a skin snip, after a concentration procedure and hematoxylin stained. The microfilaria is typically unsheathed, and its body has a straight attitude. The tail is typically coiled ("shepherd's crook"), and nuclei extend to the end of the tail, as a single-cell row. (SOURCE: CDC)

Clinical Disease

Infection is characterized by pruritic dermatitis and hypopigmented macules.

Laboratory Diagnosis

Mansonella streptocerca can be diagnosed by demonstrating the microfilaria in a skin snip. Snips are collected from several sites, usually the shoulders and buttocks and sometimes the chest and calves. The snips are placed immediately in 0.5ml of 0.9% sodium chloride in a microtiter plate and left for four hours to allow the microfilaria to migrate out of the tissues. After four hours, the wells are examined using an inversion microscope. The microfilaria should still be moving and can be identified by staining with Giemsa at pH 6.8

Small, thin, microfilaria. Does not have a sheath. Nuclei extend to end of tail. Tail is hooked; its tip is rounded or forked. Found only skin.

Species	<i>Onchocerca volvulus</i>	<i>Mansonella streptocerca</i>
Distribution	Tropical Africa, Central and South America	West Africa
Vector	<i>Simulium</i> spp.	<i>Culicoides</i> spp.
Adult location	Subcutaneous nodules	Cutaneous connective tissue
Microfilariae location	Skin	Skin
Microfilariae size	280 - 330µm	180 - 240µm
Morphology	Broad spatulate head; No sheath, pointed tail	Curled tail; No sheath
Tail nuclei	Tail free from nuclei	Nuclei extend to tail tip

Table 10-4. Differential features of *Onchocerca volvulus* and *Mansonella streptocerca*._(SOURCE: CDC)

Dracunculus medinensis

Introduction

Dracunculus medinensis is a non-filarial parasite as it only has one uterus whereas filaria have two. It is usually associated with places where there is a lack of clean drinking water e.g. step wells in India, covered cisterns in Iran, and ponds in Ghana. The life cycle usually involves copepod intermediate host. They are parasitic in the connective tissue or coelom of vertebrates. The disease associated with this parasite is known as Dracunculiasis.

Life Cycle

Dracunculiasis

(*Dracunculus medinensis*)

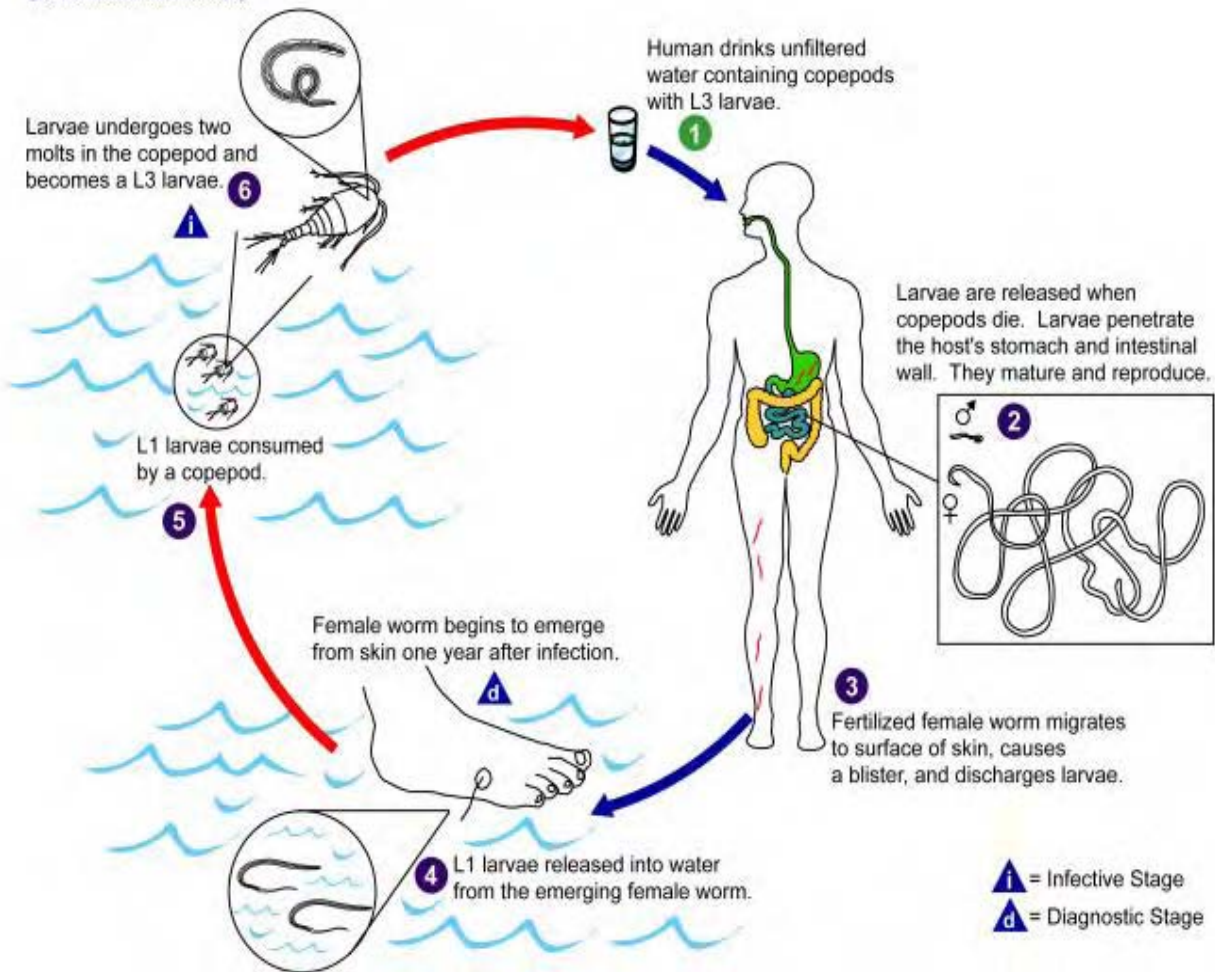


Illustration 10-6. Diagram showing the life cycle of *Dracunculus medinensis*, Guinea worm. (SOURCE: PHIL 3391 - CDC/Alexander J. da Silva, PhD/Melanie Moser)

Mature female worms which are gravid with microfilariae migrate to the superficial layers of skin of humans, especially those regions which are most likely to come in contact with water, such as the ankle, foot, arms and shoulders. Here the worms secrete a substance (substance is unknown) which causes a blister to rise over its anterior end where it has pierced the lower layers. The blister eventually forms into an ulcer which on contact with water, the uterus is projected out of the ulcer cavity, and a cloud of milky white secretion, containing hundreds of active larvae, is released. Once out of the water again the uterus dries and shrivels preventing the release of further larvae.

If the microfilariae are ingested by an appropriate species of *Cyclops*, they break through the soft mid-intestine wall and come to lie in the body cavity. The larvae undergo two molts and become infective in approximately three weeks. Humans become infected by accidentally ingesting through drinking water the infective *Cyclops*. Upon ingestion the larvae are activated to penetrate through the gut wall, and migrate through the tissues, molting twice and finally

becoming lodged in the viscera or subcutaneous tissues. Maturation of the worms is slow taking about one year to reach sexual maturity before the females are ready to migrate to the skin to release their larvae.

Morphology

The adult female worm measure up to one meter in length whereas the male measures about 2cm.

Clinical Disease

After ingestion of the Cyclops, there is no specific pathology associate with the mucosal penetration and larval maturation in the deep connective tissues. Erythema and tenderness can be associated with blister formation. The patient can also exhibit vomiting, diarrhea, asthmatic attacks. Symptoms usually subside when the lesion erupts. If the worm is removed, healing usually occurs without any problems. If the worm is damaged or broken during removal, there may be intense inflammatory reaction with possible cellulitis along the worms migratory tract. This can result in arthritis and synovitis.

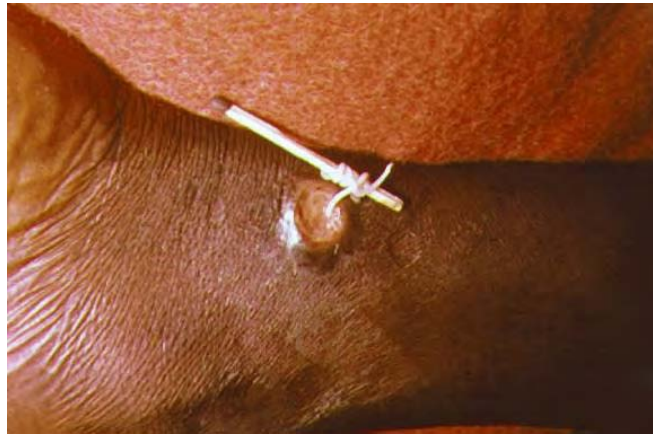

Figure 10-9. Female *Dracunculus medinensis* worm (Guinea worm) emerging out of a typical ulcer. Adult worms emerge from these ulcers on contact with water to release their microfilaria. The most effective method for removing these worms are to slowly wind them around a piece of stick, being careful not to break the worm in two. (SOURCE: PHIL 1342 – CDC)

Laboratory Diagnosis

The best remedy for removing the adult worm is a slow process of daily gently rolling the worm around a small stick and slowly pulling it out of the skin. With this method you must be careful not to pull apart the worm as it will recoil back into the skin and cause secondary infections.

This parasite is currently being approached with a strict control program. The program includes stopping people from drinking infected water, putting muslin over water collection jars, educating the communities about the parasite, and adding templos to the water to kill it off.

Chapter 11.

Babesia, Trypanosomes, and Leishmania

***Babesia* species**

Introduction

Babesia species are protozoan parasites of domestic and wild animals. They belong to the subclass Piroplasmia and are commonly referred to as 'piroplasms' due to the pear-like shaped merozoites which live as small intra-erythrocytic parasites. They commonly infect mammals, particularly cattle, sheep, goats, horses, pigs, dogs and cats and occasionally man.

Species infective to humans are the cattle form *Babesia bovis* which can often be fatal and *Babesia microti* which is less pathogenic. Until recently *B. microti* was confined to the United States but is now becoming a significant tick-borne disease of man in other temperate climates as well.

Human infections have been found in Europe and North America. The infection is known as Babesiosis, it can also be described as 'redwater fever' or 'tick fever' and has a major impact on the livestock industries in many countries.

What is unusual with this parasite's life cycle is the development in the vector. They use the one-host ticks, belonging to the genus *Boophilus*. The parasites are passed to the eggs and hence to the larval stages which can thus become infective after the adult tick dies. This process is known as transovarial transmission.

The ticks which are known to carry the parasite of *Babesia bovis* are *Boophilus microplus*, *B. decoloratus* and *B. annulatus*.

Life Cycle

Human babesiosis is a zoonosis, acquired by tick bite when individuals accidentally interact with the natural life cycle of the parasite.

The life cycle is best known for *Babesia canis* which infects dogs, but it is generally the same in each of the one-tick hosts and the definitive host.

Babesia bovis

When the tick bites, **sporozoites** are injected into the blood stream and penetrate the erythrocytes. In contrast to the malaria life cycle, there is no tissue stage for *Babesia bovis*. *Babesia* multiplies in the red cell by budding in contrast to schizogony in *Plasmodium* species. The red cell ruptures and daughter parasites invade new erythrocytes for further asexual multiplication. Some of the **sporozoites** injected by the tick vector follow a different path of intra-erythrocytic development, growing slowly and "folding" to form accordion-like structures which are destined to undergo further development in the tick vector. Within the intestine of the tick, the accordion-like stage eventually fuses with another, to form a **zygote**. Further development outside the intestine occurs in a variety of tissues, the salivary glands and ovaries being especially important for transmission. **Sporozoites** in tick salivary glands are injected into the mammalian host at the next blood meal. Transovarial transmission of *Babesia bovis* also takes place so that newly hatched onto adult stages can then take place.

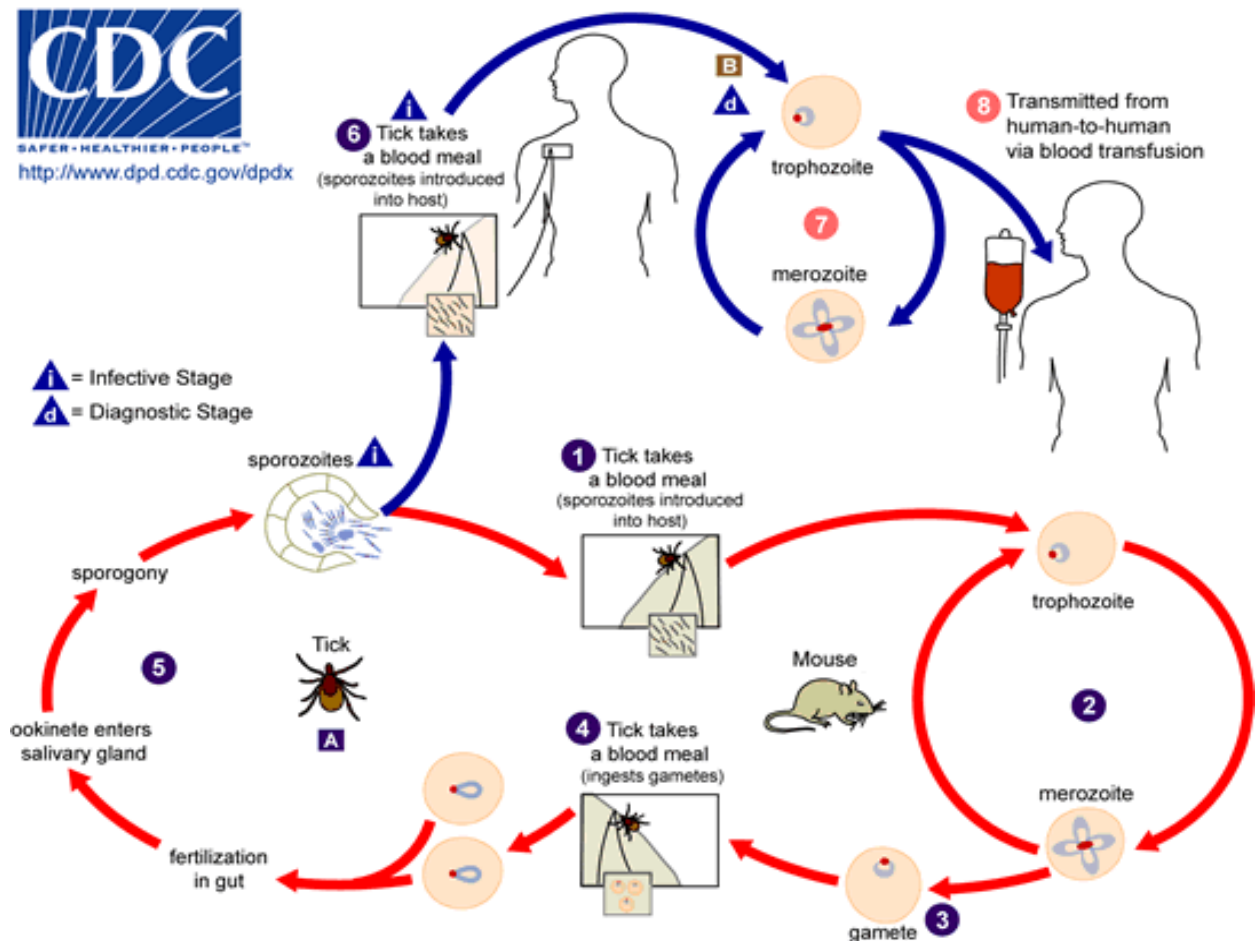


Illustration 11-1. Generalized life cycle of the parasite *Babesia*, which causes the disease babesiosis in man. (SOURCE: CDC/DPDx)

Babesia microti

In the small mammal host of *Babesia microti*, **sporozoites** from the tick vector first enter lymphocytes and undergo **merogony**, the daughter parasites of which then enter erythrocytes.

Babesia microti do not undergo transovarial transmission, but once a larva has become infected from a mammalian host they are able to pass on the infection transstadially to the nymph.

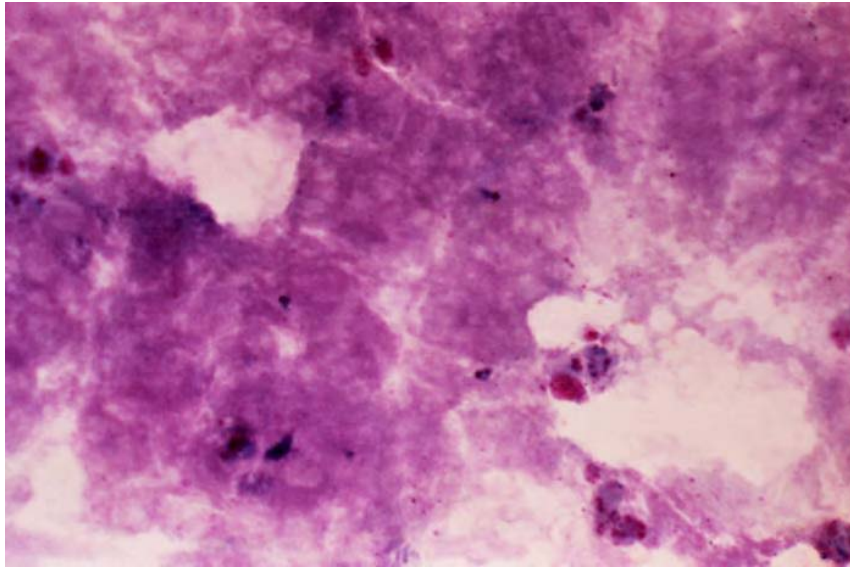


Image 11-1. Diagnosis of *Babesia* species depends on the observation of the intraerythrocytic organisms in blood smears. Pear shaped microorganisms (2-5µm) and tetrads are the diagnostic shape of the parasite. (SOURCE: PHIL 3899 – CDC/Dr. George Healy)

Clinical Disease

Babesia bovis - Patients who are particularly at risk are those who have had a splenectomy. The patient may feel vaguely unwell at first but by the time the diagnosis has been made, is usually very ill, with fever, prostration, jaundice, anemia and hemoglobinuria. Nausea, vomiting and diarrhea have also been recorded. Unlike malaria symptoms, the symptoms of babesiosis do not exhibit periodicity.

Babesia microti - Most human infections are subclinical. Where clinical illness develops, the incubation period is 1 to 3 weeks, occasionally up to six weeks. The illness usually begins gradually, with anorexia and fatigue, plus fever (without periodicity), sweating, rigors and generalized myalgia. Physical examination may reveal only fever, but may also show mild splenomegaly and occasionally mild hepatomegaly.

Laboratory Diagnosis

Definitive diagnosis depends upon finding parasites on blood film examination which can be detected 2 to 4 weeks after a tick bite. Hamster inoculation and serology have also been used for diagnosis.

1. Microscopic Examination

Babesia bovis

Babesia bovis are pear shaped, oval or round and may exist in pyriform pairs. There may be 1 to 8 parasites per red cell. Ring forms can be confused with malaria parasites, especially *Plasmodium falciparum*. However, in contrast to *Plasmodium* species, *Babesia* do not form pigment, do not cause alterations in red cell morphology and finally do not exhibit the Maurer's clefts of *Plasmodium falciparum*, the Schüffner's dots of *Plasmodium vivax*, or the James's dots of *Plasmodium ovale*.

The "Maltese cross form" is unique to *Babesia* but in its absence it may be very difficult to distinguish young ring forms of *Plasmodium falciparum*, from *Babesia*. The absence of pigment cannot be relied upon, as young rings of *Plasmodium* do not exhibit pigment. *Babesia*, are smaller than malaria parasites, and in some of the larger rings there is white vacuole containing erythrocyte stroma, instead of the pink vacuole seen in malaria. *Babesia* parasites do not form schizonts.

Babesia microti

Ring, rod shaped, pyriform, amoeboid, and "Maltese cross" forms are seen. In heavy infections different stages may be noted in the same red cell. Intra-erythrocytic stages measure approximately 2 by 1.5µm. In very high parasitaemias, extracellular merozoites are found singly or as a syncytial structure. Peak parasitaemia varies between less than 1% to approximately 10%.

2. Serodiagnosis

The Indirect Fluorescent Antibody Test (IFAT) is available for both *B. bovis* and for *B. microti* and is the most useful serological test for early diagnosis.

3. Animal Inoculation

This is not routinely used for diagnosis but *B. microti* grows well in hamsters and can serve as a confirmatory test.

Toxoplasma gondii

Introduction

Toxoplasma gondii, the causative organism of toxoplasmosis, was first observed in 1927 in the gundi, a North African rodent. The first human case of toxoplasmosis was also reported that year. The organism is a coccidian protozoa belonging to the sub-phylum Apicomplexa and has a world wide distribution occurring in all warm-blooded animals.

Cats are the definitive hosts and they become infected by ingesting oocysts or cysts in tissues of paratenic hosts, such as mice, or transplacentally. Man becomes infected either by direct ingestion of oocysts from a cat or by eating raw or undercooked meat. Those who handle raw meat are particularly at risk. Infection can be transmitted transplacentally.

Life Cycle

The development of the enteroepithelial (sexual) cycle in a cats intestine is brought about by the ingestion of sporulated oocysts of a mouse with cysts. The pre-patent period up to the shedding of the oocysts varies with the stage of *T. gondii* ingested, for example only 3–10 days if the cat has ingested a mouse containing cysts, but about 19–20 days or longer after direct infection with oocysts or ingestion of a mouse containing only tachyzoites. Women most at risk of delivering an infected infant are those who acquire the infection just prior to gestation.

Humans can acquire infection by:

- Accidental ingestion of the oocyst shed in the cats feces
- Ingestion of the tachyzoite in infected milk or transplacentally
- Ingestion of the tissue cyst in undercooked or raw meat.
- Transplant of an infected organ in a seronegative recipient

Toxoplasmosis

(*Toxoplasma gondii*)

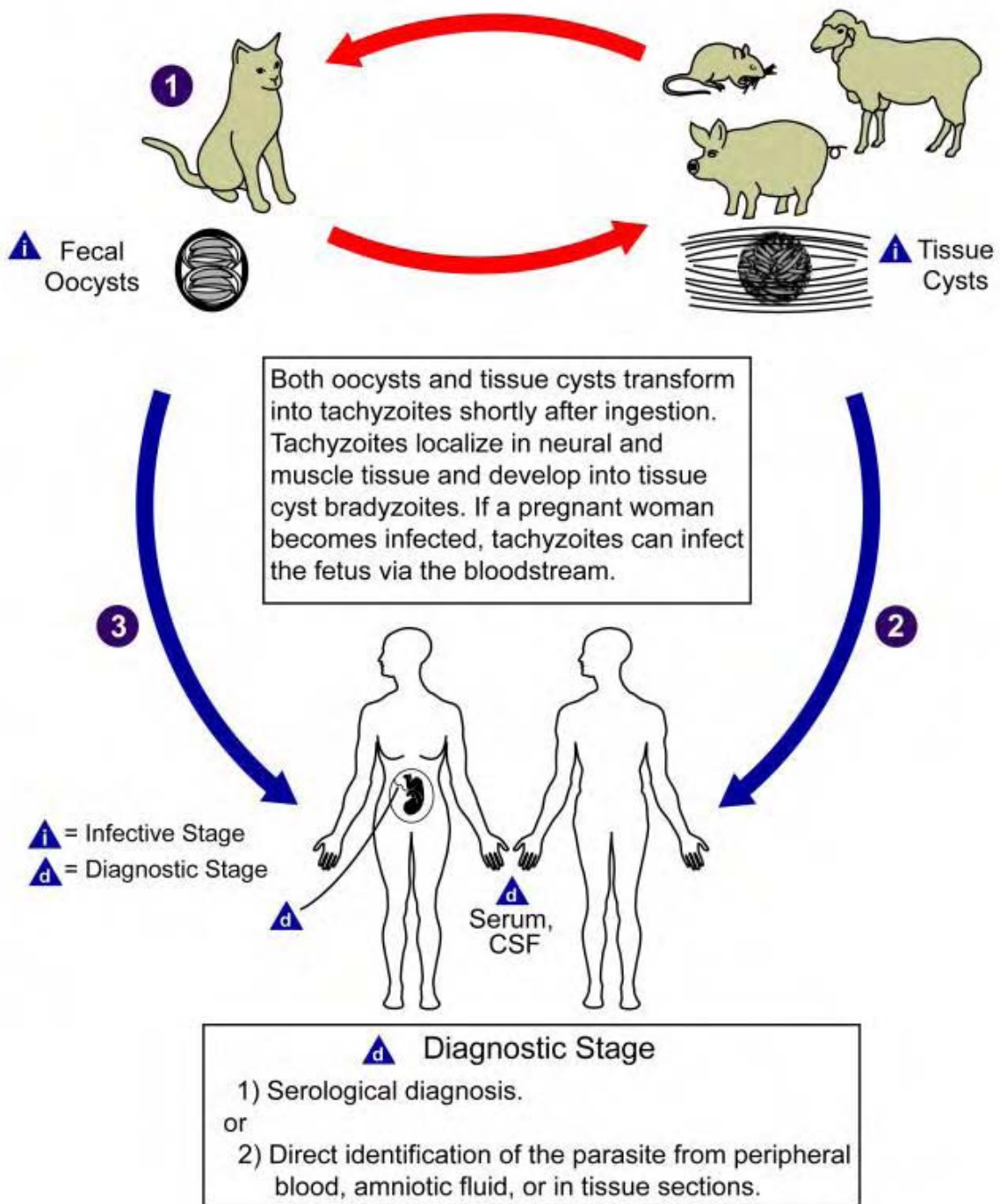


Illustration 11-2. Life cycle of *Toxoplasma gondii*, causes toxoplasmosis in man. (SOURCE: PHIL 3421 – CDC/Alexander J. da Silva, PhD/Melanie Moser)

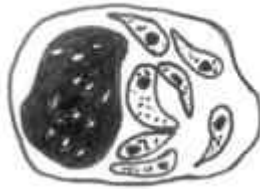

Illustration 11-3. Diagrammatic illustration of a *Toxoplasma gondii* trophozoite in a macrophage of a vertebrate. (SOURCE: Unknown)

Clinical Disease

Serological evidence has shown that approximately one third of the world's population has *Toxoplasma* antibodies. This suggests that the majority of infections are benign with most people exhibiting few or no symptoms, but fever and swelling may be seen. However, *Toxoplasma gondii* can cause severe illness in congenital infections, acquired infections and in immunocompromised patients. This may lead to ocular toxoplasmosis and ultimately to fatal CNS disorders such as encephalitis.

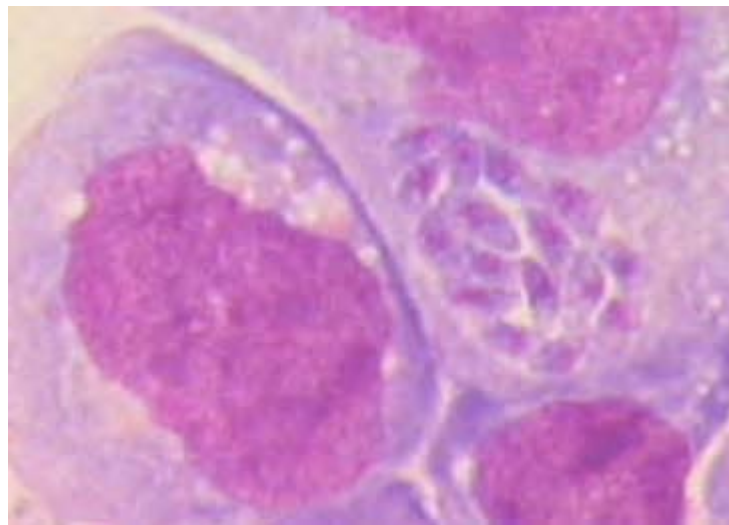


Image 11-2. *Toxoplasma gondii* tissue cyst containing 8–20 parasites (Giemsa stain) (SOURCE: CDC)

Congenital Toxoplasmosis

This occurs approximately in 1 per 1000 pregnancies. It can cause severe damage to and even death of the fetus. Proliferation of tachyzoites leads to intracellular calcification, choroidoretinitis, hydrocephaly, psychomotor disturbances and convulsions. A small proportion of babies who are asymptomatic at birth develop retinochoroiditis or mental

retardation as children or young adults. When a mother is first exposed to the parasite in later pregnancy the infant is likely to be less severely damaged or asymptomatic.

Acquired Infections

Infections with *T. gondii* are often mild with flu-like symptoms thus they often go unnoticed. However lymphadenopathy is the most easily recognized symptom and it can be accompanied by fever, headache and myalgia. Toxoplasmosis may also produce infectious mononucleosis like symptoms. Ocular toxoplasmosis is also a common manifest however it is not yet proven whether this is due to congenital or acquired infections. Other manifestations of *Toxoplasma* infections are meningoencephalitis, hepatitis, pneumonitis and myocarditis.

Immunocompromised Patients

Toxoplasmosis has been shown to occur as an opportunistic pathogen in immunocompromised patients and can cause severe complications. Toxoplasmosis in immunocompromised patients almost always arises from a reactivation of latent infections. Conditions which can predispose to toxoplasmosis are malignancies, organ transplants, leukemias and patients with acquired immune deficiency syndrome (AIDS). In immunocompromised patients, the central nervous system is primarily involved with diffuse encephalopathy, meningoencephalitis or cerebral mass lesions. *Toxoplasma* encephalitis has been reported as a life-threatening among patients with AIDS.

Laboratory Diagnosis

1. Serological Techniques

The detection of toxoplasma specific antibodies is most commonly used in clinical laboratories. Specific IgG antibodies typically persist for life whereas specific IgM antibodies begin to decline after several months. Most laboratories carry out preliminary tests for IgG antibodies and more definitive tests including IgM and IgA are carried out in reference laboratories. The Sabin-Feldman Dye Test is the benchmark for detecting the presence of specific antibodies. It measures the total amount of specific antibody in a serum which is capable of participating in antibody-mediated killing of tachyzoites by complement. This test involves the use of live tachyzoites which are derived from infected mice or rats. Because of the use of live organisms, this test is not recommended in the use of routine laboratories and is thus only employed in reference centers.

2. Isolation Techniques

Culture of parasites in animals is the best overall method but it can take up to six weeks before the result is available and is thus a disadvantage. Tissue culture is more rapid taking three or four days to obtain a result, but is not as sensitive.

3. Antigen Detection

The direct detection of very small amounts of specific nucleic acid has been made possible by the introduction in 1985 of the polymerase chain reaction (PCR). This technique results in the amplification of a specific fragment of DNA from within the parasite genome which is detected by ethidium bromide staining, following gel electrophoresis. PCR is so sensitive it should detect *Toxoplasma* DNA in one cyst. However this may indicate a latent infection rather than an active infection. However its sensitivity may create problems since it will detect very small amounts of DNA from latent as well as active infections and it does not differentiate between cyst and tachyzoite DNA. Thus samples like blood, CSF, urine and amniotic fluid should be used as they do not contain the latent stages. PCR shows great promise but as yet is still labor intensive and expensive for routine use in the laboratory.

Trypanosoma species

Introduction

Trypanosomes are hemoflagellates and three species of the genus *Trypanosoma* are responsible for disease in humans such as sleeping sickness.

Trypanosomes occur in the blood of the majority of vertebrate animals. The life cycle involves intermediate host, which usually is an insect. Many species of trypanosomes can live in harmony with their hosts producing no pathogenic effect, but the best known species are those that are pathogenic to their definitive hosts. The disease in caused by the pathogenic types is called trypanosomiasis.

Salivarian Trypanosomes

Trypanosoma brucei rhodesiense and *Trypanosoma brucei gambiense* - The metacyclic trypanosomes are found in the proboscis of the insect vector - infection is therefore inoculative. The above are the causative agents of African trypanosomiasis. It is a zoonotic species in that it multiplies in the blood of a range of many mammals including man.

Trypanosoma brucei rhodesiense causes acute sleeping sickness in East Africa, while *T. b. gambiense* causes chronic sleeping sickness in West Africa.

These are known as salivarian trypanosomes as they complete their development in the salivary system (anterior portion of the vector). Transmission takes place by inoculation of the metacyclic stage.

Stercorarian Trypanosomes

Trypanosoma cruzi - The metacyclic trypanosomes occupy a posterior position in the gut of the insect vector and are passed out in the feces - infection is therefore contaminative. This is the causative agent of American Trypanosomiasis.

These trypanosomes are known as stercocarian as they complete their development in the posterior region of the vector, so that the infective forms appear in the insect's feces. Hosts are infected by the contaminative route.

African Trypanosomiasis

Life Cycle

Transmission from one vertebrate to another is carried out by blood-sucking invertebrates, usually an insect. The vector for African Trypanosomiasis is the Tsetse fly, *Glossina* spp. which cause the diseases *Trypanosoma brucei gambiense* and *Trypanosoma brucei rhodesiense*.

Metacyclic (infective) trypomastigotes are inoculated through the skin when a tsetse fly takes a blood meal. The parasites develop into long slender trypomastigotes which multiply at the site of inoculation where ulceration occurs. The trypanosomes continue to develop and then may invade the lymphatic tissues, the heart, various organs and in later stages, the central nervous system. Trypomastigotes are taken up by the tsetse fly (male and female) during a blood meal. The parasites develop in the midgut of the fly where they multiply. 2-3 weeks later the trypomastigotes move to the salivary glands transforming from epimastigotes into metacyclic (infective) trypomastigotes. The tsetse fly remains infective for life i.e. about three months.

Sleeping Sickness, African (African trypanosomiasis)

(*Trypanosoma brucei gambiense*)

(*Trypanosoma brucei rhodesiense*)

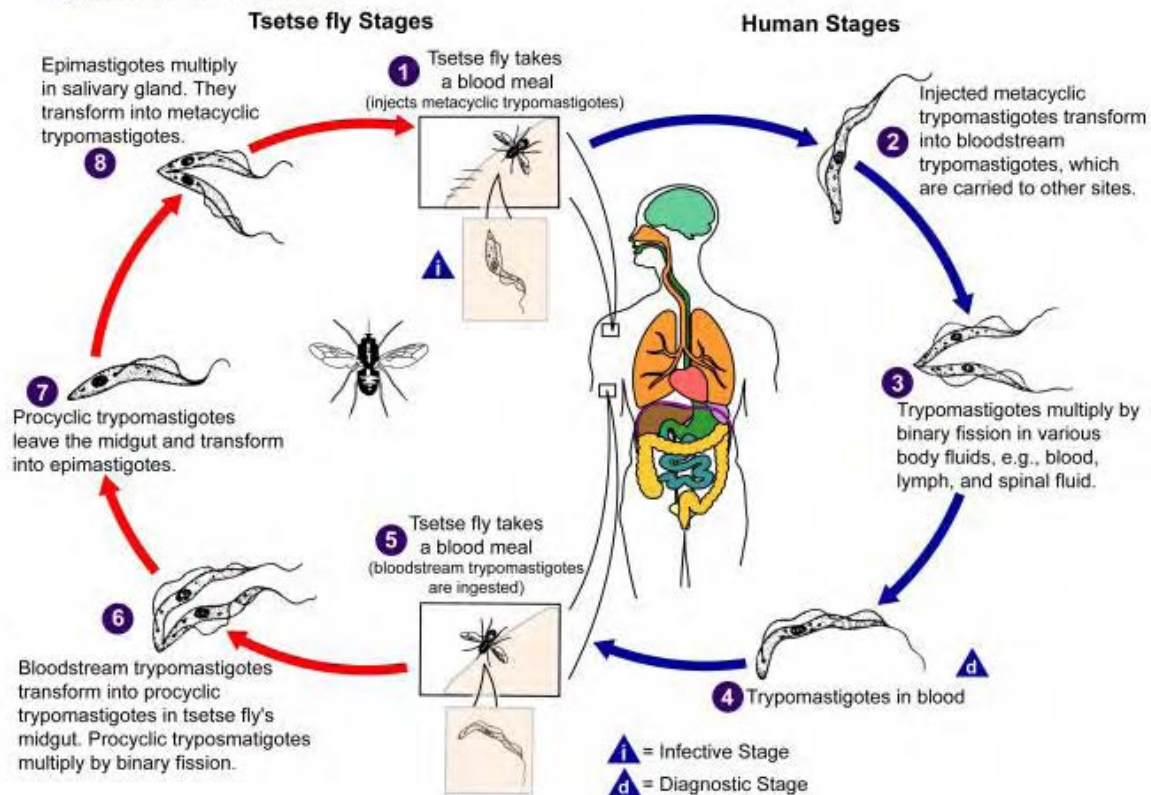


Illustration 11-4. Generalized life cycle of the *Trypanosoma* spp. which causes African Trypanosomiasis. (SOURCE: PHIL 3418 – CDC/Alexander J. da Silva, PhD/Melanie Moser)

The mode of transmission mentioned above, metacyclic transmission, requires to be separated from mechanical transmission, a process in which trypanosomes survive, for a short time, on and about mouth parts of an insect and are inoculated into a new host when the vector bites again, without undergoing any developmental cycle.

Metacyclic transmission requires a lapse of time to allow the trypanosomes to reach an infective stage by a particular developmental sequence in the vector, usually a period of several days.

Morphology

The parasite is an elongated cell with single nucleus which usually lies near the centre of the cell. Each cell bears a single flagellum which appears to arise from a small granule - the kinetoplast. The kinetoplast is a specialized part of the mitochondria and contains DNA. The length and position of the trypanosome's flagellum is variable. In trypanosomes from the blood of a host the flagellum originates near the posterior end of the cell and passes forward over the cell surface, its sheath is expanded and forms a wavy flange called an undulating membrane.

Development is characterized by the occurrence of three types of blood forms (polymorphic), these are:

- 1) **Slender forms:** long and thin, about 29 μ m long, free flagellum.
- 2) **Stumpy forms:** thick and short, average length 18 μ m, typically no free flagellum, but a short one may be present.
- 3) **Intermediate forms:** about 23 μ m long with a moderately thick body and a free flagellum of medium length.



Illustration 11-5. Diagrammatic illustration of a typical trypanosome. (SOURCE: Unknown)

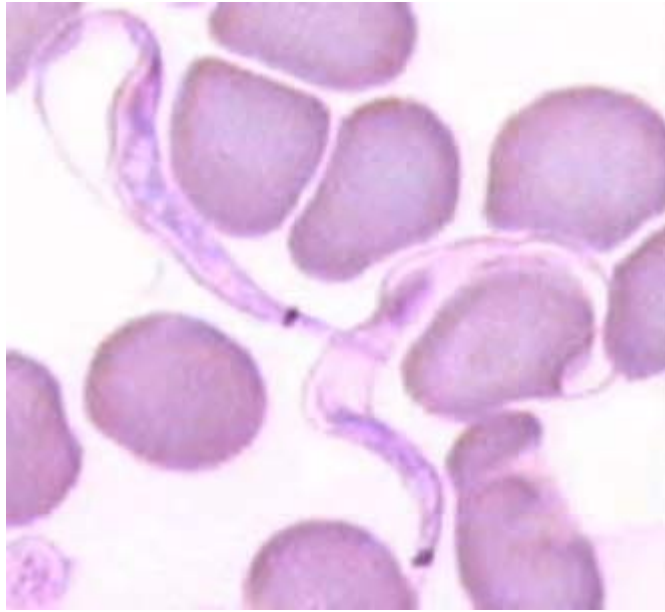


Image 11-3. *Trypanosoma brucei gambiense* and *T. b. rhodesiense*: two forms of trypomastigote can be seen in peripheral blood: one is long slender, 30 μm in length, and is capable of multiplying in the host, the other is stumpy, not dividing, 18 μm in length. (SOURCE: CDC)

Clinical Disease

The early stages of African trypanosomiasis may be asymptomatic and there is a low grade parasitaemia. This period may last for several weeks to several months. The disease may terminate untreated at this stage or go on to invade the lymph glands. Invasion of the lymph glands is usually accompanied by a high irregular fever with shivering, sweating and an increased pulse rate. The lymph glands near the bite often become swollen, in *T. b. gambiense* the glands at the back of the neck and *T. b. rhodesiense* usually the glands under the jaw are affected (Winterbottom's sign). As the disease progresses, edema of the eyelids, face and sleeplessness are features along with increasing lethargy and listlessness.

Trypanosomes may invade the central nervous system giving symptoms of meningoencephalitis, confusion, apathy, excessive sleeping and incontinence. At this stage, the cerebrospinal fluid (CSF) usually contains mononuclear cells and a few trypanosomes may be detected. If untreated, character changes, mental deterioration and coma develops, finally resulting in death. Such signs are more commonly seen with *gambiense* than in *rhodesiense* in which patients often die before these symptoms develop fully.

Laboratory Diagnosis of African trypanosomiasis

Laboratory diagnosis of African Trypanosomiasis is by:

- Examination of blood for the parasites
- Examination of aspirates from enlarged lymph glands for the parasites
- Examination of the CSF for the parasite

- Detection of trypanosomal antibodies in the serum

1. Examination of Blood

a) Thick and Thin Blood Films

Thick and thin blood films are made and stained with Fields stain and examined as for malaria parasites

b) Triple Centrifugation Technique

This method is carried out as follows:

- i. 5 to 10ml of citrated blood is centrifuged at 2000rpm for 5 minutes to pack the red blood cells.
- ii. The plasma and white cell layer are removed by a Pasteur pipette and transferred to a clean centrifuge tube.
- iii. This is centrifuged for a short time in order to deposit any red blood cells carried over.
- iv. The supernatant fluid is removed by pipette to a clean tube.
- v. This is centrifuged at 5000rpm for 10 minutes.
- vi. The supernatant fluid is removed with a pipette and discarded.
- vii. The deposit is examined microscopically for trypanosomes.

c) Miniature anion-exchange centrifugation technique.

Heparinized blood is passed through an anion exchange column. As the blood travels down the column the red cells are adsorbed while the less strongly charged trypanosomes are washed through with saline. The eluate is centrifuged and examined microscopically for motile trypanosomes.

d) Buffy Coat Examination

Trypanosomes are centrifuged in a microhaematocrit tube for five minutes. Parasites can be seen microscopically at the junction of the packed red cells and plasma.

2. Examination of Lymph Gland Aspirates

The aspirate can be examined microscopically by making a wet preparation, or if there is not much material, it can be allowed to dry on a slide and then stained with either rapid Field's stain or with Giemsa and examined microscopically.

3. Examination of CSF

In the late stages of African trypanosomiasis, trypanosomes may be found in the CSF together with IgM - containing morula (Mott) cells, lymphocytes and other mononuclear cells. Once the CSF has been collected it **must be examined as soon as possible**. The parasites are unable

to survive for more than 15-20 minutes in CSF once it has been removed. The parasites become inactive, are rapidly lysed and will not therefore be detected. The CSF should be examined wet and spun down in a sterile tube and a film made from the deposit. The film is then stained with rapid Field's or Giemsa and examined microscopically.

NB. It is impossible to distinguish between *T. b. gambiense* from *T. b. rhodesiense* on a stained film as the two subspecies which infect man are identical.

American Trypanosomiasis

Trypanosoma cruzi occurs throughout South and Central America, especially in Brazil, Argentina and Mexico causing the disease known as Chagas' disease. It is estimated that over 24 million people are infected with this species. It is a zoonotic parasite with over 150 species of wild animals known to harbor the parasites, for example opossums, dogs, rates, pigs and cats.

It is transmitted to man by brightly colored bugs belonging to the Reduviidae family, subfamily Triatominae. All stages of these bugs are known to become infected.

The bugs live in the crack of the walls and vegetal roofs of the poorly maintained houses, coming out at night to feed on the exposed parts of the host's body.



Image 11-4. Insect vector of *Trypanosoma cruzi*, belongs to colorful insect Triatominae, also known as the kissing bug. (SOURCE: PHIL 2538 - CDC/World Health Organization)

Life Cycle

Metacyclic trypomastigotes are deposited in feces on the skin as the **triatomine bug** (reduviid bug) feeds. The bug usually bites round the edges of the mouth and eyes. The trypomastigotes are either rubbed into the skin by scratching the irritated area or penetrate the conjunctiva or membranes of the nose and mouth. Trypomastigotes become amastigotes in localized reticuloendothelial cells and multiply. The amastigotes develop into trypomastigotes

which are released into the blood when the cell ruptures. No multiplication of the parasite takes place in the blood in its trypomastigote stage. The trypomastigotes reach tissue cells especially heart muscle, nerves, skeletal muscle and smooth muscle of the gastrointestinal system by way of the blood and lymphatic system. The trypomastigotes become amastigotes and multiply forming pseudocysts. Within the pseudocyst some amastigotes become elongated and develop first into epimastigotes and then trypomastigotes. When the cell ruptures the trypomastigotes are released into the blood and continue to circulate while others invade further tissue cells. The life cycle completes when a triatomine bug vector ingests circulating trypomastigotes. In the vector the trypomastigotes transform and develop into epimastigotes, multiply by binary fission in the gut of the bug. After about 10-15 days, metacyclic trypomastigotes are formed and can be found in the hindgut of the bug.

Trypanosomiasis, American (Chagas disease)

(*Trypanosoma cruzi*)

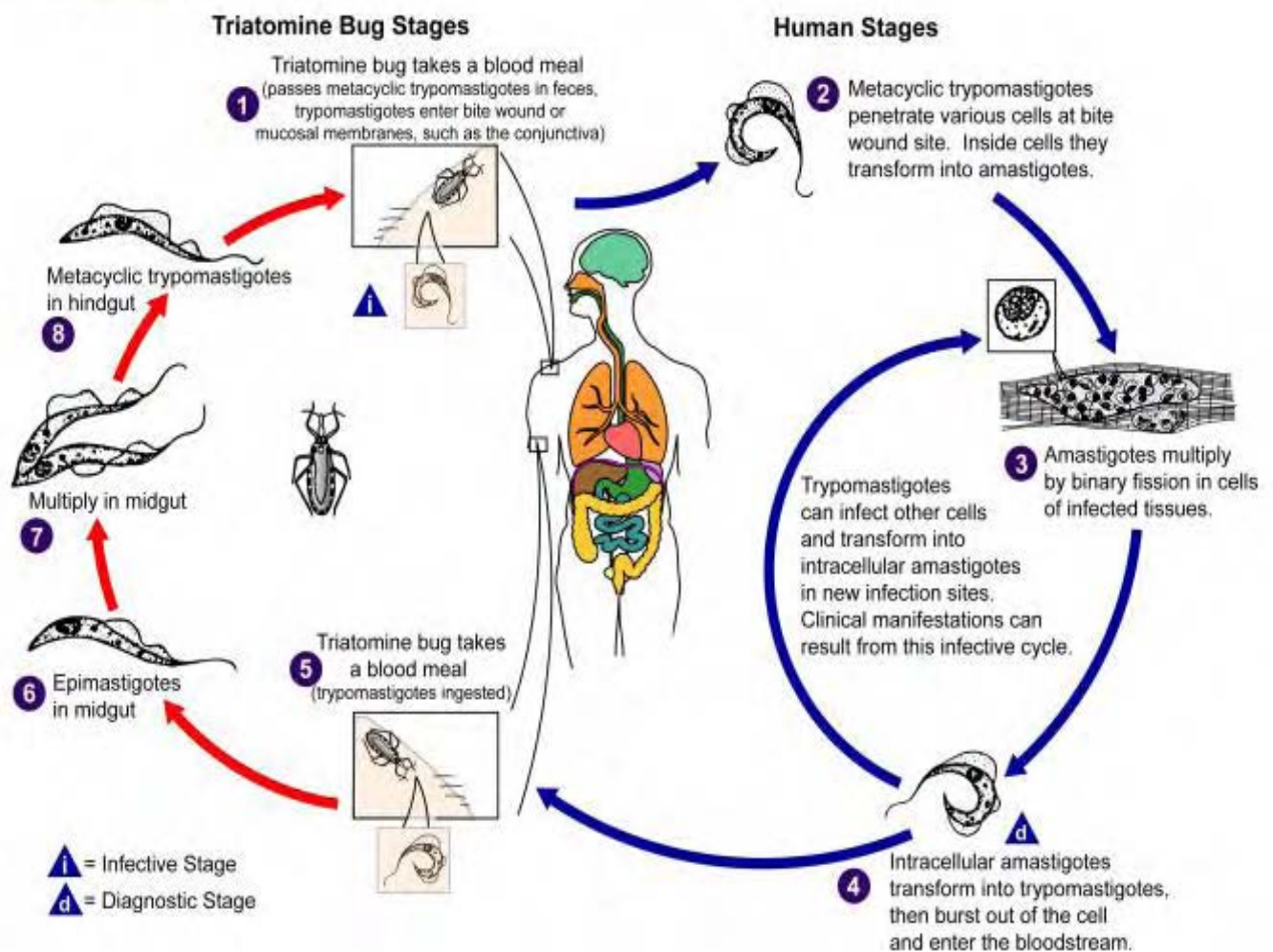


Illustration 11-6. Generalized life cycle of the American trypanosomes, *Trypanosoma cruzi*, which is known to cause Chagas' disease. (SOURCE: PHIL 3384 – CDC/Alexander J. da Silva, PhD/Melanie Moser)

Morphology

Trypanosoma cruzi has a single form (monomorphic), about 20µm in length, and characteristically curved. The kinetoplast is large, considerably larger than the *Trypanosoma brucei* species already discussed. They sometimes appear as a bulge at the posterior end. The flagellum is medium in length.

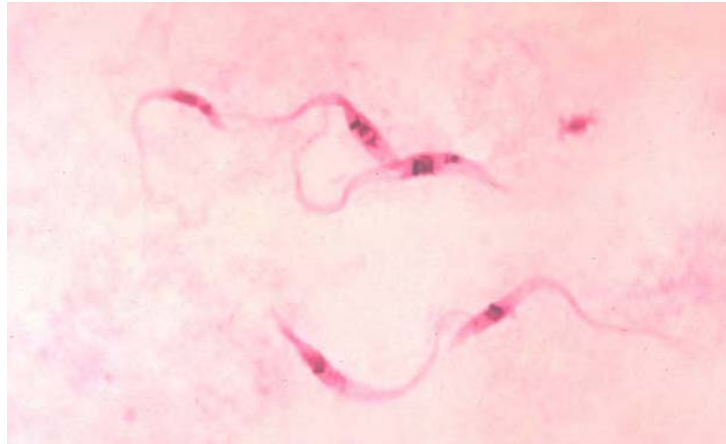


Image 11-5. *Trypanosoma cruzi* hemoflagellate in blood sample (SOURCE: PHIL 545 - CDC)

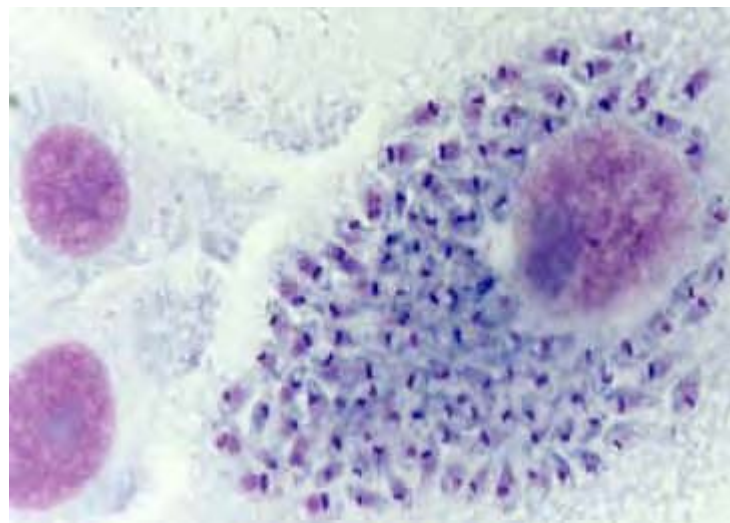


Image 11-6. Multiplication of *Trypanosoma cruzi* in man only occurs in the amastigote phase, which grows in a variety of tissue cells especially muscle. In vitro infected fibroblast showing a large number of intracellular amastigotes. (Giemsa stain) (SOURCE: Unknown)

Clinical Disease

Many people infected with *T. cruzi* remain asymptomatic and free from Chagas' disease or experience only an acute infection without progressing to the chronic stage. The most severe form of the disease is most commonly seen in children younger than five years of age.

Multiplication of *T. cruzi* at the site of infection can produce an inflamed swelling (chagoma) which persists for weeks. Trypomastigotes or amastigotes may be seen in the aspirate of the chagoma. Regional lymph nodes may become infected which frequently involve one side of the face. Unilateral edema of the upper and lower eyelid may occur along with conjunctivitis. This is known as Romanas' sign.

In the acute stage of infection trypomastigotes can be found in the blood. Symptoms may pass unnoticed, but there may be fever, malaise, increased pulse rate, and enlargement of lymph glands, liver, and possibly spleen. Muscle aches and pains are characteristic at this stage and parasites may be seen in blood films. The acute form is most often seen in young children and occasionally can cause serious damage to the heart and other complications leading to death caused by central nervous system involvement.

Chronic manifestations include signs of cardiac muscle damage with a weak and irregular heartbeat, edema, heart enlargement leading to heart failure. Dilation of the digestive tract resulting in megaesophagus and megacolon may also occur. About 10% of persons infected with *T. cruzi* develop chronic Chagas cardiopathy.

Laboratory Diagnosis of American Trypanosomiasis

Laboratory diagnosis of South American trypanosomiasis is by:

- Examination of blood.
- Xenodiagnosis
- Blood culture
- Serology

1. Examination of Blood

a) Thick and thin blood films are made and stained with Fields stain and examined as for malaria parasites. Wet preparations of blood can also be examined for motile trypanosomes.

b) Buffy coat examination - Trypanosomes are centrifuged in a microhematocrit tube for 5 minutes. Parasites can be seen microscopically at the junction of the packed red cells and plasma. This technique is rapid and sensitive.

Trypanosoma cruzi can often be seen in C, U or S shapes in stained films.

2. Xenodiagnosis

Xenodiagnosis is useful in chronic and sub acute (low parasitaemia) disease. Sterile bugs are fed on patients by attaching a black bag containing the bugs to the arm of the patient and allowing them to feed for 30 minutes. Twenty five to thirty days later the bugs are dissected and the contents of the hindgut and rectum are examined microscopically for the presence of trypanosomes.

3. Blood Culture

Blood culture is as sensitive as xenodiagnosis but it requires sterile conditions.

4. Serology

Serology tests include:

- a. **IFAT** indirect fluorescence antibody test
- b. **CFT** complement fixation test
- c. **IHAT** indirect hemagglutination test
- d. **ELISA** enzyme linked immunoabsorbent assay

Other lab findings include:

Raised ESR, marked lymphocytosis with atypical mononuclear lymphocytes

NB. In certain areas of S. America where *Trypanosoma rangeli* (a nonpathogenic species transmitted by *Rhodnius* spp. bugs) is found with *T. cruzi*. All positive preparations should be checked to confirm *T. cruzi*.

Leishmania species

Introduction

Leishmaniasis is caused by parasites of the genus *Leishmania* and is endemic in many parts of Africa, Asia and South America. It is transmitted by *Phlebotomus* species, sandfly.

Leishmania species are mainly parasites of man and other animals, especially dogs and rodents. They cause diseases collectively known as Leishmaniasis; causing three types of disease (i.e. Visceral Leishmaniasis, Cutaneous Leishmaniasis, and Mucocutaneous Leishmaniasis. These are all debilitating and disfiguring diseases which occur throughout the Old and New World. The parasites are unusual in that they live entirely within the cells of the reticuloendothelial cells, they have become perfectly adapted as the proteolytic enzymes which attack other foreign bodies in the blood stream but do not destroy them.

Visceral Leishmaniasis

Human visceral leishmaniasis (VL), sometimes known as Kala-azar, is caused by *Leishmania donovani* complex; *L. donovani* and *L. donovani infantum* in the Old World and *L. donovani chagasi* in the New World. The clinical features -azar caused by these species are similar, but they have different epidemiological features. The parent species *L. donovani* occurs in Asia (Northeastern China, India and Iran) and Africa (primarily Sudan, Kenya and Ethiopia) and can affect people of all ages. The parasite (*L. d. infantum*) which causes VL in countries bordering the Mediterranean, (Southern Europe as well as North Africa) affects young children as well as infants. It is now being seen in the immunocompromised. In the New World also, VL is mainly a disease of young children, with the causative organism *L. d. chagasi* being closely related to, but slightly different from, *L. donovani*. The main geographical foci of VL in Latin America are in northern and northeastern Brazil. Small foci are found in northern Argentina, Columbia and Venezuela. Sporadic cases are found in Central American countries, including Mexico.

Cutaneous Leishmaniasis

Cutaneous leishmaniasis is caused by *L. tropica*, *L. major* and *L. aethiopia* in the Old World and *L. mexicana* complex in the New World. *Leishmania tropica* is widely distributed around the Mediterranean basin, Afghanistan, Kenya, Kenya, Armenia, Azerbaijan, Turkmenistan and Uzbekistan. *Leishmania aethiopia* is seen in the highlands of Ethiopia and *L. major* occurs in the Middle East, West Africa, North Africa and Kenya. *Leishmania mexicana* complex is found in Central America and the Amazon Basin.

Mucocutaneous Leishmaniasis

Is caused by the *L. braziliensis* complex and is found in Brazil, Eastern Peru, Bolivia, Paraguay, Ecuador, Columbia and Venezuela.

Life cycle

All forms of infection starts when a female sandfly (*Phlebotomus* species) takes a blood meal from an infected host. Small amounts of blood, lymph and macrophages infected with *Leishmania* **amastigotes** are ingested. Once ingested the **amastigotes** transform to **promastigotes** in the sandfly, the non-infective **promastigotes** divide and develop into infective **metacyclic promastigotes**. These are formed in the midgut of the sandfly and migrate to the proboscis. When the sandfly bites, the extracellular inoculated promastigotes at the site of the bite are phagocytosed by macrophages. After phagocytosis, transformation to dividing **amastigotes** occurs within 24 hours. Reproduction at all stages of the lifecycle is believed to occur by binary fission. No sexual stage has been identified.

Leishmaniasis

(*Leishmania* spp.)

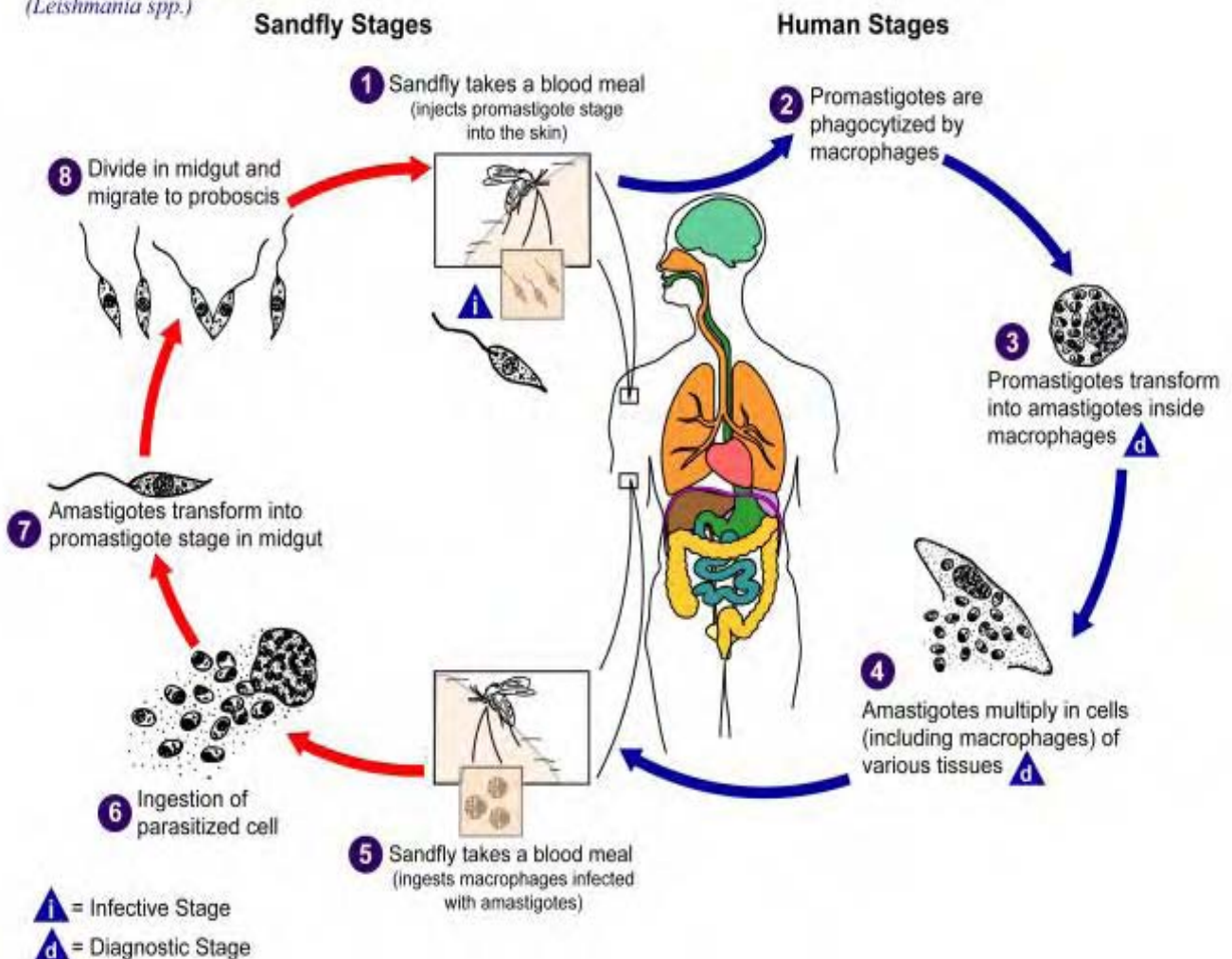


Illustration 11-7. Generalized life cycle of *Leishmania* sp., which by using a sandfly as a vector can cause Leishmaniasis in man. (SOURCE: PHIL 3400 – CDC/Alexander J. da Silva, PhD/Melanie Moser)

Morphology

Leishmania exist as flagellated extracellular **promastigotes** in the Sandfly vector and as a flagellar obligate intracellular **amastigotes** within mononuclear phagocytes of their vertebrate hosts. The various species are not distinguishable morphologically from one another. When stained with Romanowsky stains such as Giemsa, **amastigotes** appear as round or oval bodies ranging from 2 - 3 μ m in diameter with a well defined nucleus and kinetoplast, a rod shaped specialized mitochondrial structure that contains extranuclear DNA. The flagellated **promastigote** form is spindle shaped, measuring 10 - 20 μ m in length, not including the length of the flagellum. As in the amastigote form a nucleus and kinetoplast are clearly visible.

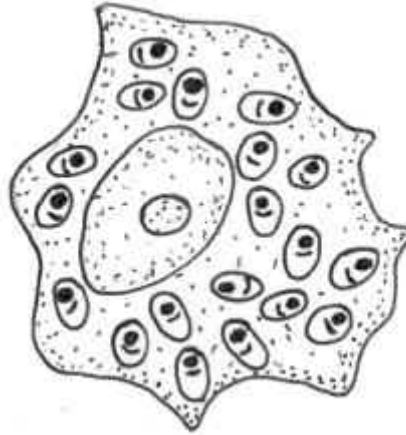


Illustration 11-8. Amastigote of *Leishmania* sp. in a macrophage of a vertebrate host. (SOURCE: Unknown)

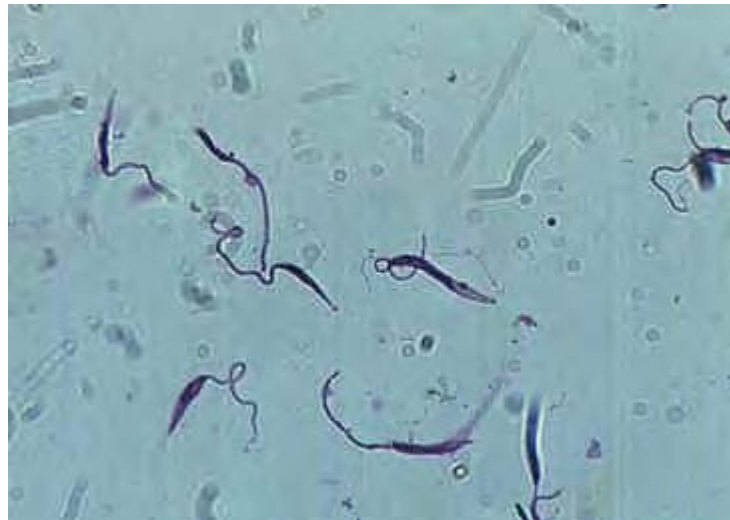

Image 11-7. *Leishmania* promastigote. This stage of the parasite are seen in the vector, sandfly. (SOURCE: Unknown)

Clinical Disease - Visceral Leishmaniasis

The incubation period of VL may vary between two weeks and 18 months. The onset of VL is usually insidious with fever, sweating, weakness and weight loss. The most prominent findings are fever, hepatosplenomegaly and anemia. The sites mainly affected are the liver, spleen and bone marrow. Enlargement of the liver is due to hyperplasia of Kupffer cells which are packed with amastigotes. The bone marrow is infiltrated with parasitized macrophages. Some organs, notably the kidneys, may show pathological changes secondary to deposition of immune complexes. In advanced cases, ascites and edema can develop. Deaths are usually due to secondary bacterial infections such as pneumonia, tuberculosis or dysentery.

Laboratory Diagnosis - Visceral Leishmaniasis

1. Microscopy

Parasites may be found in a splenic aspirate, liver biopsy or bone marrow biopsy. These techniques, especially splenic aspirate and liver biopsy, can be hazardous and require previous expertise in the procedure.

- a) Air dry smears
- b) Fix in methanol for one minute
- c) Stain with Giemsa 1 in 10 in buffered distilled water pH 6.8 for 30 minutes (or use the rapid Field's stain)
- d) Wash the slide in buffered water and drain dry

Amastigotes of *Leishmania* should be seen in positive smears. They are approximately 2-4µm in size, oval and are frequently seen within the cytoplasm of the macrophage. The amastigotes possess a nucleus and a rod - shaped kinetoplast within the cytoplasm. In many samples a very small number of parasites are present. Extensive searching of the film is necessary.

2. Culture

The aspirates can be cultured in Novy-Nicolle-MacNeal (NNN) or Schneider's *Drosophila* medium. In culture the **amastigote** stage converts to the **promastigote** stage. However, this is not a rapid technique, as the parasites may take anything from 10-21 days to grow.

3. Serodiagnosis

VL produces large amounts of specific IgG which can be used for diagnosis. Currently the most used sero diagnostic tests are Indirect-immuno Fluorescent Antibody Test (IFAT), Enzyme Linked Immunosorbent Assay (ELISA) and Direct Agglutination Test (DAT).

Clinical Disease – Cutaneous Leishmaniasis

Following a bite from an infected sandfly, a small red papule appears at the site of the bite about 2–8 weeks later. The papule increases in size centrifugally. The patient then mounts either a hypersensitive response or an anergic response. In a hypersensitive response, the papule eventually ulcerates, becomes depressed and then eventually heals through scarring. The patient is now immune from subsequent bites. In an anergic response, the nodule grows and spreads over large areas of skin. This resembles leprosy.

Laboratory Diagnosis - Cutaneous Leishmaniasis

1. Slit skin smear.

The margin of the lesion contains amastigotes whereas the centre contains debris and dead skin material. This margin of the lesion is aseptically punctured with a hypodermic needle and syringe containing a small amount of saline. The aspirate which is drawn up into the needle is examined microscopically and/or cultured using the method described in Visceral Leishmaniasis.

2. Polymerase chain reaction

Gene amplification techniques are powerful and sensitive methods and are useful in diagnosis of Cutaneous Leishmaniasis particularly when organisms cannot be detected microscopically. It is also very useful for the speciation of *Leishmania* parasites thus the correct treatment can be administered.

Clinical Disease – Mucocutaneous Leishmaniasis

Mucocutaneous Leishmaniasis or espundia initially develops like cutaneous leishmaniasis but develops into lesions in the mucocutaneous junction of the pharynx resulting in the break down of the palate of the mouth and nose or more rarely the genitalia or anus. This occurs from a few weeks to several years after the cutaneous lesion has healed. These lesions result in disfiguring deformities of the nose and mouth.

Laboratory Diagnosis - Mucocutaneous Leishmaniasis

1. Microscopy

Finding the organisms in a histological section of the lesion provides definitive diagnosis of Mucocutaneous Leishmaniasis. However, the organisms are very rare in this form of the disease and culture can be a more sensitive method (see visceral leishmaniasis).

2. Polymerase Chain Reaction

The PCR method has the advantage of not only low numbers of parasites in aspirates but also histological sections. This makes this a very sensitive method in diagnosing Mucocutaneous Leishmaniasis when parasites are difficult to detect.

Chapter 12.

Arthropod Vectors

Soft Ticks

Class: Arachnida

Subclass: Acari

Order: Ixodida

Family: Argasidae

Genus: *Ornithodoros*



Image 12-1. *Ornithodoros* – Soft Tick (SOURCE: CDC)



Image 12-2. *Ornithodoros moubata*, the most important soft tick disease vector found throughout the world (SOURCE: CDC)

General Characteristics

Soft Ticks are characterized by a tough leathery integument and a flattened oval shape when examined dorsally. The Argasidae lack the dorsal shield present in the Hard Ticks (Ixodidae), and need to be examined ventrally to observe their capitulum or mouthparts. Soft ticks generally have a world-wide distribution, with the most important disease vector *Ornithodoros* populating Europe, Africa, Asia and the Americas.

Life Cycles

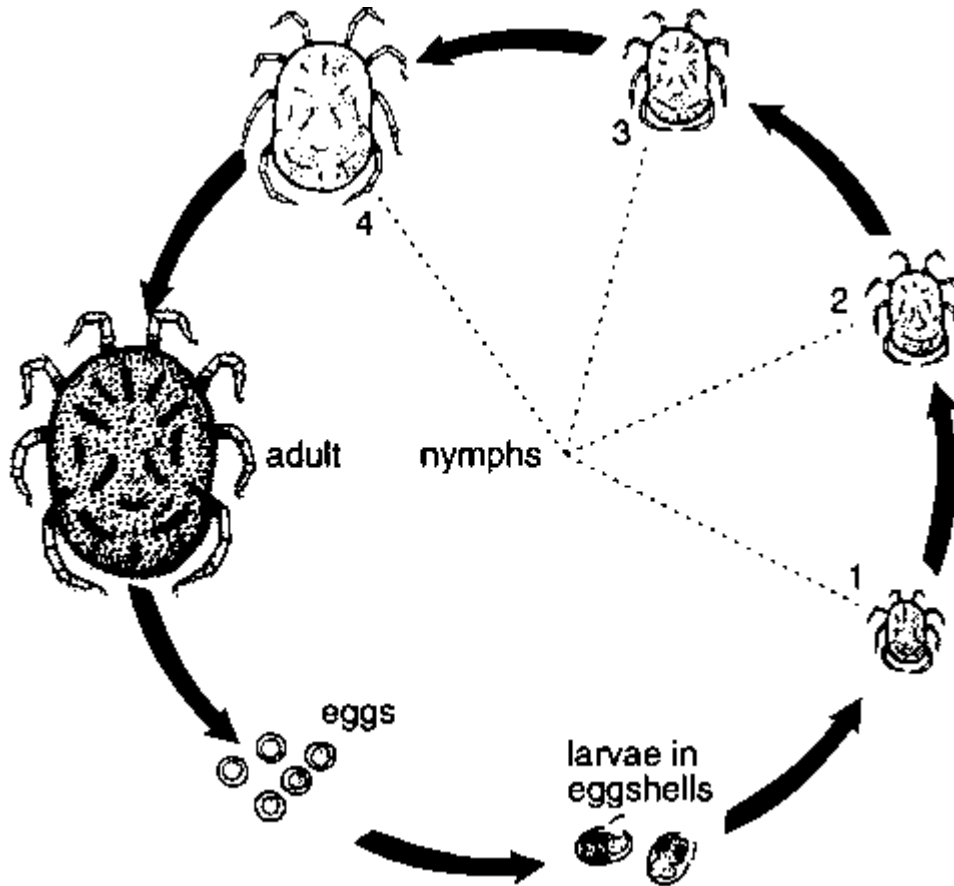


Illustration 12-1. Life Cycle of Soft Ticks. (SOURCE: Unknown)

Soft ticks have a hemimetabolous life cycle, with eggs hatching six legged larvae, which molt to eight legged nymphs. There are five to seven larval instars depending on the species, with each stage requiring a blood meal to proceed. Larvae of *Ornithodoros moubata* do not require a blood meal to molt to the nymph stage. Adult females lay small egg batches following each blood meal. The duration of the life cycle depends on the temperature, host availability, and inherently the particular species in question.

The adults are flat and oval in outline and have tough, leathery, wrinkled bodies. The mouthparts are situated underneath the body and are not visible from above. The eggs are

laid in the places where the adults rest, such as cracks and crevices in the walls and floors of houses and in furniture. The larva, the five nymphal stages and the adults all actively search for hosts from which to take blood-meals. After feeding, which lasts about 30 minutes, they drop to the ground. Most species can survive for more than a year between blood-meals, and some for more than 10 years.

The soft ticks live apart from their hosts and are most common in the nests and resting places of the animals on which they feed. Some species, such as the chicken tick and the pigeon tick (*Argas* species) may feed on humans when the preferred hosts are not available.

Species that commonly feed on humans are found around villages and inside houses. Their habits are comparable to those of bedbugs: ticks often emerge from hiding places at night to suck the blood of humans and animals. Some species are common on travel routes, in rest houses and camping sites, and in caves and crevices.

Disease

Soft Ticks are vectors for serious disease including tick borne relapsing fever (*Borrelia duttoni*), rickettsial disease (*Coxiella burneti*), and some arboviruses. The most important disease spread by soft ticks is tick borne relapsing fever which occurs world-wide and is spread by spirochete infected *Ornithodoros*. Q-fever and arboviruses can be spread following a blood meal, but are both primarily introduced into the population by the Hard Ticks.

Tick-borne Relapsing Fever

This disease is caused by a microorganism of the genus *Borrelia*. It is transmitted by biting soft ticks of the genus *Ornithodoros* in many countries in the tropics and subtropics and also in Europe and North America. The ticks usually feed quickly at night in or near houses, and then leave the host.

The disease causes bouts of fever alternating with periods without fever. Death occurs in about 2-10% of persons who are untreated.

Treatment

Treatment is possible with tetracycline or its derivatives.

Prevention

Prevention requires measures to control soft ticks and to avoid their bites.

Hard Ticks

Class: Arachnida

Subclass: Acari

Order: Ixodida

Family: Ixodidae

Species: *Ixodes*, *Amblyomma*, *Rhipicephalus*, *Dermacentor*

General Characteristics

Hard ticks appear flattened when examined dorsally and can be primarily characterized by the presence of a dorsal plate or scutum, and a capitulum that projects beyond the body outline. The scutum regularly covers the entire dorsal area, although females may have a reduced plate present directly behind the capitulum. *Ixodes* spp. inhabit in Canada, Europe, Asiatic Russia, China, Japan, and Australia.



Image 12-3. *Ixodes scapularis* - male - showing the scutum covering the whole length of the body (left); *Ixodes scapularis* - female, showing the scutum covering half the length of the body (right)



Image 12-4. *Amblyomma variegatum* - male - showing the scutum covering the whole length of the body (left); *Amblyomma variegatum* - female - showing the scutum covering half the length of the body (right)



Image 12-5. *Rhipicephalus sanguineus* - female - showing the scutum covering half the length of the body (left); *Rhipicephalus sanguineus* - male - showing the scutum covering the whole length of the body (right). (AFPMB – used with permission)



Image 12-6. *Dermacentor variabilis* - male - showing the scutum covering the whole length of the body (left); *Dermacentor variabilis* - female - showing the scutum covering half the length of the body (right) (Image courtesy of: Iowa State University)

Life Cycle

Hard Ticks have a hemimetabolous life cycle similar to that of the Soft Ticks. Hard tick larvae search for suitable hosts, feed for several days, and drop off engorged to the ground below. Molting to the nymph stage follows several days later and the tick again searches for a suitable blood source. There is only one nymphal stage in *Ixodes*, and following several weeks of stasis the nymph will molt into an adult. Females lay one large mass of eggs, which forms a cellular mass on the scutum of the ovipositing female.

Disease

Hard ticks transmit a variety of diseases including Lyme Disease, Tick Paralysis, Rickettsia, arboviruses that are responsible for encephalitis and hemorrhagic fevers, tularemia and *Babesia microti* infection. Tick paralysis is caused by the toxins present in the saliva of the tick, and is introduced during feeding.

Lyme disease is a serious ailment caused by the spirochete *Borrelia burgdorferi*. Lyme disease results in acute erythema, systematic lesions and eventually chronic involvement of multiple organs.

Rickettsiae diseases spread by *Ixodes* include Q-fever (*Coxiella burnetii*) and arboviruses that cause serious encephalitis.

Babesia microti infection primarily involves animals, with Man as an accidental host. The parasite is present in the tick salivary glands and is passed to Man via tick bite. Once in the bloodstream, the parasites enter the erythrocytes. Infection with *B. microti* ranges from asymptomatic to severe illness. Symptoms generally resemble those of malaria with fever, rigors, myalgia, and malaise. Occasionally there is mild or moderate hemolytic anemia and jaundice (renal failure). Parasitemia can be up to 25% in the immunocompetent individual, and up to 80% in patients who have been splenectomized.

Other Medically Important Hard Ticks

General Characteristics

Several other species of ticks are also responsible for the spread of disease throughout the world. Wood ticks (*Dermacentor andersoni*) are found in the mountainous west of North America; dog ticks (*Rhipicephalus*) are found in coastal areas. Lone Star ticks (*Amblyomma americanum*) are found in forests in SE USA where deer are found. The females of these species are known to cause a condition known as tick paralysis.



Image 12-7. *Amblyomma*, hard tick. The scutum is so-called 'enameled' colored areas, and is described as being an ornate species. (SOURCE: PHIL 5981 – CDC)



Image 12-8. *Dermacentor variabilis*, ticks of this species show very ornate scutums, covering the length of the body (left - male). When blood engorged it is harder to see the scutum (right - female). (SOURCE: PHIL 5977 – CDC)

Life Cycle

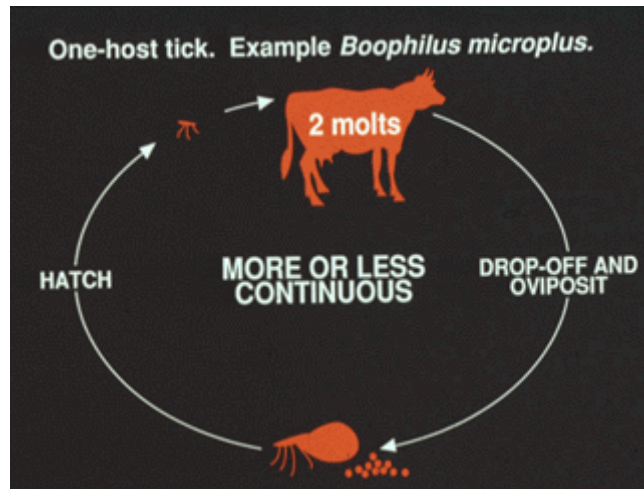


Illustration 12-2. One-host tick life cycle. (SOURCE: CDC)

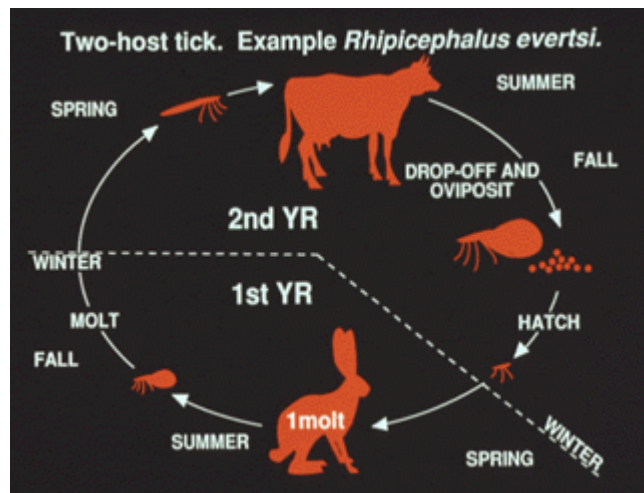


Illustration 12-3. Two-host tick life cycle. (SOURCE: CDC)

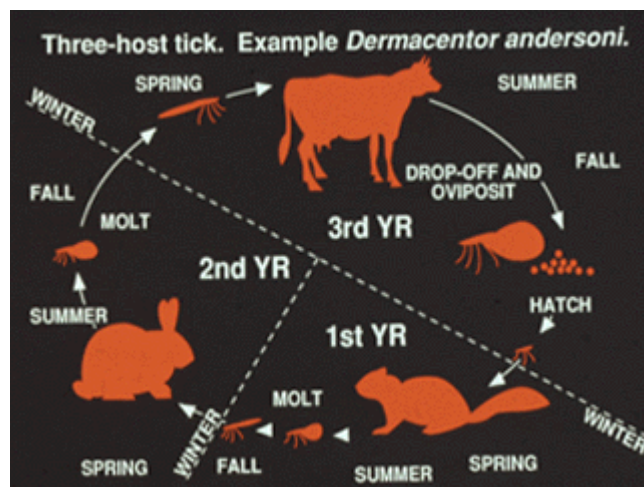


Illustration 12-4. Three-host tick life cycle. (SOURCE: CDC)

Hard Ticks have a hemimetabolous life cycle similar to that of the soft ticks. Hard tick larvae search for suitable hosts feed for several days, and drop off engorged to the ground below. Molting to the nymph stage follows several days later and the tick again searches for a suitable blood source. There is only one nymphal stage in *Ixodes*, and following several weeks of stasis the nymph will molt into an adult. Females lay one large mass of eggs, which forms a cellular mass on the scutum of the ovipositing female.



Image 12-9. Female tick with egg mass. (SOURCE: PHIL 5968 – CDC)

Diseases

Both *Dermacentor* and *Amblyomma* transmit Rocky Mountain Spotted Fever (*Rickettsia rickettsia*). The different strains transmitted by these species vary in their virulence and subsequent manifestation of the disease. *Dermacentor* are known to transmit serious arboviruses responsible for encephalitis and hemorrhagic fevers. *D. variabilis* are also responsible for spreading tularemia (*Francisella tularensis*) and human granulocytic ehrlichiosis (*Ehrlichia chaffeensis*). *Rhipicephalus sanguineus* transmits Mediterranean Spotted Fever and African Tick Typhus.

Tick Paralysis

Hard ticks inject into the body with their saliva certain toxins that can cause a condition in people and animals called tick paralysis. It appears 5-7 days after a tick begins feeding, paralyzing the legs and affecting speaking ability, swallowing and breathing. It occurs worldwide and is most common and severe in children aged up to two years. Treatment involves removing the tick.

Tick-borne Rickettsial Fevers

This group of diseases is caused by closely related *Rickettsia* microorganisms transmitted by tick bites or contamination of the skin with crushed tissues or feces of the tick.

- Spotted fever due to *Rickettsia rickettsii* occurs in Brazil, Canada, Colombia, Mexico, Panama and the USA.
- Spotted fever due to *R. sibirica* occurs in Japan, the Russian Federation and the Pacific.
- Spotted fever due to *R. conori* is found in the Mediterranean region, Africa and southern Asia.
- Spotted fever due to *R. australis* occurs in Queensland, Australia.
- Q fever, caused by *Coxiella burnetii*, has a worldwide distribution and is commonly present in abattoirs, meat-packing and meat-rendering plants, diagnostic laboratories, stockyards and poultry farms. It is transmitted to humans mainly by the consumption of milk and meat from contaminated cattle or the inhalation of dried infected tick feces by people working with cattle.

Symptoms in humans are sudden fever persisting for several weeks, malaise, muscle and joint pains, severe headache and chills. A rash sometimes spreads over the entire body. Death may result in about 15-20% of persons if the disease is misdiagnosed or left untreated.

Treatment

Antibiotics such as tetracycline or chloramphenicol can be used.

Prevention

Tick bites should be avoided and attached ticks should be removed rapidly and carefully. Several hours of attachment are needed before the *Rickettsia* organisms can infect humans.

Lyme Disease

Lyme disease (erythema chronicum migrans) is a severe and often debilitating condition caused by a spirochete, *Borrelia burgdorferi*. Acute Lyme disease is a flu-like illness, characterized by an expanding red rash in about 50% of patients, accompanied by fever, fatigue, and muscle and joint pain. Weeks or even months after the infecting tick bite, patients may experience swelling and pain in large joints (knee, elbow), encephalitis, facial palsy, ocular lesions and carditis, irrespective of whether a rash occurred in the acute phase. Later, perhaps years after the bite, there may be cartilage erosion (arthritis) and neuromuscular dysfunction (Fig. 4.29). Lyme disease occurs principally in northern temperate regions of the world, including China, Europe, the USA and the former USSR.

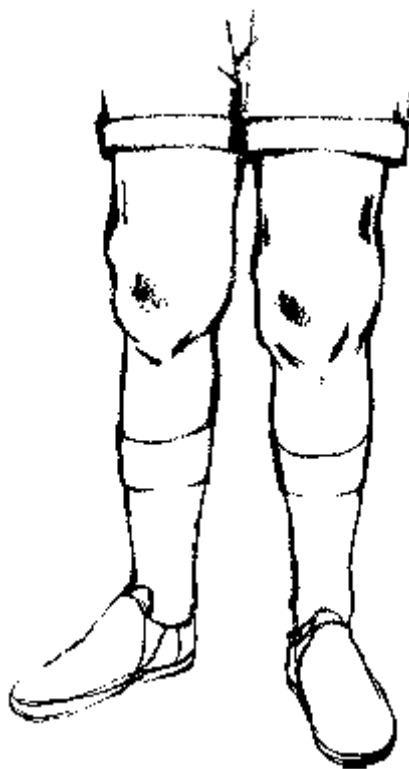


Illustration 12-5. A typical symptom of Lyme disease is swelling and pain in the large joints, such as the knees, and chronic arthritis. (SOURCE: Unknown)

Transmission

The disease is transmitted mostly by *Ixodes* ticks, commonly in the summer when the nymphs are abundant. Small rodents, especially mice, serve as reservoirs of infection while large mammals serve principally as hosts maintaining tick populations. The larvae acquire infection while feeding on mice, and nymphs or adults can transmit spirochetes during subsequent blood-meals. In the northern temperate zone, where it occurs most intensely, Lyme disease has become more common as deer populations have increased and as this critical host has

adapted to living in closer proximity to people. In many areas, Lyme disease is acquired in the suburban residential environment.

Treatment

Further development of the disease in adults may be reduced or prevented by treatment with tetracycline or its derivatives for 2-4 weeks, and in children by treatment with penicillin.

Prevention

Prevention requires avoidance of tick habitats and bites, and vector control. Personal protection may be possible by the use of repellents on the skin and clothing in tick-infested areas. The removal of attached ticks within 24 hours may prevent spirochete transmission. Prophylactic antibiotic therapy may be desirable following the bite of an infected tick. New molecular assays are commercially available for detecting the spirochetes in tick samples.

Tularemia

Tularemia, also known as rabbit fever, deerfly fever and O'Hara disease, is caused by the infectious agent *Francisella tularensis*. The symptoms, which vary according to how the agent enters the body, include headache, chills, fever and the swelling of lymph nodes. The disease occurs in Europe, Japan, North America and the former USSR.

Transmission

Transmission takes place through the bites of ticks and deerflies (see Chapter 1) or as a result of handling infected animals such as rabbits and other game. Hunters and forest workers are at the highest risk of infection.

Treatment

Antibiotics such as streptomycin can be used to treat the disease.

Prevention

Tick bites and tick habitats should be avoided, impermeable gloves should be worn when skinning and dressing game animals, wild game meat should be thoroughly cooked, and untreated drinking-water should be avoided in areas where the disease occurs.

Tick-borne Viral Encephalitides

This is a group of viral diseases causing acute inflammation of the brain, spinal cord and meninges. The symptoms vary in severity with the type of disease. Many infections do not result in disease. Severe infections may cause violent headaches, high fever, nausea, coma and death.

- Far Eastern tick-borne encephalitis is found in the far east of the former USSR.
- Central European tick-borne encephalitis occurs in Europe from the Urals to France.
- Louping ill is a disease of sheep in the United Kingdom which sometimes affects people.

Transmission and Prevention

These diseases are transmitted by biting ticks and by the consumption of milk from infected animals. No specific treatment is available but vaccines have been developed against some of the diseases. Prevention requires avoidance or rapid removal of ticks.

Principal Hard Tick Vectors

Usually various tick species act as vectors for any one disease and their importance varies from region to region.

Disease	Vector
Lyme disease	Deer tick (<i>Ixodes scapularis</i>)
Spotted fever due to:	
• <i>Rickettsia rickettsii</i>	American dog tick (<i>Dermacentor variabilis</i>)
• <i>Rickettsia sibirica</i>	Asiatic wood tick (<i>Dermacentor silvarum</i>)
• <i>Rickettsia conori</i>	Brown dog tick (<i>Rhipicephalus sanguineus</i>)
• <i>Rickettsia australis</i>	Wattle tick (<i>Ixodes holocyclus</i>)
Q fever	Lone star tick (<i>Amblyomma americanum</i>)
Tularemia	American rabbit tick (<i>Haemaphysalis leporispalustris</i>)
Far Eastern tick-borne encephalitis	Taiga tick (<i>Ixodes persulcatus</i>)
Central European tick-borne encephalitis	Castor bean ticks (<i>Ixodes ricinus</i>)
Kyasanur Forest disease	A tick of birds and monkeys (<i>Haemaphysalis spinigera</i>)
Colorado tick fever	American wood tick (<i>Dermacentor andersoni</i>)
Crimean-Congo hemorrhagic fever	A tick of birds and mammals (<i>Hyalomma marginatum</i>)

Table 12-1. Principle Hard Tick Vectors

Other Viral Diseases

Kyasanur Forest disease occurs in parts of India.

Omsk hemorrhagic fever is found in south-western Siberia; it causes severe disease and death in muskrat handlers; it is mainly waterborne, although it is found in hard ticks.

Colorado tick fever is a moderately severe disease that occurs in western North America.

Crimean-Congo hemorrhagic fever is an acute, often severe and fatal disease found in parts of Africa, Asia and Europe.

Mites

Class: Arachnida

Subclass: Acari

Order: Astigmata

Family: Pyroglyphidae

Genus: *Dermatophagoides* (Dust mites)

Family: Sarcoptidae

Genus: *Sarcoptes* (Scabies mites)

Order: Prostigmata

Family: Democidae

Genus: *Demodex* (Hair follicle mite)

Order: Mesostigmata

Genus: *Leptotrombidium* (Other Mites)

General Characteristics

Dermatophagoides, the common dust mite, commonly inhabit beds, mattresses, carpets and house dust. They are motile and feed on residual organic debris and are typically 0.3 μm in length. They characteristically have four long legs with suckers and pincer chelicerae.



Image 12-10. A Dust Mite (*Dermatophagoides*). They commonly inhabit mattresses, carpets and house dust.

Demodex folliculorum mites are 300 microns in length, live in the follicle for 5-6 days and migrate onto contiguous skin at night. Classically, they appear as 1 μm "sleeves" around the base of the eyelashes.

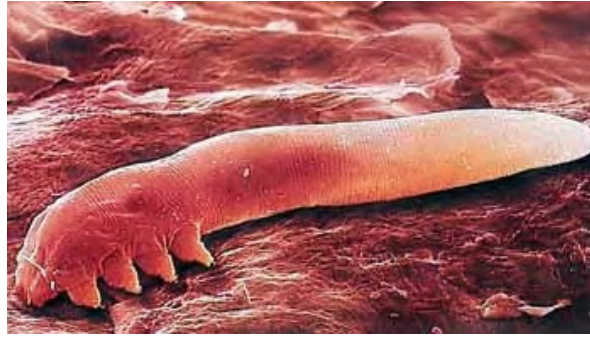

Image 12-11. *Demodex folliculorum* (SOURCE: CDC)

The mite, *Sarcoptes scabiei*, lives exclusively on human skin and causes scabies. It is small (the larger female is 0.3-0.4 μm), colorless and oval with 8 short legs.

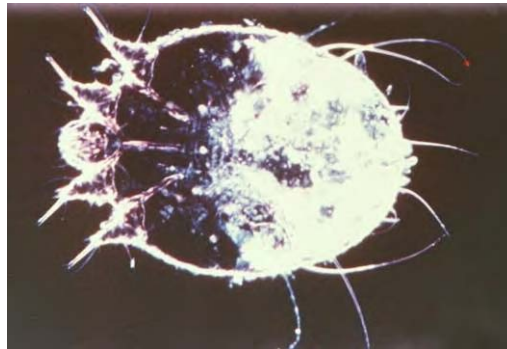


Image 12-12. Picture of the human parasite scabies (*Sarcoptes scabiei*). They live exclusively on human skin causing the condition known as scabies. (SOURCE: PHIL 3810 - CDC/Joe Miller/Reed and Crnrick pharmaceuticals.)

Leptotrombidium adults are normally reddish and covered with velvet like hair. It is the larvae that are parasitic and they too regularly appear reddish, but only have three pairs of legs. The palps are segmented, and the mouthparts are large and easily identifiable. *Leptotrombidium* larvae are distinguished by large eyes, two feathered sensillae and five feathered setae that are present on the scutum.



Image 12-13. *Leptotrombidium* (SOURCE: CDC of Taiwan)

Disease and Control

Dermatophagoides are antigenic, even when dead (fecal pellets are also allergenic), and are associated with complex allergies with symptoms such as asthma, perennial rhinitis, conjunctivitis and atopic dermatitis. A diagnosis can be made using reactive skin tests and treatment involves removal of accumulated antigens from mattresses and pillows.

Demodex have been implicated in dermatitis, acne and should be considered in chronic, therapy-resistant cases of blepharitis. The role of this mite in ocular disease is uncertain. Washing with soap and water is the most effective method of prevention.

Symptoms of *Sarcoptes* infection arise after 4-6 weeks and comprise a papular pruritic eruption at a site often unrelated to the site of infestation; symptoms of secondary infestations arise almost immediately. Zoonotic scabies have shorter incubation periods but are also self-limiting. Persistent nodular scabies comprises itchy erythematous or scabbed nodules, often on the penis. When the immune system is impaired, Norwegian (crusted) scabies may develop: this presents with erythema and hyperkeratosis but little itching.

Diagnosis demands discovery of the mites, scybala or eggs by epidermal shave biopsy or superficial scraping. Burrows are best seen on wrists and interdigital spaces. They fluoresce under a Wood's lamp after application of liquid tetracycline and, later, alcohol; alternatively ink may be used. Lindane (Quellada) lotion is the treatment of choice in the USA; permethrin or crotamiton are alternatives. Ivermectin has been recommended for Norwegian scabies. Malathion (Derbac-M) liquid or permethrin are recommended in the UK (benzyl benzoate is also active). Malathion should be avoided in infants and lindane should be avoided in pregnancy, breast-feeding and young children. Treatment is applied over the whole body except the head and neck and washed off after 24 hours. Normal laundering of bed linen and clothes is recommended. Household and sexual contacts should also be treated. Symptoms may continue after treatment because of persisting antigens, Calamine or Eurax lotion may be used; other problems include reinfestation and secondary bacterial infection.

Feeding by *Leptotrobium* causes cellular damage and initially results in intense itching and irritation for the host. The agent of scrub typhus, *Rickettsia tsutsugamuchi*, is often transmitted by the larval trombiculid mite. Scrub typhus results in infection in those living or working near 'mite islands' which are usually found in transitional vegetation and provide a stable environment for mite proliferation. Prevention has generally been with chemical repellents or herbicides to remove the scrub habitat.

Mosquitoes

Class: Insecta
Order: Diptera
Family: Culicidae
Subfamily: Anophelinae
Genus: *Anophele*
Subfamily: Culicinae
Genus: *Culicine*

		
<p>Anopheles (SOURCE: PHIL 7949 – CDC)</p>	<p>Aedes (SOURCE: PHIL 9261 - CDC/ Prof. Frank Hadley Collins, Dir., Cntr. for Global Health and Infectious Diseases, Univ. of Notre Dame)</p>	<p>Culex (SOURCE: PHIL 7957 – CDC)</p>

Image 12-14. *Anophele* and *Culicine* mosquitoes.

Introduction

Mosquitoes are small with a clearly demarcated body and very long slender legs. The head contains a large pair of kidney shaped compound eyes, a pair of antennae, and a single long proboscis for feeding. The thorax, abdomen and wings are often covered with scales. Differential coloration and pattern of these scales provides a means of visually distinguishing species. The large wings are folded over the segmented abdomen, which generally appears brown-black and slender but turns a bright red and swells following feeding.

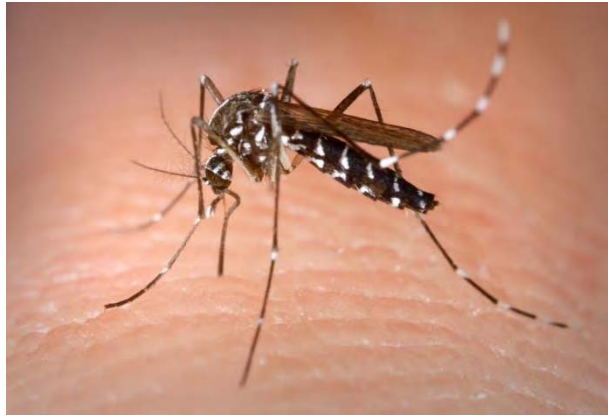

Image 12-15. Image of a typical Culicine mosquito. Adults are generally brown – black, at rest they palce their abdomens parallel to the ground. (SOURCE: PHIL 4487 – CDC)

Mosquitoes may be classified as Anopheline (Anopheles) or Culicine (Aedes, Culex). The antennae of male mosquitoes are plumose (many feathery hairs); females are pilose (few spidery hairs). The male Anopheline palps are long and clubbed; those of the male Culicine are long but not clubbed. The female Anopheline palps are long; the female Culicine are short. If a mosquito is incorrectly sexed, a female Anopheline may be confused with a male Culicine.

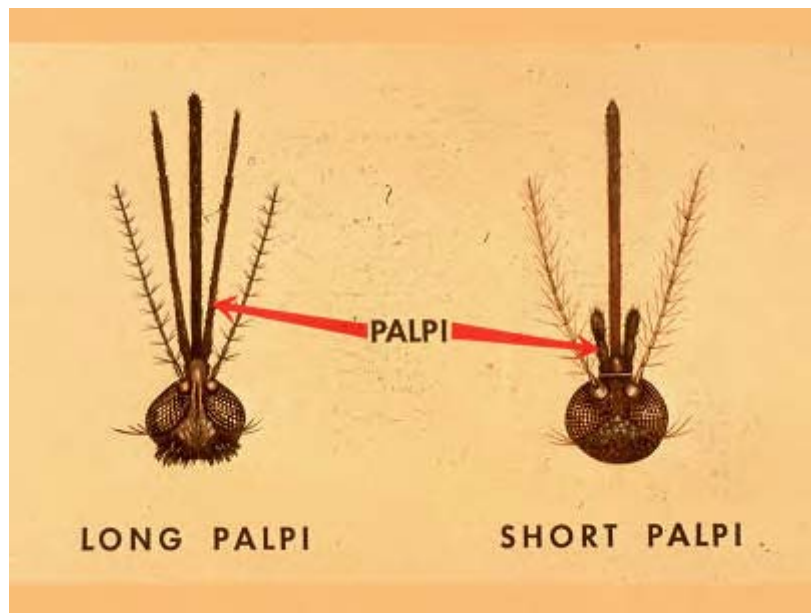


Illustration 12-6. Image of typical male Anopheline mosquito showing the characteristic features of the mosquitoes head; the palps are as long as the proboscis with clubbed like ends and the antennae are plumose. The female Culicine mosquito shows the short palps and the pilose antennae. (SOURCE: CDC)

At rest, Anophelines usually position their abdomens at an angle to the surface; Culicines maintain their abdomen in a parallel position.

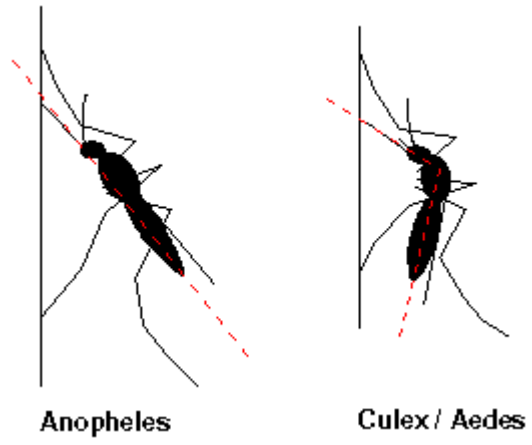


Illustration 12-7. Typical *Anopheline* and *Culicine* at rest, showing the abdomen at an angle to the surface. (SOURCE: CDC)

Anopheline (*Anopheles*) Mosquitoes

Class: Insecta
Order: Diptera
Family: Culicidae
Subfamily: Anophelinae
Genus: Anopheline
Species: *Anopheles*



Image 12-16. Typical *Anopheles* mosquitoes (SOURCE: PHIL 7862 – CDC)

General Characteristics

Anopheles mosquitoes are characterized by dark and pale scale blocks arranged on their wings. They have palps that are of equal length to the proboscis, which appear terminally clubbed in males. *Anopheles* always rest at an angle when standing on surfaces and preferring

to feed at twilight or night. Breeding sites are varied but Anopheles prefer unpolluted fresh or saltwater.

Life Cycle

Anopheles lay 50 to 200 dark color eggs in aquatic environments, and hatch in several days to several weeks depending on the external temperature. Anopheles larvae have a dark brown head and 6-7 anterior segments covered with dorsal palmate hairs. Accessory tegral plates are present on the dorsal side of segments 1-10 and two sets of anal papillae emerge from the last abdominal segment.

There are four larval instars that survive by filter feeding and breathing oxygen through their spiracles. Anopheles larvae occur throughout many different habitats including both permanent marshes and swamps, and temporary locations such as pots filled with water. In general Anopheles prefer to inhabit clean habitats. The larval period lasts about a week, but may be extended depending on the environmental conditions. The pupa is comma shaped with a set of trumpet shaped breathing tubes. The abdomen is covered with setae, and segments 2-7 have distinct spines. The pupal period may last a few days to weeks depending on the temperature.

Disease - Malaria

Anopheles are vectors of malaria, Bancroftian and Brugian filariasis and of multiple arboviruses (dengue fever; yellow fever; encephalitides and hemorrhagic fevers). Malaria is caused by *Plasmodium falciparum*, *P. vivax*, *P. malariae* and *P. ovale*. Transmission of the disease occurs in virtually all of tropical Africa, Central and South America, and the Middle and Far East. South East Asia is a particular problem due to multiple drug resistance. *P. falciparum* is found in Africa and other tropical countries as well as in subtropics. *P. malariae* has a low prevalence in both tropics and subtropics. *P. vivax* is the most widespread in temperate regions and subtropics but may also be found in the tropics. *P. ovale* has a low prevalence in West Africa. In Africa alone, 370 million people live in endemic areas.

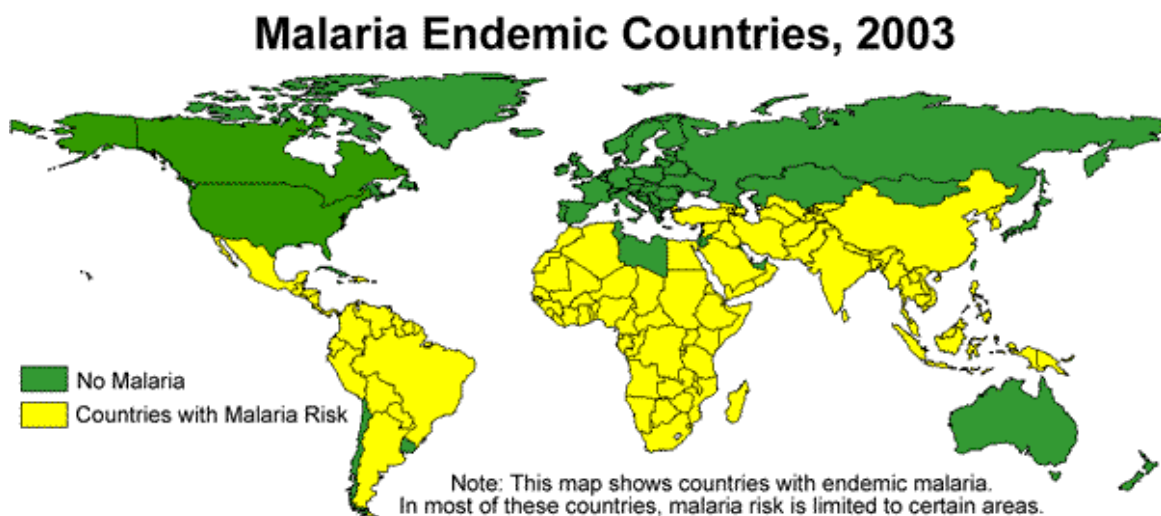


Illustration 12-8. World map showing the distribution of malaria. (CDC)

P. vivax causes benign tertian malaria (43% of cases) and *P. falciparum* results in malignant tertian or sub-tertian malaria and pernicious malaria (50% of cases). *P. ovale* (mild tertian malaria, 1% of cases) and *P. malariae* (quartan malaria, 7% of cases) contribute a small percentage of malarial cases.

Clinical features including fever and chills are due to the host inflammatory response and are associated with rupture of erythrocytic schizonts. Fever presents in three stages - **a)** Cold: rigors and fever lasting 15 minutes to 1 hour; **b)** Hot: the patient is flushed with tachycardia and is pyrexial (40C) for 2-6 hours; **c)** Sweating: the temperature falls (over 2-4 hours). Each paroxysm lasts 8-12 hours in total. All erythrocytes containing a trophozoite will be destroyed within 48-72 hours. Periodic fever often takes more than seven days to develop, and anemia can be hemolytic or due to toxic marrow suppression. Splenomegaly occurs in all malaria: it may be acute or chronic (+/- hypersplenism). Jaundice may be hemolytic and/or hepatic (only *P. falciparum*). In addition, there may be headache, myalgia, arthralgia, diarrhea and vomiting.

Plasmodium falciparum is the most virulent form (invades mature and immature RBCs) and is often fatal if untreated. Blood schizogony takes place in deep capillaries and micro-circulatory failure can occur in individuals with little immunity to malaria. It does not relapse but recrudescence may occur. The time between paroxysms is 48 hours but fever may last for 24-36 hours. Very rapid progression and complications include diarrhea and vomiting; delirium; coma; convulsions; renal failure, including hemoglobinuria (blackwater fever); jaundice; pulmonary edema; hypoglycemia and abortion. Cerebral malaria often results in delirium, disorientation, stupor, coma, convulsions and death.

P. vivax / ovale exhibit 48 hours between paroxysms; relapses may occur up to 8 years after primary infection and only infects immature RBCs of those with Duffy blood group. *Plasmodium malariae* generally results in 72 hours between paroxysms, only infects older RBCs, and recrudescence may occur decades after primary infection.

The global malaria situation is serious and becoming worse: 300-500 million clinical cases occur annually. 1.5-2.7 million people die of malaria each year with approximately one million deaths among children under five years of age are attributed to malaria alone or in combination with other diseases. Countries in tropical Africa account for more than 90% of the total malaria incidence and the great majority of malaria deaths (WHO data). The death toll of African children with malaria is expected to double by 2010, conceivably reaching four million deaths per year. Many factors influence the epidemiology of this disease including: breeding habits of the various mosquito vectors; agricultural practices; economic conditions; industrialization and pesticide use. Increasing air-traffic from malaria endemic areas has led to the possibility of malaria developing in non-endemic areas where the mosquito vector has been imported onboard aircraft.

Treatments and Control - Malaria

If the infective species is not known, or the infection is known to be mixed, initial treatment should be with quinine, mefloquine or rarely halofantrine. Falciparum (malignant) malaria is

often resistant to chloroquine and should be treated with quinine, mefloquine, halofantrine, quinidine or pyrimethamine-sulphadoxine. Benign malaria (*P. vivax*) should be treated with chloroquine although resistance has been reported from New Guinea. Malarial prophylaxis is relative and not absolute.

The UK Consensus Group on Malaria Prophylaxis (1997) recommend mefloquine for UK travelers to West, Central and East Africa for periods of greater than two weeks and for travelers to specific areas within south-east Asia: prophylaxis should be commenced two weeks before departure. Doxycycline can be used in older children and adults who cannot tolerate mefloquine.

Prevention is most dependent upon coverage of exposed skin and the use of insect repellent, mosquito nets impregnated with permethrin and correct prophylaxis. The vector may be controlled by water clearance programs, house spraying (DDT) and destruction of breeding areas. Drug resistance to DDT and ethical resistance to its use have limited its effectiveness. Natural immunity involves both antibody and cell-mediated systems and appears to require frequent boosting; antigens from different stages of the parasite's life cycle will be important in vaccine development.

Disease - Filariasis

Anopheline mosquitoes also transmit the filarial worms *Wuchereria bancrofti*, *Brugia malayi* and *Brugia timori*. *Wuchereria bancrofti* is the main cause of "elephantiasis" (Bancroftian filariasis) and the most widely distributed filarial parasite of man. The adults live in the lymphatic system, and can survive for 30 years or more. Once they have mated they produce a pre-larval form, the microfilaria. Both the adults and the microfilaria may play a role in generating the symptoms and signs. Microfilaria measure 240-300 μ m in length by 7-10 μ m in width. They are sheathed (derived from ovum membrane) and nuclei terminate 15-20 μ m proximal to the pointed tail. There are fewer, more distinct nuclei than in other species and there are less body curves. Adult worms are slender and white (males 4cm; females stout and 10cm in length)

Initial infection with *Wuchereria* is usually asymptomatic. There may be recurrence of attacks of "cellulitis" affecting the limbs, breast, scrotum or elsewhere. Infection is associated with fever, lymphangitis, lymphadenopathy and occasionally abscess formation. These initially settle but later on the tissues eventually become edematous and hypertrophied. Further effects may include scrotal involvement and hydrocoele, which can lead to scrotal enlargement and lymph scrotum. This is "elephantiasis" and is associated with dermal hypertrophy, verrucous changes and the rupture of lymph varices into various sites.

Brugian (Malayan) filariasis is less widespread, less common and less serious than its Bancroftian counterpart. The life cycle is identical to that of *Wuchereria bancrofti* with *Brugia malayi* limited to Asia and *B. timori* restricted to Indonesia. Infection results in lymphadenopathy involving most frequently the inguinal area, lymphoedema normally below the knee, eosinophilia, and in rare cases chyluria.

Treatments and Control - Filariasis

Diethylcarbamazine (DEC) kills microfilaria. Ivermectin suppresses microfilaria production but its overall effectiveness remains untried and elephantiasis can be treated surgically. Control measures comprise draining of mosquito breeding sites and killing larvae. Many mosquitoes are resistant to insecticides but mosquito repellents and nets are effective. The infective pool may be reduced by periodic mass treatment with DEC. *Brugia malayi* is more susceptible to diethylcarbamazine (DEC) than is *Wuchereria bancrofti*. Anopheline larvae may be suffocated in their breeding sites but Culicine larvae (*Mansonia* sp.) derive oxygen from plants and are not vulnerable to such measures. Control depends upon the use of mosquito nets and periodic mass treatment.

Culicine (*Aedes*) Mosquitoes

Class: Insecta
Order: Diptera
Family: Culicidae
Subfamily: Culicinae
Genus: Culicine
Species: *Aedes*

General Characteristics

Aedes can generally be distinguished by patterns of black and silvery scales present on the abdomen and thorax. The legs appear to have black and white rings along their length. The wings are generally covered with black scales. *Aedes* breed in marshes and other wetland areas and have a worldwide distribution.

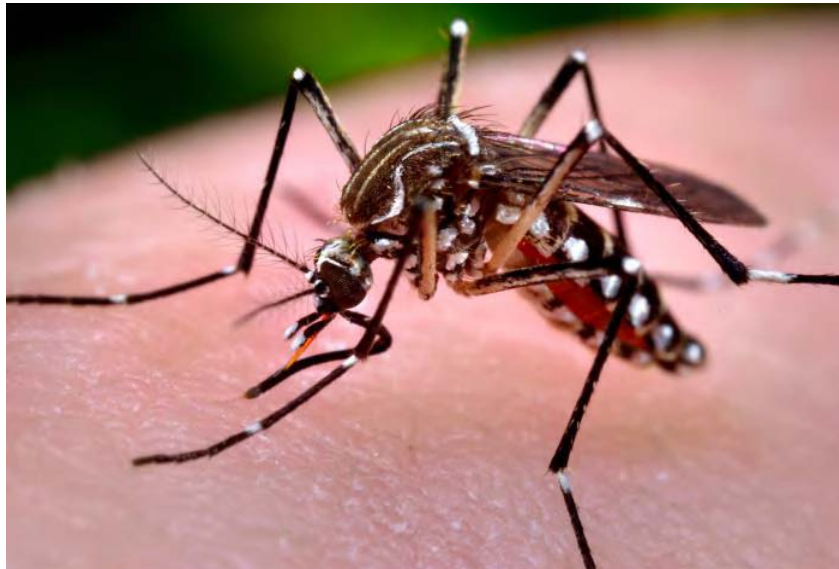

Image 12-17. Typical *Aedes* mosquito. They are clearly distinguished from Anopheline mosquitoes due to the presence of black and silvery scales on the abdomen and thorax. (SOURCE: PHIL 9252 - CDC/ Prof. Frank Hadley Collins, Dir., Cntr. for Global Health and Infectious Diseases, Univ. of Notre Dame)

Life Cycle

Female *Aedes* lay eggs on damp areas such mud, detritus, clay and rock. The eggs are very robust and can survive desiccation and other environmental pressures. The eggs hatch in waves depending on the environmental cues. *Aedes* larvae have a stout barrel shaped siphon with one pair of subventral tufts. There are three pairs of setae on the ventral brush, and large setae are not present on the abdominal segments.

Disease

Aedes are vectors of Bancroftian filariasis and arboviruses such as yellow fever and dengue. *Wuchereria bancrofti* is the main cause of "elephantiasis" (Bancroftian filariasis) and the most widely distributed filarial parasite of Man. The adults live in the lymphatic system, and can survive for 30 years or more. They copulate and generate a pre-larval form, the microfilaria. Both the adults and the microfilaria may play a role in generating the symptoms and signs. Microfilaria measure 240-300 μ m in length by 7-10 μ m in width. They are sheathed (derived from ovum membrane) and nuclei terminate 15-20 μ m proximal to the pointed tail. There are fewer, more distinct nuclei than in other species and there are less body curves. Adult worms are slender and white (males 4cm; females, stout and 10cm in length).

Initial infection with *Wuchereria* is usually asymptomatic. There may be recurrence of attacks of "cellulitis" affecting the limbs, breast, scrotum or elsewhere. Infection is associated with fever, lymphangitis, lymphadenopathy and occasionally abscess formation. These initially settle but later on the tissues eventually become edematous and hypertrophied. Further effects may include scrotal involvement and hydrocoele, which can lead to scrotal enlargement and lymph scrotum. This is "elephantiasis" and is associated with dermal hypertrophy, verrucous changes and the rupture of lymph varices into various sites.

Yellow fever and dengue hemorrhagic fever are serious viral infections spread by the *Aedes* mosquito. Dengue is now the most important mosquito borne virus, with global infection increasing.

Control and Treatment

In general the most effective control for Culicine mosquitoes are repellents and fine screening or netting. Treatment with insecticides will also serve to reduce the vector population, but increased problems are encountered with Culicines because they also feed during the daytime. If filarial infection occurs, treatment with Diethylcarbamazine (DEC) will kill microfilaria. Ivermectin suppresses microfilaria production but its overall effectiveness remains untried and elephantiasis can be treated surgically.

Culicine (*Culex*) Mosquitoes

Class: Insecta

Order: Diptera

Family: Culicidae

Subfamily: Culicinae

Genus: Culicine

Species: *Culex*

General Characteristics

Culex are distinguished by their lack of coloration and feature. The thorax, abdomen, legs and wings are often covered with brown-black scales giving a generally dark appearance. The abdomen may occasionally also have white scales arranged in segments. *Culex* breeds mainly in aquatic habitats, often in areas containing large quantities of organic waste.



Illustration 12-8. Typical illustration of a *Culex* mosquito, showing the characteristic brown-black scales on the thorax, abdomen, legs and wings giving it a general dark appearance. (Illustration: Trustees of the British Museum)

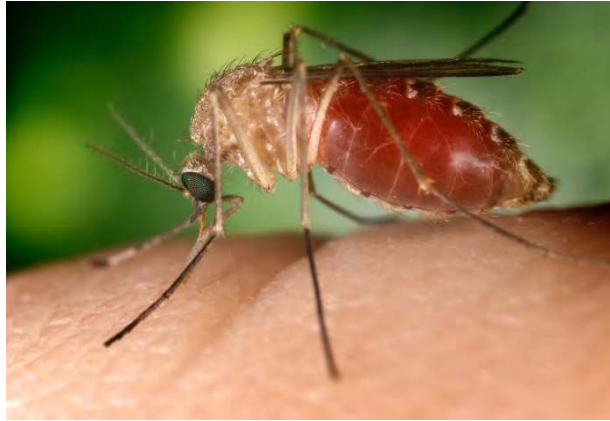

Image 12-18. A *Culex* mosquito taking a blood meal from a human host. The abdomen becomes distended and blood red in color. (SOURCE: PHIL 4464 - CDC/Jim Gathany)

Life Cycle

Female *Culex* lay dark brown eggs in characteristic clumps of approximately 300 eggs. As mentioned these eggs are often found in organic waste deposits or polluted waters. *Culex* larvae have a long and narrow siphon with more than one pair of subventral tufts.

Disease

Culex mosquitoes are vectors of Bancroftian filariasis throughout Africa, but most importantly arboviruses such as Japanese encephalitis. Encephalitis occurs throughout the world, with *Culex* acting as an important vector for spread and infection. *Culex* mosquitoes are similar to Culicine mosquitoes, but prefer to bite at night and breed in organic refuse.

Control and Treatment

Culex mosquitoes are most easily controlled by improving sanitation and removing static water sources from the affected area. In general the most effective control for *Culex* mosquitoes are also repellents and fine screening or netting. Treatment with insecticides will also serve to reduce the vector population, but increased problems are encountered with Culicine mosquitoes because they also feed during the daytime. If filarial infection occurs treatment with Diethylcarbamazine (DEC) will kill microfilaria. Ivermectin suppresses microfilaria production but its overall effectiveness remains untried and elephantiasis can be treated surgically.

Tsetse Flies

Class: Insecta
Order: Diptera
Family: Glossinidae
Genus: *Glossina*

General Characteristics

Tsetse flies are large, yellow-brown or brown-black and measure 6-15µm in length. They are distinguished by a rigid projecting proboscis and a long pair of accompanying palps. There is a characteristic axe-shaped venation of the wings when viewed dorsally resembling an inverted hatchet in the central cell. The antennae appear short and feathery, and the abdomen is segmented and often striped or patched. Both males and females suck blood every 4-5 days, outside in open spaces.



Image 12-19. Typical illustration of a *Tsetse Fly*. They are yellow-brown in colour and usually measure 6 – 15µm in length. Their characteristic feature is the hatchet shaped cell in the centre of the wing venation. (IMAGE SOURCE: Trustees of the British Museum)

Life Cycle

Female Tsetse flies are unique in the sense that they deposit larvae and do not lay eggs. The eggs mature within the female and are supplied with essential nourishment to complete larval development. This cycle requires a large number of blood meals to maintain and thus the female requires regular feeding. The larvae are normally deposited in shaded areas. There are three larval instars with the mature larva appearing white, visibly segmented with a pair of lobes at the posterior end. Pupation of the third instar results in a dark colored puparium with posterior lobes. The pupal period is extended (3-7 weeks) depending on the surrounding environmental conditions.

Disease

Tsetse flies are vectors for African sleeping sickness (*Trypanosoma brucei* sp. The two subspecies of *T. brucei* that infect Man are morphologically identical. *T. b. gambiense* causes Gambian sleeping sickness in Western Africa and *T. b. rhodesiense* causes Rhodesian sleeping sickness in East Africa. Another subspecies, *T. b. brucei*, causes nagana in cattle.

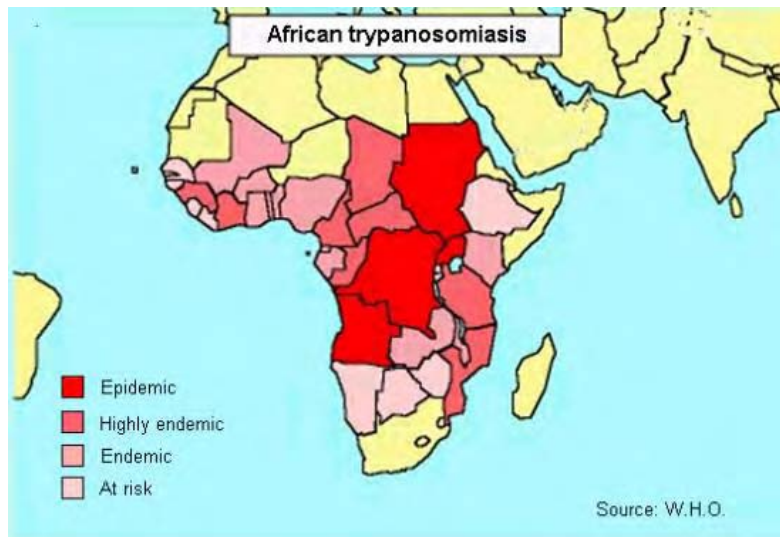


Illustration 12-9. Distribution of African Trypanosomiasis throughout Africa (WHO, 1991)

Initially the patient has a headache, fever, chills and loss of appetite but specific clinical signs are absent. Parasitaemia comes in characteristic waves. Later, the spleen, liver and lymph nodes enlarge (Winterbottom's sign). Finally, there may be CNS involvement leading to coma and death within several years. *Trypanosoma brucei rhodesiense* (rural East Africa): this is so acute that the patient invariably dies before classical symptoms develop. Without appropriate treatment, both forms are fatal.

Human African trypanosomiasis is rural and focal, with humans as the principal reservoir of infection of *T. b. gambiense*, and domestic cattle and wild animals as important reservoirs of *T. b. rhodesiense*. By the 1960s, it had been brought under control, but since 1970 the situation has deteriorated and the disease has reappeared, with major flare-ups in countries which have not maintained surveillance activities. It is estimated that 55-60 million people are exposed to the risk of becoming infected with trypanosomiasis, but only four million of them are under

active surveillance or have access to health centers where reliable diagnosis is available: the estimated number of infected persons is over 300,000 (WHO data).

Treatment and Control

Anemia and other infections should be treated first. If given before the parasite has invaded the brain (hemolymphatic stage), suramin (Rhodesian disease) or pentamidine (Gambian disease) appear to be effective. For late disease (CNS involvement), drugs of choice are melarsoprol or eflornithine, with tryparsamide plus suramin as an alternative. Tsetse-infested areas should be avoided. Protective, light-colored clothing and repellents should be used. Tsetse flies are difficult to treat with insecticide (DDT has been tried) as their larvae live in burrows in the ground; protective vegetation must first be removed. Pentamidine prophylaxis is no longer advocated. Reservoir hosts should be identified and removed. It is possible to breed resistant or tolerant cattle (West Africa). Trypanosomes other than *T. brucei* are also transmissible by Tabanid flies or by sexual contact.

Sand Flies

Class: Insecta

Order: Diptera

Family: Psychodidae

Genera: *Phlebotomus*, *Lutzomyia*

Introduction

Sandflies are small (1.5-5µm) with a hairy head, thorax, antennae and wings. The antennae are long, may appear beaded, and protrude near a large set of black compound eyes. The wings are upwardly pointing at rest, and are a distinctive feature of Phlebotomine sandflies. Only the females are blood feeders, the males feed on plant nectar. Biting predominates nocturnally and they rest in moist and dark walls, cracks and tree trunks during the day.

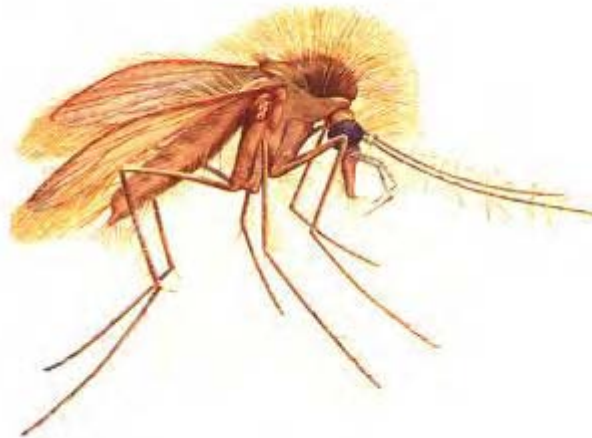


Illustration 12-10. Typical illustration of a Sand Fly. The head, thorax, abdomen, legs and antennae are hairy, they are small usually measuring 1.5-5µm long. (*Phlebotomus*) (Illustration Source: Trustees of the British Museum)

Life Cycle

Female Phlebotomine sandflies deposit 30-70 minute eggs at each oviposition. The eggs are laid in dry areas, but require humidity to avoid desiccating. There are four instars and the mature larva is characterized by a distinct black head, 12 segments, thick bristles covering the body, and two pairs of caudal setae on their posterior end. As with other fly vectors the length of the larval stage depends on the ambient temperature, species in question, and food

availability. The larval skin and caudal bristles remain attached at the posterior end during the pupal stage which lasts 5-10 days.

Disease

Sandflies are the only vectors for several species and subspecies of obligate intracellular protozoa responsible for leishmaniasis (*Leishmania* sp.) Cutaneous, mucocutaneous and visceral leishmaniasis are caused by different species of *Leishmania* contentiously linked to temperature preferences. Geographic location and host immune response also play a role in determining the form of disease. *Leishmania tropica* and *L. major* cause dermal cutaneous leishmaniasis; visceral leishmaniasis (kala-azar) is caused by *L. donovani* and mucocutaneous leishmaniasis is caused by *L. braziliensis* and *L. mexicana*. Visceral leishmaniasis in Europe is caused by *L. infantum* with dogs as the main reservoir. *Leishmania tropica* is found in the Middle East, North Africa, India and the Mediterranean. *Leishmania donovani* is found in the old and new worlds: South America, the Mediterranean, North and East Africa, India and China. *Leishmania braziliensis* is found in Central and South America. *Leishmania mexicana* is found in North and Central America, Texas and Mexico.

Dermal cutaneous leishmaniasis or Old World leishmaniasis is also known as "Tropical or Oriental Sore" or "Delhi Boil" and is generally localized to the skin surrounding the bite of the *Phlebotomus* sandfly. The ulcers (volcano sign) are "draining" but produce "dry" ulcers that crust over. They usually resolve within one year but superinfection (yaws or myiasis) may occur and immunity develops. Cutaneous leishmaniasis affects over 300,000 people. The mucosal form affects the mucosa of the nose, pharynx, palate, larynx and upper lip causing ulcers that often become secondarily infected. Scarring can lead to death from pneumonia.

Visceral leishmaniasis, or "Kala-azar" is transmitted by *Phlebotomus* sandflies and is spread via the lymphatics from an often minor cutaneous lesion. They multiply in macrophages to form Leishman-Donovan bodies. Symptoms are usually chronic and comprise malaise, lymphadenopathy, cough, diarrhea, wasting and anemia, bleeding, and low-grade fever (3/day); liver and spleen enlarge and visibly distend the abdomen. Untreated, death ensues within three years, usually from secondary infection.

Leishmaniasis currently affects some 12 million people in 88 countries, all but 16 of which are in the developing world. It is estimated that 350 million people are exposed to the risk of infection by the different species of *Leishmania* parasite. The annual incidence of new cases is about two million (1.5 million of cutaneous leishmaniasis, and 0.5 million of visceral leishmaniasis). Recently, the WHO has reported an increase in overlapping of visceral leishmaniasis (VL) and HIV infection due to the spread of the AIDS pandemic. *Leishmania* / HIV co-infection is considered to be a real "emerging disease", especially in southern Europe, where 25-70% of adult VL cases are related to HIV infection, and 1.5-9.5% of AIDS cases suffer from newly acquired or reactivated VL. Intravenous drug users have been identified as the main population at risk.

Treatment and Control

Dermal leishmaniasis usually resolves spontaneously. Visceral leishmaniasis is treated with extended courses of antimonial compounds (e.g. sodium stibogluconate or meglumine

antimonate) and dietary supplementation (pentamidine isethionate has been used in antimony-resistant cases). WHO regimes are changing and pentamidine may be used. Mucocutaneous leishmaniasis is also treated with antimonial compounds. However, only around 50% of patients respond to antimonial compounds and relapses are seen. Pentamidine isethionate, paromomycin (aminosidine), allopurinol, ketoconazole, itraconazole, interferon gamma and liposomal amphotericin B have all been used; amphotericin B appears the most effective. Control of sandflies is difficult although buildings may be sprayed with insecticide. Sandflies cannot bite through clothing. Repellents are effective although mosquito nets are of limited value (sandflies are 3 μ m). Sandflies are nocturnal and can be avoided. Rodent and dog control is a possibility. Vaccines (killed or live attenuated promastigotes) have been tried but effectiveness has not been assessed.

Black Flies

Class: Insecta
Order: Diptera
Family: Simuliidae
Genus: *Simulium*

Introduction

Black Flies are small (1.5-4µm in length) and normally black with short hairless legs and antennae. They have large compound eyes and a characteristically hairy humped thorax. Flies of the genus *Simulium* are generally found near free-flowing well-oxygenated water and bite during the day, tearing the skin to reach blood vessels.

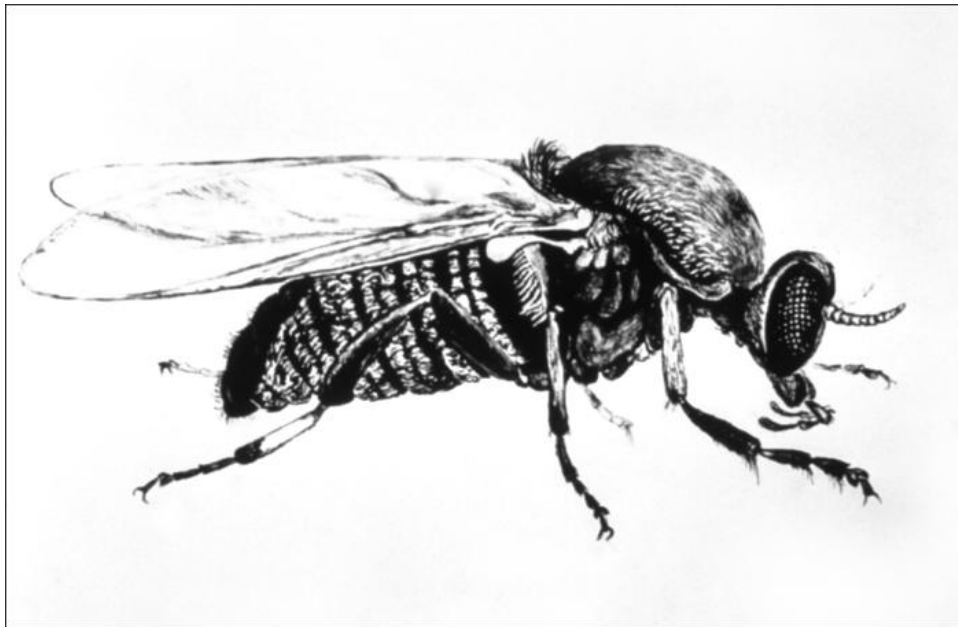

Illustration 12-11. Typical illustration of a Black Fly (*Simulium*). They are usually small (1.4–4µm in length), black with short hairless legs and antennae. (SOURCE: PHIL 4639 - CDC)



Image 12-20. Image of a Black fly receiving a blood meal. (SOURCE: Unknown)

Life Cycle

Simuliidae eggs are laid in flowing or turbid waters in clusters of 200-800 eggs depending on the species. Hatching is mediated by the external environment, generally occurring several days following oviposition. There are 6-9 larval instars, with the larvae remaining essentially sedentary for the period and feeding through filtration. Movement is possible if necessary with some larval species acting as predators. The mature larvae can be recognized by a characteristic black "gill spot" on the thorax. The pupa is enclosed in a dark colored cocoon, identifiable by a series of filamentous respiratory gills protruding from the anterior end. In most cases the adult fly emerges from the pupal stage following one week of incubation.

Disease

Simulium are vectors for the filarial parasitic nematode responsible for Onchocerciasis (*Onchocerca volvulus*). It is distributed throughout Africa, Arabia, Central America, northern South America and Mexico with 30 million people infected in Africa alone; it is one of the most important causes of blindness in the world. Adult worms (up to 50cm) live in the subcutaneous tissue of man (the only known host) and release microfilariae into the skin. These are taken up by *Simulium* (*S. damnosum* and *S. naevei* in Africa; *S. ochraceum* and *S. metallicum* in Central America). Microfilariae penetrate the gut wall, migrate to the thoracic muscles, molt to L₂ stages and molt again to filariform L₃ stages which are passed to the next host during a blood meal. Larvae mature to adults in one year and may live for up to 20 years. Microfilariae can live for up to two years but are often trapped, in fibrous nodules, by the host's cellular response and are responsible for the pathology. Microfilariae are highly motile, unsheathed and measure 300 by 7 microns; there are no nuclei in the end of the tail, which is long and pointed; the head is slightly enlarged. Microfilariae are not found in blood.

Skin problems include nodules (2cm to 5cm in diameter) containing adult worms. Onchodermatitis is caused by death of microfilariae in the skin and is associated with severe pruritis (adopts different forms in different geographical localities e.g. "erysipelas de la costa" in Central America, "leopard skin" in parts of Africa), skin depigmentation and premature ageing. There may be minor elephantiasis of the inguinal area ("hanging groin") or of the genitals (including hydrocoele). Eye involvement is due to microfilariae entering the eye and dying and

may eventually lead to blindness through sclerosing keratitis and retinal damage (microfilaria can be seen in the anterior chamber of the eye). There may be competition between parasite and host for vitamin A.

Treatments and Control

Ivermectin destroys microfilariae and renders adult female worms infertile; the manufacturer provides this drug without charge. Nodules may be surgically removed to reduce the worm-load and decrease the chances of ocular involvement. In areas of East Africa, *S. naevei* has been eradicated with insecticide (the larvae of this parasite attach to freshwater crabs). *S. damnosum* inhabit areas far distant to its breeding sites and control is much more difficult. However, the WHO larvicide program in concert with mass Ivermectin treatment has the potential to control the problem. Vegetation should be cleared around villages and irrigation should be devised to avoid fast-flowing water currents.

Tabanid Flies

Class: Insecta

Order: Diptera

Family: Tabanidae

Subfamily: Chrysopsinae (Deer flies)

Genus: *Chrysops*

Subfamily: Tabaninae (Horse flies)

Genus: *Tabanus*

Introduction

Chrysops are 9-10µm in length with broad wings and large iridescent eyes. The abdomen is yellow or orange and can be patterned with black markings. The antennae consist of three segments, lacking a projection from the second segment and with the third segment subdivided into four smaller sections. Female *Chrysops* are attracted by smoke and normally bite in the morning or late afternoon. They breed in shaded muddy areas and have a worldwide distribution.

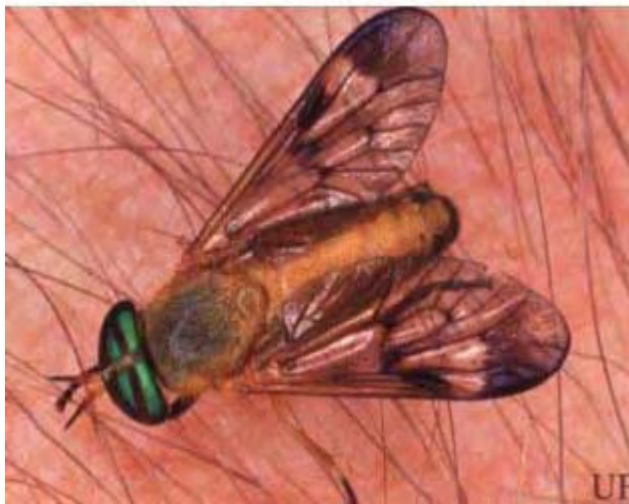

Image 12-21. Image of a Deer fly receiving a blood meal. They have large iridescent eyes and broad wings. Generally measure between 9–10µm in length. (SOURCE: University of Florida)

Life Cycle

Female Tabanids generally lay 100 -1000 large creamy white eggs on the undersides of plants and rocks surrounding aquatic areas. The eggs hatch following several weeks of incubation. Larvae live and feed in wet rotting vegetation but survive breathing oxygen. The larval stage can be quite prolonged (1-3 years) with 6-13 larval instars depending on the species. The mature larvae migrate to dry areas and undergo pupation. The pupa often gets buried in the soil and can often be large. The pupal stage lasts several weeks, and the adults emerge to feed.

Disease

Tabanids are vectors for the parasitic nematode *Loa loa*. Their Microfilariae are large and sheathed and contain nuclei extending to the end of the rounded tail. Adult worms are thin and white (females 2cm-7cm long, 425µm in diameter and males 2cm-3.4cm long, 350µm in diameter). Clinical features of *Loa loa* infections include considerable pruritis and transient painful subcutaneous swellings termed Calabar swellings. Migrating adult worms can cross the conjunctiva or the bridge of the nose and ectopic worms cause problems such as hydrocoele, orchitis, colonic lesions, encephalitis.

Treatment and Control

Worms traversing the conjunctiva may be removed surgically. Diethyl-carbamazine (DEC) is a proven treatment; prevention comprises the use of prophylactic DEC. However, DEC may have fatal side effects including encephalitis and the current drug of choice is Ivermectin. Drugs kill microfilariae but not adult worms. Antihistamines and corticosteroids may prevent allergic reactions brought about by rapid destruction of microfilariae in heavy infections. Insect control is not practical.

Biting Midges

Class: Insecta

Order: Diptera

Family: Ceratopogonidae

Genus: *Culicoides*

Introduction

Biting midges are 1µm-2µm long with a small head, long antennae and segmented palps. The thorax is often black spotted and contains a distinctive set of small depressions called the “humeral pits” just posterior of the head on the upper thorax. Biting midges have long legs and wings that fold over the thorax when at rest. Only the females take blood meals and normally swarm and bite in the early morning or late evening, especially during overcast weather.

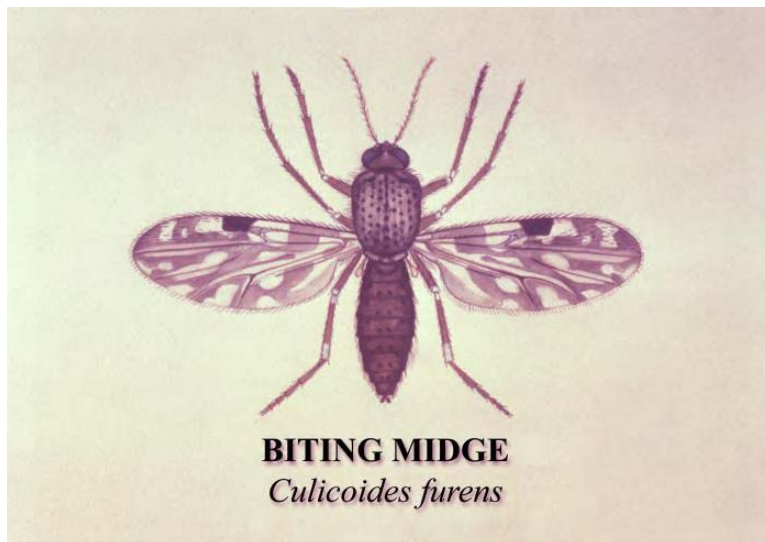

Illustration 12-12: Typical Illustration of a Biting Midge (*Culicoides*). The thorax is often black spotted and contains a distinctive set of small depressions called the “humeral pits” just posterior of the head (SOURCE: PHIL 3822 - CDC/Dr. Richard Darsie)

Life Cycle

Female *Culicoides* lay 30-250 dark, cylindrical eggs on the surface of wet soil or organic debris. Larvae emerge from the eggs soon thereafter depending on the environmental conditions. There are four larval instars, and the mature larvae resemble that of a nematode worm. They have a small dark head, 12 segments, and terminal papillae. The larvae feed on detritus and may develop for extended periods of time depending on the species and conditions. The pupal period lasts 3-10 days, with the adult females emerging to feed and breed.

Disease

Culicoides species possess the ability to transmit various filarial parasites to humans (*Mansonella perstans*, *M. streptocerca* and *M. ozzardi*). Adult *Mansonella streptocerca* reach 3 cm in length and live in the skin. Microfilariae are small and thin (200µm in length), unsheathed and nuclei extend to the end of a hooked tail. The major symptoms of infection are pruritis, papular eruptions and pigment changes.

Mansonella ozzardi is found in South and Central America and the adult worms live in the peritoneal cavity. Microfilariae are small, thin (150-200 by 4.5 microns) and unsheathed with indistinct nuclei that do not extend to the end of the pointed tail. They are found in the skin and blood and are non-periodic. Most infected persons are asymptomatic but may be associated with arthralgias, headaches, fever, pruritis, hepatomegaly, pulmonary symptoms and adenopathy: there is no proven therapy.

Mansonella perstans is found in tropical Africa and coastal South America with adult worms measuring 4cm-8cm. They inhabit the peritoneal and, rarely, pleural cavities. Infections are usually asymptomatic but can be associated with pruritis, fever, arthralgias and neurological changes.

Head and Body Lice

Class: Insecta

Order: Phthiraptera

Genus: *Pediculus*

Introduction

Pediculus humanus capitis (the head louse) and *Pediculus humanus humanus* (the body louse) are 2µm-4µm long and flattened dorsoventrally. They are wingless with distinct head, thorax (bearing three pairs of clawed legs) and abdomen (seven segments). The fore legs are well developed to grasp clothing and hair, with terminal claws to aid grip on the host. *Pediculus* feed using two stylets which suck blood whilst a third directs saliva into the skin; meanwhile feces are continually passed onto the skin.



Image 12-22. Dorsal Image of a typical body louse (*Pediculus humanus humanus*). They are wingless and dorsoventrally flattened, bearing a distinct head, thorax and abdomen. They measure approximately 2–4µm in length. (SOURCE: PHIL 9205 - CDC/ Frank Collins, Ph.D.)

Life Cycle

The head and body louse share very similar life cycles only differing in the placement of their eggs; the body louse cements eggs to clothing and the head louse cements single eggs at the base of hairs. Females can lay upwards of 300 eggs during a lifetime. Lice have a hemimetabolous lifecycle. The nymph hatches from the egg and appears very structurally similar to the adult louse. There are three nymphal instars that require blood meals to proceed. It only takes 7-12 days to proceed to the adult stage if blood meals are readily available, but conversely lice will perish if not fed for several days.



Image 12-23. Dorsal Image of a typical head louse (*Pediculus humanus capitis*) (SOURCE: PHIL 377 - CDC/ Dr. Dennis D. Juranek)

Disease

Colonization by lice may result in serious infection and disease. Lice can potentially pass *Rickettsia prowazeki* resulting in epidemic typhus and other pathogens such as *Rochalimaea quintana* and *Borrelia recurrentis* that result in potentially serious fever. The mode of transmission for all infectious agents is through physically crushing and spreading feces or waste into the wound created through feeding.

Control

The most effective control is to remain clean, but insecticides are often necessary during epidemics to avoid reinfestation.

Pubic Lice

Class: Insecta
Order: Phthiraptera
Genus: *Phthirus*

Introduction

The crab louse is 1µm-2µm long and distinguished by a square, undifferentiated body and massive claws on the two posterior sets of forelegs. These claws are able to grasp both pubic and facial hair (including eyelashes), and allow the louse to remain tightly bound to the host. They are spread mostly by sexual contact, but may also be transmitted through fomites.

Life Cycle

The life cycle of *Phthirus* is very similar to *Pediculus*. Females lay bundles of eggs on the coarse pubic hairs and dense facial hairs of humans. The crab lice proceed through a cycle similar to the head and body lice, with the nymphal stage proceeding several days longer. *Phthirus* are less active than *Pediculus*, but similarly can not survive for very long without a host and blood meals.

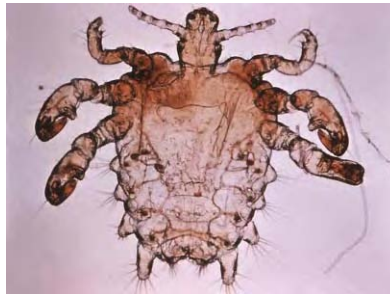

Image 12-24. Ventral Image of a typical Crab louse (*Phthirus*). They hold onto pubic hair with the large claws found on the posterior legs. (SOURCE: PHIL 4077 - CDC)

Disease

There appears to be very little evidence of disease transmission by *Phthirus*, but have the ability to cause severe localized allergic reactions during infestations.

Fleas

Class: Insecta

Order: Siphonaptera

Genus: *Pulex*, *Xenopsylla*, *Ctenocephalides*, *Tunga*

Introduction

Fleas are laterally compressed and wingless (1µm-4µm) with powerful legs. The entire body is generally covered with bristles, and the mouthparts point downwards. *Pulex irritans* (the human flea) and *Xenopsylla cheopsis* (the tropical rat flea) are combless. *Nosopsyllus fasciatus* (the rat flea) has a pronotal comb (behind its head). *Ctenocephalides felis* (the cat flea) and *C. canis* have two combs - a pronotal comb and a genal comb (under the head).



Image 12-25. Image of the cat flea *Ctenocephalides felis*. Fleas are laterally compressed and wingless (1-4 µm) with powerful legs. (SOURCE: CDC)

Tunga penetrans (the Chigoe or jigger flea) demonstrates compressed thoracic segments and attacks man in the Americas, Africa and India, commonly penetrating the stratum corneum between the toes or in the toenail margins

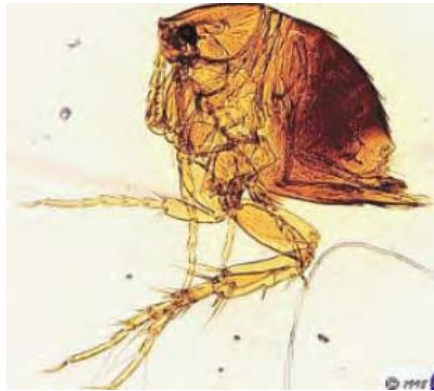

Image 12-26. Image of the Chigoe flea *Tunga penetrans*. They commonly penetrate between the toes or under the toenail. (SOURCE: Unknown)

Life Cycle

Flea larvae hatch from eggs generally following a week incubation. The larvae are legless, segmented, and covered with setae. The larvae feed on organic material, and proceed through two or three larval instars depending on the environment. The larva spins a cocoon and pupates and emerges when the conditions appear favorable for survival. The life cycle can be as short as several weeks or up to several years depending on the stimuli surrounding the pupa. Both sexes take blood meals and can live for long periods of time allowing females to lay an enormous number of eggs over their lifetime.

Disease

Fleas are a general nuisance, often biting humans on exposed surfaces resulting in discomfort. Flea-bites induce pruritic papular urticaria commonly on the unprotected lower leg of women and all over the body of children who have intimate animal contact; a generalized allergic response may occur.

Certain fleas, notably the rat fleas, spread plague (*Yersinia pestis*) and murine typhus (*Rickettsia typhi*), and serve as intermediate hosts for species of tapeworm (*Hymenolepis* sp.). Cat and dog fleas serve as intermediate hosts for another common tapeworm (*Dipylidium caninum*), which can be spread to humans, especially children with exposure to pet animals. *Pulex irritans* is not a major vector of disease but may play a minor role in the transmission of plague. Infection is often spread by the bite alone, but can also potentially be transmitted through fecal abrasion. *Tunga penetrans* does not transmit disease to humans, but females will burrow into host skin. The pinpoint lesion enlarges to pea-size within two weeks necessitating removal of the gravid female using a pin, a needle or a sliver of bamboo. This may potentially lead to a secondary bacterial infection.

Control and Treatment

Control of fleas is generally mediated through insecticidal powders and aerosols. If outbreaks of murine typhus or plague occur steps to control the rodent populations in the affected area may be employed.

Bedbugs

Class: Insecta

Order: Siphonaptera

Genus: *Cimex*

Introduction

Common bedbugs (*Cimex lectularius*) are 3µm-7µm long, wingless, and flattened dorsoventrally. They have long legs, clearly segmented antennae and abdomen, and a distinctive set of compound eyes. Bedbugs are characteristically pale brown but swell and turn to black-red when engorged with blood. Both sexes infest clothing, beds and laundry and pierce the skin with an elongated proboscis to feed.



Image 12-27. Image of the common Bedbug *Cimex lectularius*. Bed bugs are usually pale brown in color but swell and turn black-red after a blood meal. (SOURCE: PHIL 6283 - CDC/Donated by the World Health Organization, Geneva, Switzerland.)

Life Cycle

Cimex nymphs appear yellow and very similar structurally to the adults. The life cycle is hemimetabolous with five nymphal instars that require blood meals to proceed. The adults primarily feed nocturnally, and females may lay upwards of 500 eggs during their lifetime. Life

cycle duration and the number of offspring produced are primarily determined by the humidity and temperature of the surrounding environment.

Disease

Cimex blood meals result in inflammation, irritation and intense itching. These are the most common results of an infestation, but *Cimex* have also been found to carry Hepatitis B in India.

Treatment and Control

A female lays around 200 adherent eggs at the rate of 3 or 4 per day: eggs are white and 1mm in length. Control is by application of insecticide to mattresses and crevices where they hide during the daytime (to a height of several feet from the floor).

Triatomine bugs

Class: Insecta
Order: Hemiptera
Family: Reduviidae
Genus: *Triatoma*

General Characteristics

Triatomine bugs (a.k.a., Assassin bugs, Kissing bugs, Cone-nosed beetles, Walapai Tiger, or Reduviid bugs) are of variable size but are often large (10mm-30mm). They typically appear brown-black, but can have bright coloration. They are distinguished by a large snout with dark compound eyes, a thin and straight proboscis, and a triangular pronotum. They have long slender legs with terminal claws and segmented antennae. A set of large wings covers the oval abdomen. They live in the mud-walls of housing and woodpiles and come out to feed at night when the host is asleep: they are voracious biters, often on the face around the eyes.



Image 12-28. Image of the Triatomine Bugs *Triatoma infestans*. Reduviid bugs are of variable size but are often large (10-30 mm). They typically appear brown-black, but can have bright coloration. (SOURCE: PHIL 2538 - CDC/World Health Organization.)

Life Cycle

The life cycle of *Triatoma* is hemimetabolous. The emergence of nymphs from eggs is primarily determined by the environment, and blood meals are required to proceed through the

five nymphal instars. The nymphs and adults feed nocturnally and generally lay 50 to 1000 eggs depending on life term and the quantity of blood meals taken.

Disease

The primary disease transmitted by *Triatoma* is Chaga's Disease caused by *Trypanosoma cruzi*. Chagas disease is endemic in 21 countries; around 100 million people in Central and South America could be exposed to reduviid bugs; the prevalence of Chaga's disease is about 16-18 million. Rural migrations to urban areas during the 1970s and 1980s changed the traditional epidemiological pattern of Chaga's disease: it became an urban disease, as unscreened blood transfusion created a second way of transmission. Between 1960 and 1989, the prevalence of infected blood in blood banks in selected cities of South America ranged from 1.7% in Sao Paulo, Brazil to 53% in Santa Cruz, Bolivia, a percentage far higher than that of hepatitis or HIV infection (WHO data).

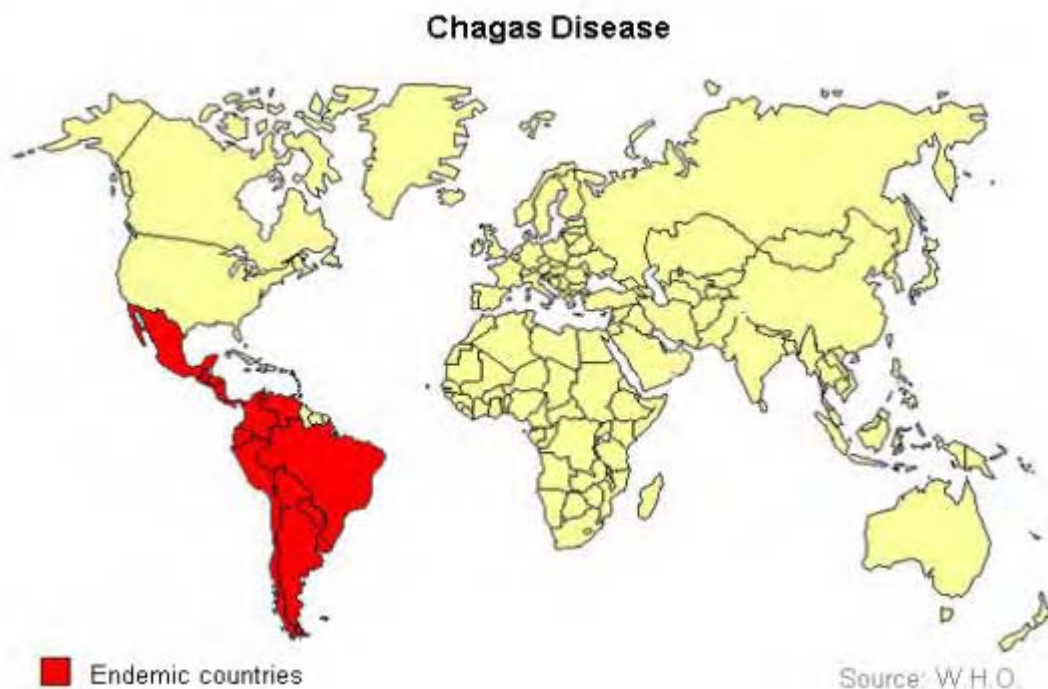

Illustration 12-13. Worldwide distribution of Chagas Disease (*Trypanosoma cruzi*) (SOURCE: WHO)

Triatomids are blood feeders and deposit infected feces (containing metacyclic trypanomastigotes) on the host's skin during feeding. The host rubs the feces into the wound; alternatively trypanosomes enter through the mucous membranes or conjunctivae. Once in the bloodstream, trypanomastigotes penetrate the spleen, liver, lymph nodes and muscle by an unknown mechanism (possibly via receptor-ligand binding proteins). The parasite transforms to the amastigote form that divides by binary fission and forms a pseudocyst. This ruptures and released amastigotes transform to flagellated trypanomastigotes via promastigotes and epimastigotes and enter the bloodstream. Unlike African bloodstream trypanomastigotes, these do not replicate. If a Reduviid bug eats trypanomastigotes, they transform to epimastigotes, replicate by binary fission, and are passed as trypanomastigotes

two weeks later. *Trypanosoma cruzi* does not exhibit antigenic variation but can persist for the life of the host. *T. cruzi* may also be transmitted in blood products or transplacentally. Humans and a large number of species of domestic and wild animals constitute the reservoir, and the vector bugs infest poor housing and thatched roofs.

In the acute phase (generally seen in children) a small red nodule (Chagoma) may form at the site of the bite. Romana's signs comprise fever, unilateral bipalpebral edema and ophthalmia. Most acute phases are asymptomatic and resolve to an asymptomatic chronic stage in 2-3 months. However, the patient may present with myalgia, bone pain, fever and chills, lymphadenopathy, hepatosplenomegaly and anorexia. Young children may develop meningoencephalitis. Pseudocysts form in heart muscle and fatal heart failure arises within one month. Neurological disorders, gastrointestinal disease and chronic myocarditis are features of chronic disease (mainly seen in adults) which arises 10-20 years after the initial infection and is untreatable. Congenital infection may lead to abortion, still birth or acute disease. Reactivation occurs in HIV-infected patients. Diagnosis is by detection of trypanosomes in peripheral anti-coagulated blood, CSF or node aspirate using wet film or Giemsa stain (acute disease) or by serology (Chaga's IgG ELISA in chronic disease). *Trypanosoma cruzi* is usually C-shaped, 12-30µm in length with a narrow membrane and a flagellum. The posterior kinetoplast is characteristically large and the nucleus is central.

Control

There is no satisfactory treatment. Extended therapy with the toxic agents, benznidazole or nifurtimox, only kills extra-cellular parasites and optimum efficacy (60%) is achieved during the acute phase. Chronic disease is treated symptomatically. Control is by improvements in housing, health education and insecticidal treatment of dwellings. Vaccines and chemoprophylaxis are ineffective (associated with autoimmune disease). For the control of blood-transmitted infections the aim is to screen all blood donors from endemic countries for *T. cruzi* antibodies, and to strengthen health service infrastructures for multiple blood screening (HIV, Hepatitis B and *T. cruzi*).

Chapter 13.

Artifacts and Confounders

Artifacts and Confounders

Introduction and Summary

Cysts and trophozoites must be examined carefully in different fields of view and measurement is often essential. Objects such as epithelial cells and macrophages are around the same size as amoebic trophozoites: the latter may also move and contain red blood cells. White blood cells, plant and vegetable cells, fat globules, muscle fibers, pollen grains, yeasts cells and air bubbles may be confused with cysts or eggs. Air bubbles trapped under adhesive tape often resemble *Enterobius* eggs. Plant hairs and fibers are easily confused with larvae; algae such as *Psorospermium haeckelii* may be found in the feces of patients who have eaten crayfish. Earthworms may resemble roundworms. A variety of non-pathogenic ova, cysts and parasites resemble pathogens in terms of size and morphology and careful examination is essential. Eggs of *Heterodera*, a parasitic nematode of root vegetables, may resemble hookworm eggs. Eggs originating from harmless mites in cereals or flour could be confused with hookworm ova but are usually larger. We recently encountered 160 micron "Schistosome ova" in the urine of a patient complaining of hematuria: we suspected *Schistosoma haematobium* but, on closer analysis, the eggs contained unidentified insects. This volume provides examples of artifacts that may be confused for parasitic life stages. Artifacts should be considered on the basis of size, shape, lack of organelles and defining feature, and variable reactivity with common stains.

Red and White Blood Cells

Red blood cells and a variety of white blood cells can be easily mistaken for parasitic cells or cysts when observed with microscopy.

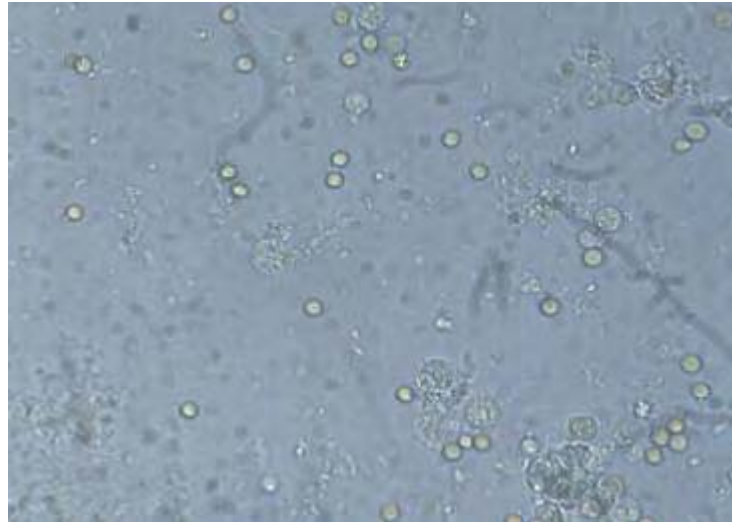


Image 13-1. Image illustrating red and white blood cells in a slide preparation. (SOURCE: Unknown)

White Blood Cells

Charcot-Leyden crystals are a product of eosinophil breakdown and are, therefore, occasionally found in feces of patients suffering from parasitic disease. They appear red when stained with in a trichrome fecal preparation.

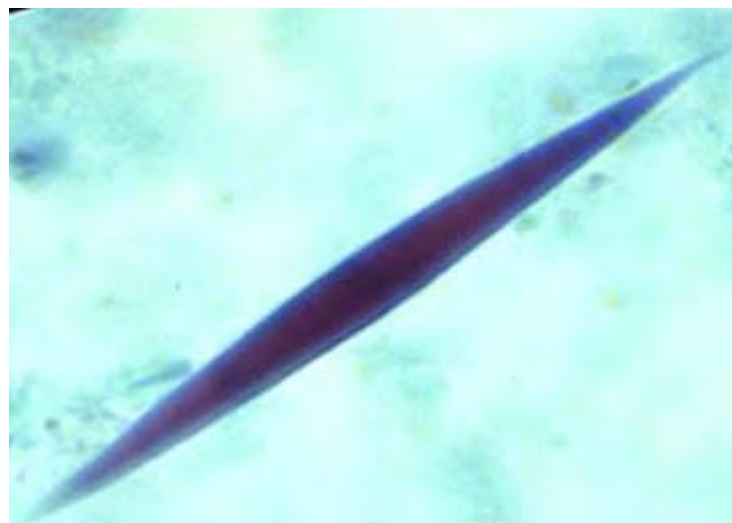

Image 13-2. Image illustrating trichrome stained Charcot-Leyden crystals in a slide preparation (Image courtesy of: The University of Alberta)

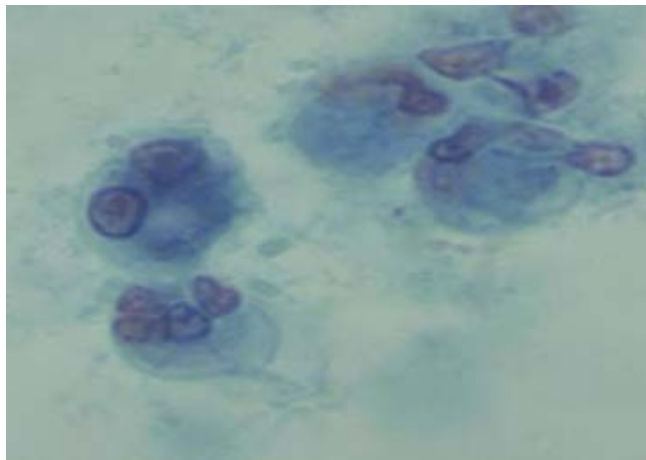


Image 13-3. Image showing trichrome stained Macrophage in a slide preparation. Note similarity to Amoeboid structure. (SOURCE: Unknown)

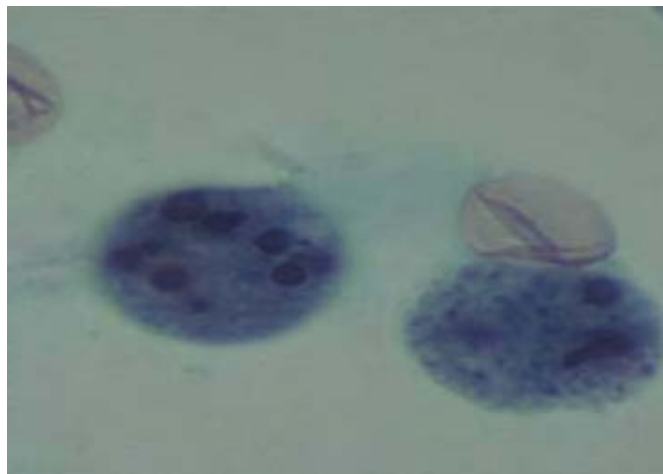


Image 13-4. Image illustrating trichrome stained Leukocyte in a slide preparation. Note similarity to Amoeboid cyst structure. (SOURCE: Unknown)

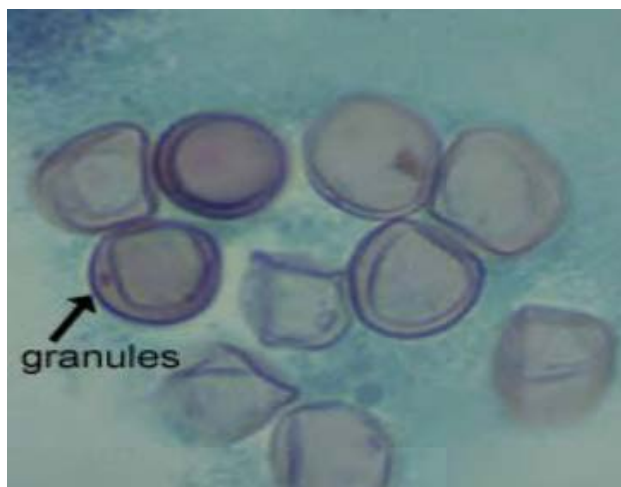

Image 13-5. Image illustrating Red Blood Cells in slide preparation. RBC's may appear to have a central body and a rim of cytoplasm or granules which could be mistaken for *Blastocystis hominis*. (SOURCE: Unknown)

Fat Globules

Fat globules present in a fecal slide preparation may appear similar to parasitic cysts or cell bodies.

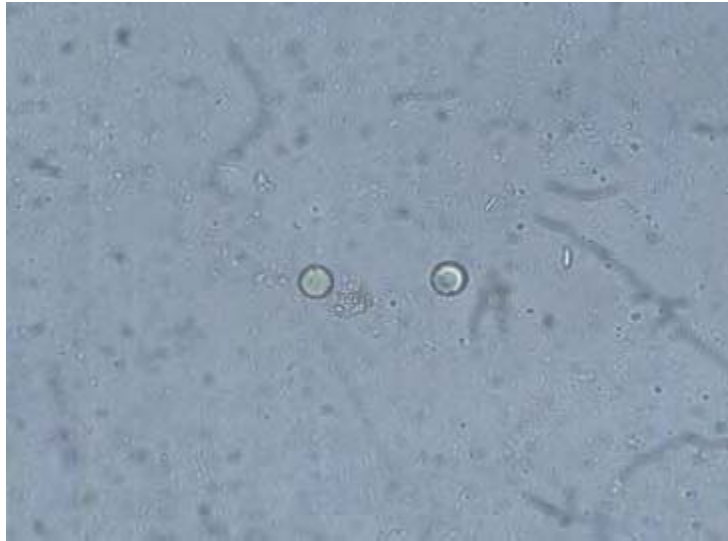


Image 13-6. Image illustrating Fat Globules in slide preparation. (SOURCE: Unknown)

Emulsifying agents are a useful tool to eliminate potential confusion involving fat globules. The removal of such particles from slide preparations will undoubtedly reduce cases of misdiagnosis.

Yeast Cells

Yeast may resemble protozoan cysts because they are uniform in color, have few inclusions and no nucleus. Yeast could also be confused with small protozoans like *E. nana* or with *Cryptosporidium* or *Cyclospora* oocysts in wet preparation. In acid-fast stains, the oocysts of *Cryptosporidium* and *Cyclospora* species stain pink to red. Yeasts are not acid fast and stain green.

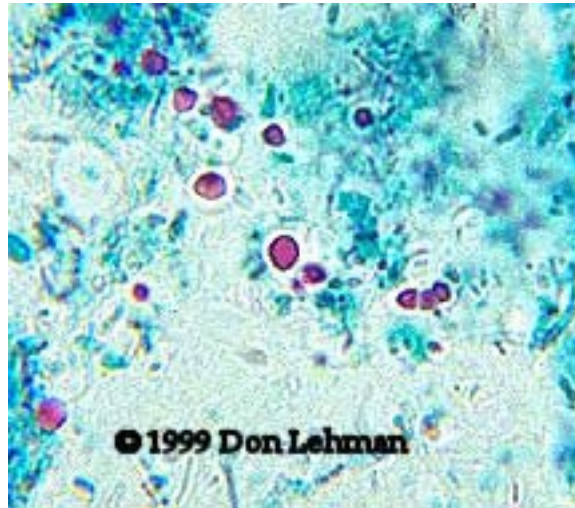


Image 13-7. Image illustrating Yeast Cells in slide preparation (Image courtesy of: Don Lehman). Note similarity to parasitic oocysts. (SOURCE: [Don Lehman, Univ of Delaware](#))

Vegetable Cells

Plant cells and associated elements seen in feces may resemble eggs, cysts or cell bodies. Plant cells are often identified by a more irregular outer membrane.



Image 13-8. Image illustrating Vegetable cell in slide preparation. Note similarity to *Paragonimus* eggs.
(SOURCE: Unknown)

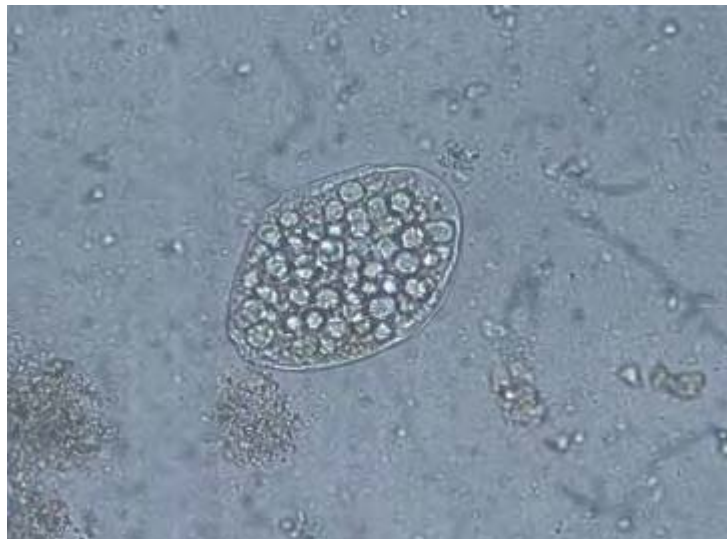

Image 13-9. Image illustrating Vegetable cell in slide preparation. Note similarity to *Dipylidium caninum* egg packets.
(SOURCE: Unknown)



Image 13-10. Image illustrating Vegetable cell in slide preparation. (SOURCE: Unknown)

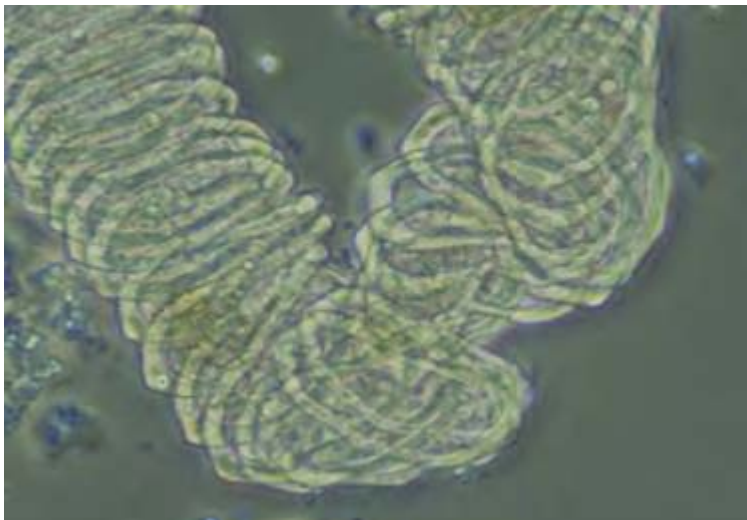


Image 13-11. Image illustrating a Vegetable Spiral in slide preparation. Such spirals may appear similar to proglottids. (SOURCE: Unknown)



Image 13-12. Image illustrating Vegetable Spiral in slide preparation. (SOURCE: Unknown)

Pollen

Pollen grains are often misinterpreted as parasite eggs, but can often be discerned through size and the presence or absence of important structural elements.




Image 13-13. Image illustrating pollen in slide preparation using a color filter. (SOURCE: Unknown)

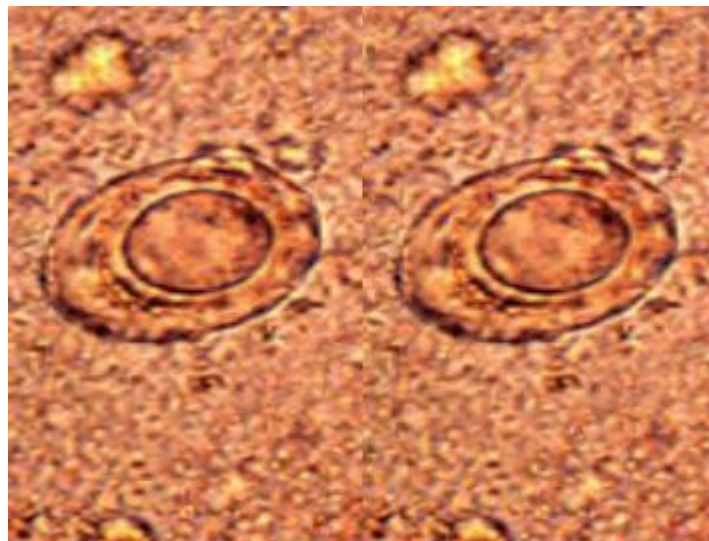


Image 13-14. Image illustrating pollen in slide preparation that could be mistaken for a *Taenia* egg. The shell is thinner, of non-uniform thickness, and no hooks are visible. (SOURCE: CDC)

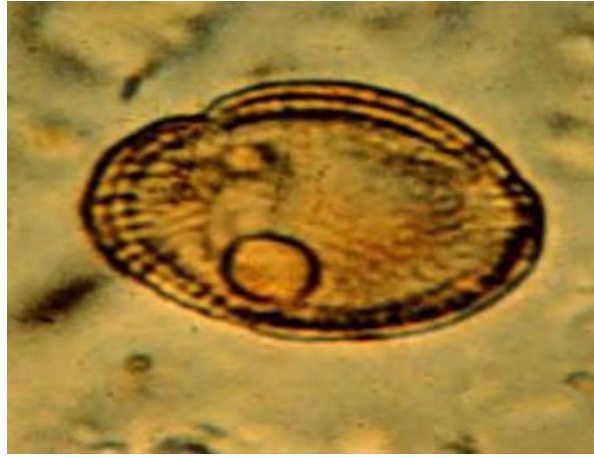

Image 13-15. Image illustrating pollen resembling a *Hymenolepis nana* egg. Hooks and polar filaments are not visible. (SOURCE: CDC)

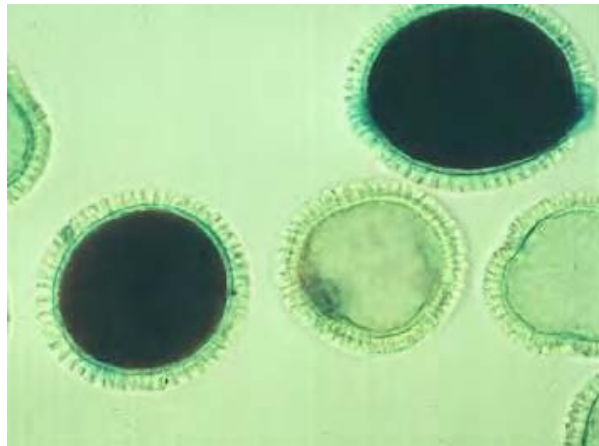


Image 13-16. Image illustrating geranium pollen cells in slide preparation. (SOURCE: Unknown)

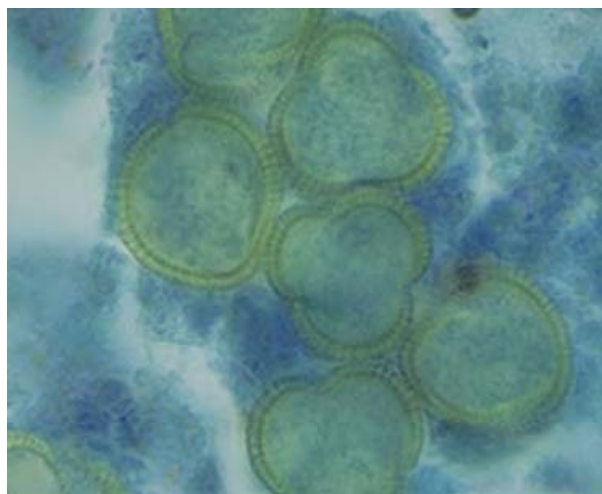


Image 13-17. Image illustrating pollen cells in slide preparation. Similar to *Taenia* eggs, but distinguished by uneven thickness of the wall and lack of internal contents do not suggest an egg. (SOURCE: Unknown)

Hair

Animal and plant hairs are most often and easily mistaken for parasitic nematode worms. Their size and shape may be comparable in many cases, but a lack of internal definition will identify the artifact when compared to the worm. Although nematodes are non-segmented and externally simple organisms, they will often show unique structural characteristics under close examination.

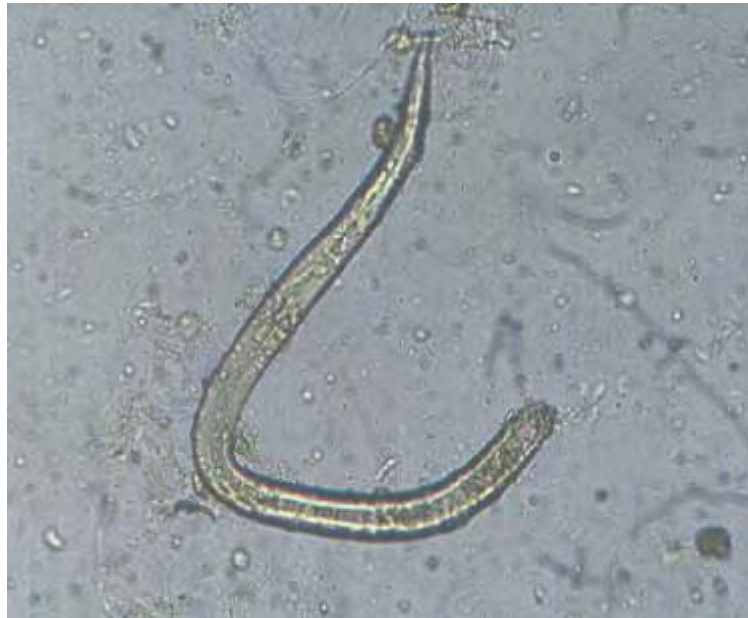

Image 13-18. Image illustrating peach hair in slide preparation. Note the similarity to *Strongyloides stercoralis*. (SOURCE: Unknown)



Image 13-19. Image illustrating vegetable hairs in slide preparation. (SOURCE: Unknown)

Insect Eggs

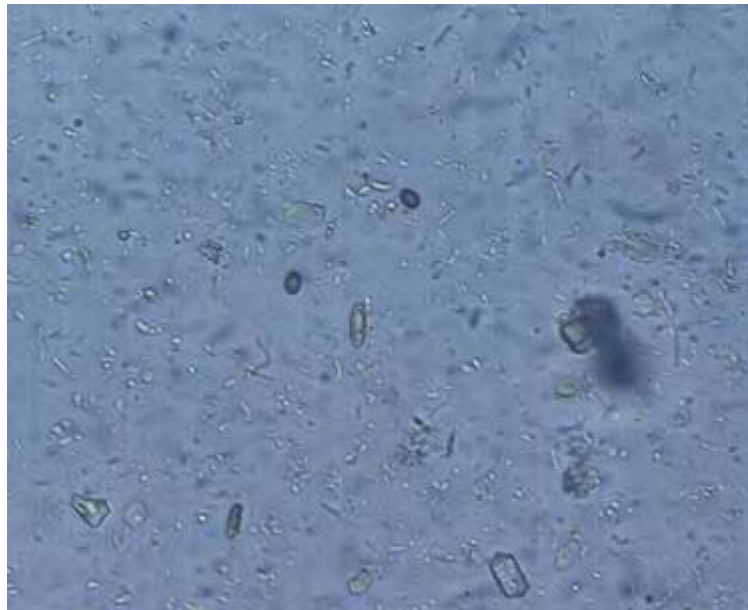

Image 13-20. Image illustrating Insect eggs in slide preparation. (SOURCE: Unknown)

Plant Parasites

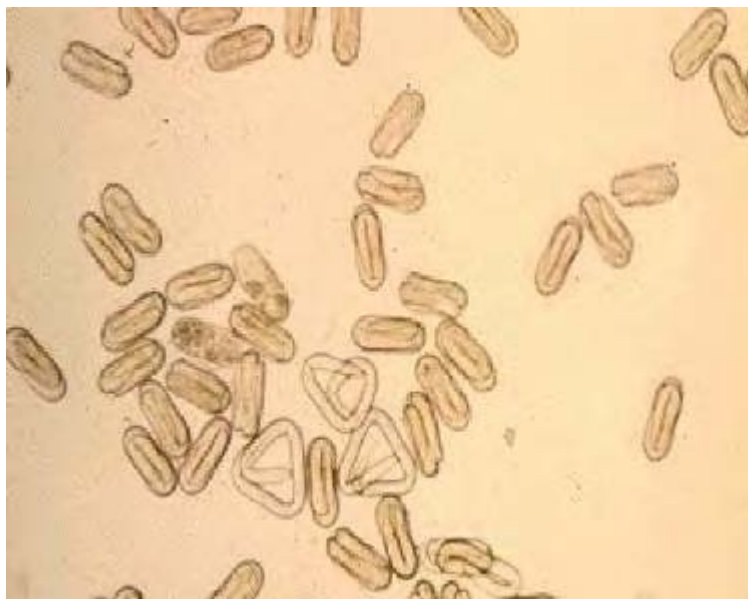


Image 13-21. Image illustrating *Heterodera spp.* in slide preparation. Such parasitic nematodes attack root vegetables such as beetroot, turnips and radishes. Their eggs are 80-120 μ m by 25-40 μ m and can conceivably be confused with hookworm eggs. (SOURCE: Unknown)

Earthworms



Image 13-22. Image illustrating an Annelid earthworm in detritus. They belong to the Annelida (*Lumbricus* and *Allolobophora*) and are elongated, segmented and circular in section and are occasionally confused with *Ascaris*. They have a purple-brown dorsal surface and a paler ventral surface, swell out at around segment 12 and possess a marked thickening (the clitellum) a third of the way from the anterior. (SOURCE: Unknown)